



Reversible myelosuppression suspected to be secondary to linezolid in a cat with infected subcutaneous ureteral bypass systems

Authors: Hedgespeth, Barry A, Tefft, Karen M, and Kendall, Allison R

Source: Journal of Feline Medicine and Surgery Open Reports, 6(2)

Published By: SAGE Publishing

URL: <https://doi.org/10.1177/2055116920967226>

BioOne Complete (complete.BioOne.org) is a full-text database of 200 subscribed and open-access titles in the biological, ecological, and environmental sciences published by nonprofit societies, associations, museums, institutions, and presses.

Your use of this PDF, the BioOne Complete website, and all posted and associated content indicates your acceptance of BioOne's Terms of Use, available at www.bioone.org/terms-of-use.

Usage of BioOne Complete content is strictly limited to personal, educational, and non - commercial use. Commercial inquiries or rights and permissions requests should be directed to the individual publisher as copyright holder.

BioOne sees sustainable scholarly publishing as an inherently collaborative enterprise connecting authors, nonprofit publishers, academic institutions, research libraries, and research funders in the common goal of maximizing access to critical research.



Reversible myelosuppression suspected to be secondary to linezolid in a cat with infected subcutaneous ureteral bypass systems

Journal of Feline Medicine and Surgery Open Reports
1–6

© The Author(s) 2020

Article reuse guidelines:

sagepub.com/journals-permissions

DOI: 10.1177/2055116920967226

journals.sagepub.com/home/jfmsopenreports

This paper was handled and processed by the American Editorial Office (AAFP) for publication in *JFMS Open Reports*



Barry A Hedgespeth^{id}, Karen M Tefft^{id}
and Allison R Kendall^{id}

Abstract

Case summary A 5-year-old castrated male domestic shorthair cat was presented for a multidrug-resistant *Enterococcus faecium* urinary tract infection within its bilateral subcutaneous ureteral bypass systems. After considerable consultation, the cat was treated with oral linezolid (10 mg/kg q12h) for two separate 2-week courses over 5 weeks. Over this time period, the cat became progressively neutropenic and thrombocytopenic, but was otherwise clinically stable. Upon cessation of the linezolid, the bicytopenia resolved within 12 days.

Relevance and novel information The reversible myelosuppression in this case is suspected to be secondary to linezolid administration. While previously reported in people, this effect has not been reported at therapeutic doses in veterinary species. This report demonstrates the potential for adverse drug reaction development in cats treated with prolonged linezolid therapy and highlights the need for extreme caution when utilizing linezolid in patients with renal insufficiency. Linezolid is the only drug currently approved by the Food and Drug Administration to treat vancomycin-resistant enterococci infections in people; however, resistance to this antibiotic appears to be increasing. Multidrug-resistant organisms continue to be a real global public health threat in both human and veterinary medicine. Third-tier antibiotics should only be considered under extreme circumstances and after considerable consultation with a specialist. Please note that the authors of this manuscript followed American Veterinary Medical Association policies on stewardship and International Society for Companion Animal Infectious Diseases guidelines, and do not promote or encourage the use in daily practice.

Keywords: Adverse drug reaction; antibiotic; linezolid; monitoring; myelosuppression; neutropenia; side effect; subcutaneous ureteral bypass; thrombocytopenia; urinary tract infection

Accepted: 12 September 2020

Introduction

Ureteral obstruction is a common, and often fatal, condition in cats. Medical management is generally associated with a poor long-term outcome, and traditional surgical approaches such as ureterotomy are associated with significant morbidity and mortality.¹ Currently, interventional methods such as placement of a ureteral stent or subcutaneous ureteral bypass (SUB) device are recommended following the failure of medical management or in severe, emergent cases.² While these techniques have lower perioperative mortality rates, they still carry the

risk of long-term complications such as urinary tract and/or implant infection.³ Two studies have shown positive bacterial urine cultures in 24–25% of cats following

Department of Clinical Sciences, North Carolina State University, Raleigh, NC, USA

Corresponding author:

Allison R Kendall DVM, MS, DACVIM (SAIM), Department of Clinical Sciences, North Carolina State University, 1060 William Moore Drive, Raleigh, NC 27607, USA
Email: arkendal@ncsu.edu



Creative Commons Non Commercial CC BY-NC: This article is distributed under the terms of the Creative Commons

Attribution-NonCommercial 4.0 License (<https://creativecommons.org/licenses/by-nc/4.0/>) which permits non-commercial use, reproduction and distribution of the work without further permission provided the original work is attributed as specified on the SAGE and Open Access pages (<https://us.sagepub.com/en-us/nam/open-access-at-sage>).

SUB placement.^{3,4} *Enterococcus* species are the most commonly implicated cause of chronic bacteriuria in cats with SUB systems, though treatment may not always be warranted.^{3,4} Enterococcal infection can be challenging given its propensity for the development of resistance and biofilm formation, and implant removal may be the only viable option to prevent progression to urosepsis in some cases.⁵⁻⁷

Case description

A 5-year-old castrated male domestic shorthair cat was presented to our veterinary teaching hospital for suspected pyelonephritis. Twenty months previously, the cat was evaluated at another hospital for acute kidney injury due to bilateral ureteral obstruction and suspected pyelonephritis. No abnormalities were present on complete blood count (CBC) at that time. Serum chemistry revealed marked azotemia (blood urea nitrogen [BUN] 211 mg/dl [reference interval (RI) 15–34 mg/dl]; creatinine 13.2 mg/dl [RI 0.7–1.8 mg/dl]). When medical management failed, bilateral SUB devices were placed. Bloodwork performed 1 month after surgery revealed dramatic improvement in azotemia (BUN 28 mg/dl; creatinine 2.7 mg/dl). Despite recommendations for periodic flushing of the SUB devices, this only occurred twice in the 20 months since placement at approximately 8 and 13 months, respectively. Urine obtained during both flushes was negative for microbial growth.

Upon presentation to our hospital, the cat's physical examination revealed a temperature of 100.4°F (38.0°C), a heart rate of 230 beats per min (bpm) and a respiratory rate of 40 breaths per min. CBC abnormalities included a mild normocytic, normochromic, non-regenerative anemia (hematocrit 30.7% [RI 33.0–51.0%]) and leukocytosis (white blood cell [WBC] count $14.35 \times 10^3/\mu\text{l}$ [RI $3.77\text{--}16.73 \times 10^3/\mu\text{l}$]) characterized by left-shifted neutrophilia (segmented neutrophils $15.985 \times 10^3/\mu\text{l}$ [RI $2.773\text{--}6.975 \times 10^3/\mu\text{l}$]; band neutrophils $0.623 \times 10^3/\mu\text{l}$ [RI 0.000/ μl]) and monocytosis ($1.246 \times 10^3/\mu\text{l}$ [RI 0.068–0.780 $\times 10^3/\mu\text{l}$]). Serum chemistry abnormalities included moderate azotemia (BUN 65 mg/dl; creatinine 4.3 mg/dl) and hypermagnesemia (3.2 mg/dl [RI 2.0–2.6 mg/dl]). Abdominal ultrasonography revealed left hydronephrosis and hydroureter, regional tissue reaction, small intestinal rupture with an intraluminal foreign body at the site of entry of the left SUB tubing into the urinary bladder and no evidence of right-sided SUB obstruction. Flushing the systems with agitated sterile saline during ultrasonographic assessment determined the left cystostomy tube to be obstructed. An exploratory laparotomy was performed, wherein the small intestines were found adhered and perforated around the left cystostomy tube. The left cystostomy tube was replaced, and resection and anastomosis of the intestinal segment was performed with

no intra- or postoperative complications. A chemistry panel submitted prior to hospital discharge revealed BUN 49 mg/dl and creatinine 2.8 mg/dl. The cat was discharged with amoxicillin/clavulanic acid (Clavamox drops [Zoetis] 13.2 mg/kg PO q12h for 2 weeks).

Two weeks after surgery, the cat was presented for progressive lethargy, inappetence and worsening azotemia discovered by the primary care veterinarian (BUN 57 mg/dl; creatinine 4.7 mg/dl). CBC revealed a normocytic, normochromic, non-regenerative anemia (21.2%) and leukocytosis ($14.35 \times 10^3/\mu\text{l}$) characterized by segmented neutrophilia ($9.615 \times 10^3/\mu\text{l}$). Ultrasonographic evaluation of the cat's urinary tract revealed mild left-sided SUB occlusion in addition to left-sided pyelectasia. A urine sample was collected from both SUB ports; urinalysis revealed pyuria, hematuria and bacteriuria in both, while bacterial culture of each sample cultured $>100,000$ CFU/ml multidrug-resistant (MDR) *Enterococcus faecium* with identical resistance profiles. Based on extended susceptibility testing, the bacteria were susceptible only to vancomycin and linezolid. Given the cat's progressive azotemia, clinical signs, dangerous sequelae associated with infected implants, and following consultations with both the veterinary college's pharmacologist and microbiologist, antibiotic therapy with linezolid (compounded 50 mg capsule; North Carolina State University [NCSU]) 10 mg/kg PO q12h was initiated (Figure 1; day 0). Although the bacteria were susceptible to vancomycin, this antibiotic was not chosen owing to the necessity of intravenous (IV) administration and possible nephrotoxicity. The cat was administered darbepoetin (Aranesp [Amgen] 0.5 $\mu\text{g/kg}$ SC) once weekly and iron dextran (100 mg/ml solution [Vedco] 10 mg/kg SC) once to address the anemia.

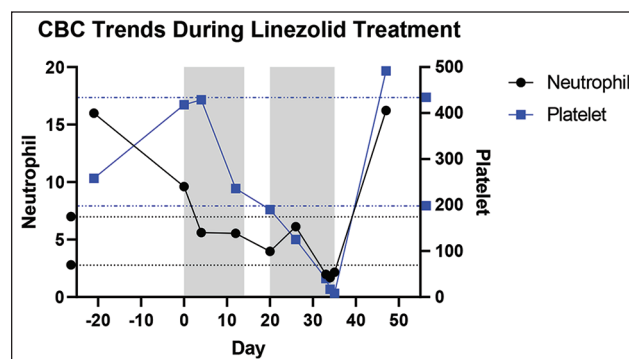


Figure 1 Neutrophil and platelet count trends of a cat experiencing suspected reversible bicytopenia during linezolid treatment. Gray columns indicate the time during which linezolid was administered. Dotted horizontal lines indicate the bounds of the normal reference interval for each respective cell index. Neutrophil and platelet counts expressed as cells $\times 10^3/\mu\text{l}$. CBC = complete blood count

The T-FloLoc (Tetra-EDTA) Protocol for Infection was also commenced starting on day 4 of linezolid administration.⁸ A full description of the protocol can be found elsewhere.⁸ Owing to the cost of repeated urine cultures, a urinalysis was obtained on day 4 and a urine culture was obtained on day 7. Cultures from each SUB port on day 7 both yielded 5000–10,000 colony-forming units (CFU)/ml *E faecium* that was now susceptible to tetracyclines. Urine collected from the SUB ports on day 14 cultured the same new strain of *E faecium*, now at a concentration of >100,000 CFU/ml. Owing to the cat's clinical improvement, and in order to avoid any unknown sequelae and ethical dilemma associated with chronic linezolid therapy, this antibiotic was discontinued on day 14 and minocycline was initiated that day (compounded 25 mg capsule [NCSU] 5.7 mg/kg PO q12h for 2 weeks). Urine collected from the SUB ports on day 20 cultured >100,000 CFU/ml *E faecium* with a similar resistance profile to the previous culture. A urinalysis also revealed the presence of severe pyuria and the cat was hyporexic and lethargic at home. Prior to considering removal or replacement of the SUB systems, linezolid (10 mg/kg PO q12h) was reinitiated in conjunction with the minocycline. On day 26, a SUB flush was performed again in accordance with the T-FloLoc Protocol for Infection. At that time, the cat was clinically doing well. A CBC revealed mild thrombocytopenia ($125 \times 10^3/\mu\text{l}$ [RI 198–434 $\times 10^3/\mu\text{l}$]) and a urine culture was again positive for *Enterococcus* species with the same resistance profile as previously identified. The cat's azotemia was stable at this time (BUN 52 mg/dl; creatinine 5.4 mg/dl).

The cat was presented on day 33 for re-evaluation. The only medications that the cat was receiving at this time were linezolid and minocycline. Physical examination revealed a temperature of 101.2°F (38.4°C), a heart rate of 200 bpm and a respiratory rate of 30 breaths per min. CBC abnormalities revealed a moderate normocytic, normochromic, non-regenerative anemia (24.8%), mild leukopenia ($3.040 \times 10^3/\mu\text{l}$) characterized by segmented neutropenia ($1.976 \times 10^3/\mu\text{l}$), no band neutrophils and thrombocytopenia ($40 \times 10^3/\mu\text{l}$), which was confirmed on blood smear. Out of concern for sepsis, a coagulation panel was performed, which showed that no coagulopathy was present. A chemistry panel revealed progressive azotemia (BUN 124 mg/dl; creatinine 10.0 mg/dl). The cat was hospitalized for supportive care (IV fluid therapy and a packed red blood cell transfusion) and monitoring of CBC parameters, which continued to worsen over the following 2 days, despite vital signs remaining within normal limits. The cat's segmented neutrophils reached a nadir of $1.693 \times 10^3/\mu\text{l}$, while the cat's platelets achieved a nadir of $8 \times 10^3/\mu\text{l}$. Because the cat only fulfilled one of four suggested criteria for the diagnosis of systemic inflammatory response syndrome (SIRS) and was otherwise clinically well, the bicytopenia was thought to be due to myelosuppression

secondary to linezolid, rather than sepsis.⁹ Blood cultures and bone marrow aspiration were recommended but declined by the owner. Both antibiotics were discontinued on day 35 and the cat was discharged on this day with instructions to return for bloodwork and urine culture in 1 week. No other medications were being administered at that time.

At this visit (day 47), the cat was doing very well clinically with a marked improvement of most of the CBC parameters (hematocrit 23.3%; WBC count $21.64 \times 10^3/\mu\text{l}$; segmented neutrophil count $16.230 \times 10^3/\mu\text{l}$; platelet count $492 \times 10^3/\mu\text{l}$). A fluoroscopic assessment of the SUB systems was performed, revealing patency of both native ureters. Given this, in addition to the persistent *E faecium* infection, as indicated on a pooled culture of urine obtained from the SUB systems, the SUB systems were removed surgically, and the cat was treated with vancomycin after further consultation with the veterinary college's microbiologist and pharmacologist and its seemingly good prognosis given bilateral ureteral patency. The cat recovered uneventfully from surgery and had no recurrence of neutropenia or thrombocytopenia until the time of euthanasia 3 months later due to recurrent ureteral obstruction.

Discussion

Linezolid was the first oxazolidinone compound to be developed into and utilized as an antimicrobial agent. Initially envisioned as monoamine oxidase inhibitors to treat depression in people, the oxazolidinones were found to display activity against Gram-positive bacteria.¹⁰ Given their wholly synthetic nature and corresponding lack of inherent resistance genes in bacteria, further development of these drugs into antimicrobials was pursued.¹¹ Linezolid is thought to act by targeting 23S ribosomal RNA of the 50S subunit, thereby interfering in the formation of the 70S initiation complex.^{12,13} It is reserved for life-threatening infections caused by Gram-positive bacteria, including *Staphylococcus*, *Streptococcus* and *Enterococcus* species.¹¹

Linezolid has been classified as a 'third-tier' antibiotic by the Antimicrobial Guidelines Working Group of the International Society for Companion Animal Infectious Diseases.^{14,15} It should therefore only be utilized in documented, treatable infections that are resistant to all other reasonable options, and after consultation with an expert in infectious diseases and/or antimicrobial therapy.¹⁵ Although its use has not been restricted in the USA, linezolid has been classified as a 'Category A' antibiotic by the European Medicines Agency, indicating that it should be avoided and may only be administered to individual companion animals under exceptional circumstances.¹⁶ Despite these recommendations, linezolid has been utilized or recommended for use in a variety of companion animal infections, including those caused by MDR *Staphylococcus pseudintermedius*, *Nocardia* species,

Corynebacterium species and *Mycobacterium avium*.^{17–21} Linezolid resistance has been documented in a variety of bacterial organisms collected from veterinary species, including *Clostridium perfringens*, *Enterococcus faecalis* and *E faecium*.^{22–25} This increasing resistance profile highlights the need to judiciously utilize second- and third-tier antibiotics. As these antibiotics are reserved for severe infections in humans, they should only be used under the most exceptional circumstances when treating infections in veterinary species and only after consultation with specialists in infectious disease, microbiology and/or pharmacology. Given the catastrophic consequences of resistance development to these antibiotics, the authors recommend their use be limited to specialist practice, should they even need to be used at all. Furthermore, their use should only be considered when all other options have been exhausted and in patients with a good prognosis.

Linezolid's adverse effect profile is well described in the human medical literature. The most common adverse effects include thrombocytopenia (incidence 5.2–38.7%), anemia (incidence 10.0–16.0%), gastrointestinal upset (incidence 13.7–27.0%), lactic acidosis (incidence 6.8%), optic neuropathy (incidence 2.0–25.0%), peripheral neuropathy (incidence 2.0–50.0%) and serotonin syndrome (incidence 2.2–3.0%).^{26–34} Significant risk factors for the development of thrombocytopenia in people include renal insufficiency, chronic liver disease, neoplasia, previous vancomycin use and daily dose exceeding 22 mg/kg.^{28,30,35–41} The median reported time to development of thrombocytopenia is 11 days.³⁷ While relatively rare, neutropenia alone has been described as occurring in 6.4% of pediatric patients receiving linezolid and in scattered case reports of adults receiving linezolid, in conjunction with anemia and neutropenia.^{42,43}

The only reported adverse effects documented in companion animals were found during prolonged, high-dose preclinical trials in which time- and dose-dependent, reversible myelosuppression occurred in rats and dogs.⁴⁴ Given the limited use in companion animal species, the incidence of adverse effects in cats is unknown. This case report is therefore the first to document reversible myelosuppression believed to be secondary to linezolid use in a cat. The etiology of linezolid-induced myelosuppression has not been fully elucidated; however, it has been suggested that cellular oxidative stress may play a large role in the development of thrombocytopenia and anemia.⁴⁵

Although no bone marrow analysis was performed to determine the etiology of this cat's bicytopenia, there is a paucity of plausible alternative explanations for why else this occurred. One possibility is that the cat was septic. Although definitive inclusion criteria for cats with SIRS have yet to be established, previous studies have suggested that cats with SIRS have ≥ 2 or ≥ 3 of the following: a rectal temperature $\geq 103.5^\circ\text{F}$ (39.7°C) or $< 100^\circ\text{F}$

(37.8°C); heart rate ≥ 225 bpm or ≤ 140 bpm; respiratory rate ≥ 40 breaths per min; WBC count $\geq 19,500$ WBCs/ μl or ≤ 5000 WBCs/ μl ; or a band neutrophil fraction $\geq 5\%$.⁹ The cat in this report fulfilled only one of these criteria, and its stable clinical condition would thus not support that SIRS and sepsis were contributing to the bicytopenia. The cat's CBC parameters improved dramatically following discontinuation of all antibiotics; were the cat septic, that would have been an unlikely outcome. Another possible explanation for the cat's bicytopenia is the concurrent administration of minocycline. Although no reports describe bicytopenia secondary to minocycline, there are isolated reports of humans developing thrombocytopenia and neutropenia following minocycline administration.^{46,47}

Upon retrospective evaluation, the cat's platelet count decreased nearly 50% after the first 2-week course of linezolid therapy, despite the platelet count remaining within the RI. This could have been an early indicator of an adverse drug reaction. This highlights the importance of monitoring CBC parameters while a patient is receiving linezolid, as a precipitous drop in platelet count may be an early sign that bone marrow toxicity is occurring and therapy should be halted. Consideration should also have been given to the cat's impaired renal function, as renal insufficiency is a known risk factor in people for the development of an adverse drug reaction to linezolid.^{28,30,35–37} If antibiotic selection is limited and linezolid must be administered to patients with renal insufficiency, dose adjustment has been suggested to mitigate the development of thrombocytopenia and should be strongly considered in addition to careful hematological monitoring.⁴⁸

Conclusions

This is the first documented case of myelosuppression suspected to be secondary to linezolid administration in a cat. It highlights the importance of rational, judicious use of third-tier antibiotics such as linezolid, as well as consideration for comorbidities such as renal insufficiency, which may increase the risk of adverse effect development.

Antimicrobial stewardship statement Linezolid is the only drug currently approved by the Food and Drug Administration to treat vancomycin-resistant enterococci infections in people; however, resistance to this antibiotic appears to be increasing. Multidrug-resistant organisms continue to be a real global public health threat in both human and veterinary medicine. Third-tier antibiotics should only be considered under extreme circumstances and after considerable consultation with a specialist. Please note that the authors of this manuscript followed American Veterinary Medical Association policies on stewardship and International Society for Companion Animal Infectious Diseases

guidelines, and do not promote or encourage the use in daily practice.

Acknowledgements The authors wish to thank Dr Megan Jacob, Dr Zachary Kern, Dr Kathryn LaQuaglia, Dr Crystal Lindaberry, Dr Mark Papich, Dr Ashley Spencer, Jewels Darrow, Melissa Jaroneski and Patricia Secoura for their assistance with case management.

Conflict of interest The authors declared no potential conflicts of interest with respect to the research, authorship, and/or publication of this article.


Funding The authors thank ScoutBio for research funding that directly contributed to financial support for publication.

Ethical approval This work involved the use of non-experimental animals only (including owned or unowned animals and data from prospective or retrospective studies). Established internationally recognized high standards ('best practice') of individual veterinary clinical patient care were followed. Ethical approval from a committee was therefore not necessarily required.

Informed consent Informed consent (either verbal or written) was obtained from the owner or legal custodian of all animal(s) described in this work (either experimental or non-experimental animals) for the procedure(s) undertaken (either prospective or retrospective studies). No animals or humans are identifiable within this publication, and therefore additional informed consent for publication was not required.

ORCID iD Barry A Hedgespeth  <https://orcid.org/0000-0002-0399-7163>

Karen M Tefft  <https://orcid.org/0000-0003-4523-9763>

Allison R Kendall  <https://orcid.org/0000-0002-7859-4895>

References

- Kyles A, Hardie E, Wooden B, et al. **Management and outcome of cats with ureteral calculi: 153 cases (1984–2002).** *J Am Vet Med Assoc* 2005; 226: 937–944.
- Lulich J, Berent A, Adams L, et al. **ACVIM small animal consensus recommendations on the treatment and prevention of uroliths in dogs and cats.** *J Vet Intern Med* 2016; 30: 1564–1574.
- Kopečný L, Palm C, Drobátz K, et al. **Risk factors for positive urine cultures in cats with subcutaneous ureteral bypass and ureteral stents.** *J Vet Intern Med* 2019; 33: 178–183.
- Berent A, Weisse C, Bagley D, et al. **Use of a subcutaneous ureteral bypass device for treatment of benign ureteral obstruction in cats: 174 ureters in 134 cats (2009–2015).** *J Am Vet Med Assoc* 2018; 253: 1309–1327.
- Arias C and Murray B. **The rise of the *Enterococcus*: beyond vancomycin resistance.** *Nat Rev Microbiol* 2012; 10: 266–278.
- Mohamed J and Huang D. **Biofilm formation by enterococci.** *J Med Microbiol* 2007; 56: 1581–1588.
- Sandoe J, Witherden IR, Cove JH, et al. **Correlation between enterococcal biofilm formation in vitro and medical-device-related infection potential in vivo.** *J Med Microbiol* 2003; 52: 547–550.
- Berent A and Weisse C. **T-FloLoc™ (Tetra-EDTA) protocol for infection.** https://norfolkvetproducts.com/PDF/T-FloLoc/EDTA_protocol_INFECTION_2018-01.pdf (2017, accessed October 12, 2020).
- Babyak J and Sharp C. **Epidemiology of systemic inflammatory response syndrome and sepsis in cats hospitalized in a veterinary teaching hospital.** *J Am Vet Med Assoc* 2016; 249: 65–71.
- Brickner S. **Oxazolidinone antibacterial agents.** *Curr Pharm Des* 1996; 2: 175–194.
- Moellering RC. **Linezolid: the first oxazolidinone antimicrobial.** *Ann Intern Med* 2003; 138: 135–142.
- Ippolito J, Kanyo Z, Wang D, et al. **Crystal structure of the oxazolidinone antibiotic bound to the 50S ribosomal subunit.** *J Med Chem* 2008; 51: 3353–3356.
- Kloss P, Xiong L, Shinabarger D, et al. **Resistance mutations in 23S rRNA identify the site of action of the protein synthesis inhibitor linezolid in the ribosomal peptidyl transferase center.** *J Mol Biol* 1999; 294: 93–101.
- Hillier A, Lloyd DH, Weese JS, et al. **Guidelines for the diagnosis and antimicrobial therapy of canine superficial bacterial folliculitis (Antimicrobial Guidelines Working Group of the International Society for Companion Animal Infectious Diseases).** *Vet Dermatol* 2014; 25: 163–e43. DOI: 10.1111/vde.12118.
- Weese JS, Blondeau JM, Boothe D, et al. **Antimicrobial use guidelines for treatment of urinary tract disease in dogs and cats: Antimicrobial Guidelines Working Group of the International Society for Companion Animal Infectious Diseases.** *Vet Med Int* 2011; 2011: 263768. DOI: 10.4061/2011/263768.
- European Medicines Agency. **Answer to the request from the European Commission for updating the scientific advice on the impact on public health and animal health of the use of antibiotics in animals – Categorisation of antimicrobials.** https://www.ema.europa.eu/en/documents/other/answer-request-european-commission-updating-scientific-advice-impact-public-health-animal-health-use_en.pdf (2019, accessed October 12, 2020).
- Hopke KP and Sargent SJ. **Novel presentation of eosinophilic granuloma complex in a cat.** *JFMS Open Rep* 2019; 5. DOI: 10.1177/2055116919891548.
- Papich MG. **Selection of antibiotics for meticillin-resistant *Staphylococcus pseudintermedius*: time to revisit some old drugs?** *Vet Dermatol* 2012; 23: 352–360.
- Malik R, Krockenberger M, O'Brien C, et al. **Norcardia infections in cats: a retrospective multi-institutional study of 17 cases.** *Aus Vet J* 2006; 84: 235–245.
- Hall AJ, Cassidy PK, Bernard KA, et al. **Novel *Corynebacterium diphtheriae* in domestic cats.** *Emerg Infect Dis* 2010; 16: 688–691.
- Riviere D, Pingret JL, Etievant M, et al. **Disseminated *Mycobacterium avium* subspecies infection in a cat.** *J Feline Med Surg* 2011; 13: 125–128.
- Alvarez-Perez S, Blanco JL, Harmanus C, et al. **Prevalence and characteristics of *Clostridium perfringens* and**

- Clostridium difficile* in dogs and cats attended in diverse veterinary clinics from the Madrid region. *Anaerobe* 2017; 48: 47–55.
- 23 Ben Said L, Dziri R, Sassi N, et al. **Species distribution, antibiotic resistance and virulence traits in canine and feline enterococci in Tunisia.** *Acta Vet Hung* 2017; 65: 173–184.
 - 24 Tamang MD, Moon DC, Kim SR, et al. **Detection of novel oxazolidinone and phenicol resistance gene *optrA* in enterococcal isolates from food animals and animal carcasses.** *Vet Microbiol* 2017; 201: 252–256.
 - 25 Damborg P, Top J, Hendrickx AP, et al. **Dogs are a reservoir of ampicillin-resistant *Enterococcus faecium* lineages associated with human infections.** *Appl Environ Microbiol* 2009; 75: 2360–2365.
 - 26 Hirano R, Sakamoto Y, Tachibana N, et al. **Retrospective analysis of the risk factors for linezolid-induced thrombocytopenia in adult Japanese patients.** *Int J Clin Pharm* 2014; 36: 795–799.
 - 27 Minson Q and Gentry C. **Analysis of linezolid associated hematologic toxicities in a large veterans affairs medical center.** *Pharmacotherapy* 2010; 30: 895–903.
 - 28 Takahashi Y, Takesue Y, Nakajima K, et al. **Risk factors associated with the development of thrombocytopenia in patients who received linezolid therapy.** *J Infect Chemother* 2011; 17: 382–387.
 - 29 Bishop E, Melvani S, Howden BP, et al. **Good clinical outcomes but high rates of adverse reactions during linezolid therapy for serious infections: a proposed protocol for monitoring therapy in complex patients.** *Antimicrob Agents Chemother* 2006; 50: 1599–1602.
 - 30 Niwa T, Suzuki A, Sakakibara S, et al. **Retrospective cohort chart review study of factors associated with the development of thrombocytopenia in adult Japanese patients who received intravenous linezolid therapy.** *Clin Ther* 2009; 31: 2126–2133.
 - 31 Rao N and Hamilton CW. **Efficacy and safety of linezolid for Gram-positive orthopedic infections: a prospective case series.** *Diagn Microbiol Infect Dis* 2007; 59: 173–179.
 - 32 Im J, Baek J, Kwon H, et al. **Incidence and risk factors of linezolid-induced lactic acidosis.** *Int J Infect Dis* 2015; 31: 47–52.
 - 33 Park I, Hong S, Oh Y, et al. **Efficacy and tolerability of daily-half dose linezolid in patients with intractable multidrug-resistant tuberculosis.** *J Antimicrob Chemother* 2006; 58: 701–704.
 - 34 Taylor J, Wilson J and Estes L. **Linezolid and serotonergic drug interactions: a retrospective survey.** *Clin Infect Dis* 2006; 43: 180–187.
 - 35 Lee EY and Caffrey AR. **Thrombocytopenia with tedizolid and linezolid.** *Antimicrob Agents Chemother* 2018; 62: e01453–17. DOI: 10.1128/AAC.01453-17.
 - 36 Lin YH, Wu VC, Tsai IJ, et al. **High frequency of linezolid-associated thrombocytopenia among patients with renal insufficiency.** *Int J Antimicrob Agents* 2006; 28: 345–351.
 - 37 Nukui Y, Hatakeyama S, Okamoto K, et al. **High plasma linezolid concentration and impaired renal function affect development of linezolid-induced thrombocytopenia.** *J Antimicrob Chemother* 2013; 68: 2128–2133.
 - 38 Ikuta S, Tanimura K, Yasui C, et al. **Chronic liver disease increases the risk of linezolid-related thrombocytopenia in methicillin-resistant *Staphylococcus aureus*-infected patients after digestive surgery.** *J Infect Chemother* 2011; 17: 388–391.
 - 39 Sasaki T, Takane H, Ogawa K, et al. **Population pharmacokinetic and pharmacodynamic analysis of linezolid and a hematologic side effect, thrombocytopenia, in Japanese patients.** *Antimicrob Agents Chemother* 2011; 55: 1867–1873.
 - 40 Smith P, Birmingham M, Noskin G, et al. **Safety, efficacy and pharmacokinetics of linezolid for treatment of resistant Gram-positive infections in cancer patients with neutropenia.** *Ann Oncol* 2003; 14: 795–801.
 - 41 Rao N, Ziran B, Wagener M, et al. **Similar hematologic effects of long-term linezolid and vancomycin therapy in a prospective observational study of patients with orthopedic infections.** *Clin Infect Dis* 2004; 38: 1058–1064.
 - 42 Kaplan SL, Patterson L, Edwards KM, et al. **Linezolid for the treatment of community-acquired pneumonia in hospitalized children. Linezolid pediatric pneumonia study group.** *Pediatr Infect Dis J* 2001; 20: 488–494.
 - 43 Rao N, Ziran BH, Wagener MW, et al. **Similar hematologic effects of long-term linezolid and vancomycin therapy in a prospective observational study of patients with orthopedic infections.** *Clin Infect Dis* 2004; 38: 1058–1064.
 - 44 Pharmacia & Upjohn. **Zyvox** [package insert]. Kalamazoo, MI: Pharmacia & Upjohn, 2000.
 - 45 Bernstein WB, Trotta RF, Rector JT, et al. **Mechanisms for linezolid-induced anemia and thrombocytopenia.** *Ann Pharmacother* 2003; 37: 517–520.
 - 46 D'Addario SF, Bryan ME, Stringer WA, et al. **Minocycline-induced immune thrombocytopenia presenting as Schamberg's disease.** *J Drugs Dermatol* 2003; 2: 320–323.
 - 47 Nolan K, Ishteiwy R, Alexis J, et al. **Minocycline-induced agranulocytosis presenting as ecthyma gangrenosum.** *Skin* 2017; 1: 161–164.
 - 48 Crass R, Cojutti P, Pai M, et al. **Reappraisal of linezolid dosing in renal impairment to improve safety.** *Antimicrob Agents Chemother* 2019; 63: e00605-19. DOI: 10.1128/AAC.00605-19.