



## **Management of severe baclofen toxicosis using hemodialysis in conjunction with mechanical ventilation in a cat with chronic kidney disease**

Authors: Hoffman, Levi, Londoño, Leonel A, and Martinez, Jenifer

Source: Journal of Feline Medicine and Surgery Open Reports, 7(2)

Published By: SAGE Publishing

URL: <https://doi.org/10.1177/20551169211033770>

---

BioOne Complete ([complete.BioOne.org](https://complete.BioOne.org)) is a full-text database of 200 subscribed and open-access titles in the biological, ecological, and environmental sciences published by nonprofit societies, associations, museums, institutions, and presses.

Your use of this PDF, the BioOne Complete website, and all posted and associated content indicates your acceptance of BioOne's Terms of Use, available at [www.bioone.org/terms-of-use](https://www.bioone.org/terms-of-use).

Usage of BioOne Complete content is strictly limited to personal, educational, and non - commercial use. Commercial inquiries or rights and permissions requests should be directed to the individual publisher as copyright holder.

---

BioOne sees sustainable scholarly publishing as an inherently collaborative enterprise connecting authors, nonprofit publishers, academic institutions, research libraries, and research funders in the common goal of maximizing access to critical research.



# Management of severe baclofen toxicosis using hemodialysis in conjunction with mechanical ventilation in a cat with chronic kidney disease

*Journal of Feline Medicine and Surgery Open Reports*  
1–7

© The Author(s) 2021

Article reuse guidelines:

sagepub.com/journals-permissions

DOI: 10.1177/20551169211033770

journals.sagepub.com/home/jfmsopenreports

This paper was handled and processed by the American Editorial Office (AAFP) for publication in *JFMS Open Reports*



Levi Hoffman<sup>1</sup>, Leonel A Londoño<sup>2</sup>   
and Jenifer Martinez<sup>1</sup>

## Abstract

**Case summary** A 2-year-old castrated male domestic shorthair cat was presented for evaluation of acute and progressive neurologic signs 2–4 h after exposure to baclofen. The suspected ingested dose was 2.1 mg/kg. On admission, the cat was tetraplegic with stuporous mentation, and venous blood gas analysis showed mild hypercapnia (PvCO<sub>2</sub> 43.4 mmHg) raising concern for hypoventilation. Owing to the acute nature of the ingestion, severity of the clinical signs and reported history of chronic kidney disease, hemodialysis was recommended to remove the toxin. A 5 h hemodialysis session was performed using an intermittent platform without hemoperfusion. At the beginning of hemodialysis, worsening hypoventilation and hypercapnia (PvCO<sub>2</sub> 88.6 mmHg) required endotracheal intubation and manual ventilation initially, followed by mechanical ventilation. At the end of the dialysis session, the cat was breathing spontaneously and disconnected from the ventilator. The cat was ambulatory and alert 1 h after the end of dialysis. After an additional 12 h of monitoring, the cat had full return of neurologic function and was discharged from hospital. Serum baclofen concentration measured prior to, during and after hemodialysis showed a 77.7% reduction in baclofen levels immediately after hemodialysis.

**Relevance and novel information** This is the first report of baclofen toxicity in a cat successfully treated with hemodialysis and mechanical ventilation simultaneously. Treatment with hemodialysis therapy and mechanical ventilation could be considered in cases of acute baclofen toxicosis to improve outcome and reduce the length of the hospital stay.

**Keywords:** Baclofen; toxicity; hemodialysis; mechanical ventilation

**Accepted:** 1 July 2021

## Introduction

Baclofen (gamma [ $\gamma$ ]-amino-beta-[p-chlorophenyl]-butyric acid) is a centrally acting  $\gamma$ -aminobutyric acid agonist, skeletal muscle relaxant that is approved by the US Food and Drug Administration for use in humans for the treatment of muscle spasticity related to spinal cord lesions and multiple sclerosis. It is also used off-label in the treatment of cerebral palsy in children, alcohol addiction, gastroesophageal reflux disease and hiccups in people.<sup>1</sup>

<sup>1</sup>Department of Small Animal Clinical Sciences, University of Florida, Gainesville, FL, USA

<sup>2</sup>Department of Critical Care, Capital Veterinary Specialists, Jacksonville, FL, USA

### Corresponding author:

Leonel A Londoño DVM, DACVECC, Department of Critical Care, Capital Veterinary Specialists, 3001 Hartley Rd, Jacksonville, FL 32257, USA

Email: leolondonodvm@gmail.com



Creative Commons Non Commercial CC BY-NC: This article is distributed under the terms of the Creative Commons

Attribution-NonCommercial 4.0 License (<https://creativecommons.org/licenses/by-nc/4.0/>) which permits non-commercial use, reproduction and distribution of the work without further permission provided the original work is attributed as specified on the SAGE and Open Access pages (<https://us.sagepub.com/en-us/nam/open-access-at-sage>).

In veterinary medicine, baclofen had previously been used to decrease urethral resistance in dogs with spinal injuries.<sup>2</sup> However, owing to its narrow margin of safety, it is no longer recommended in dogs.<sup>3</sup> The clinical use of baclofen in cats has not been evaluated and is not recommended.<sup>3</sup> Clinical signs of toxicity in dogs and cats vary and appear to be dose dependent. The most common clinical signs include central nervous system (CNS) depression, vomiting and ataxia. Less common clinical signs include respiratory depression, cardiac arrhythmias and seizures.<sup>4</sup> Currently, no lethal doses have been established in dogs or cats; however, deaths in dogs have occurred at doses between 8 and 16 mg/kg, and clinical signs have been observed with doses as low as 0.7 mg/kg.<sup>4</sup> In cats, no specific correlation between ingested dose and clinical signs has been identified; however, clinical signs have been reported with doses as low as 1.7 mg/kg.<sup>4</sup> In cats, lower doses of baclofen (3–10 µg/kg) have been reported to decrease electromyogram amplitude of spinal motor drive and decrease ventilatory function.<sup>5</sup>

Baclofen has a small molecular weight (214 Da), low-to-moderate volume of distribution (0.8–2.5 l/kg), and relatively low protein binding (30%) in circulation, making it suitable for clearance by hemodialysis.<sup>6,7</sup> Two case reports of dogs with severe baclofen toxicity have shown successful treatment using hemodialysis:<sup>8,9</sup> one of the dogs was treated with hemodialysis in conjunction with hemoperfusion, and one required support with mechanical ventilation. To our knowledge this is the first report of a cat with severe signs of baclofen toxicity treated with hemodialysis and mechanical ventilation.

## Case description

A 2-year-old castrated male domestic shorthair cat weighing 4.7 kg was presented to a university teaching hospital for progressive signs of weakness and neurologic dysfunction. The cat had a presumptive history of chronic kidney disease (CKD) of unknown cause that was previously diagnosed by the referring veterinarian based on bloodwork; however, no International Renal Interest Society staging or diagnostic imaging had been performed and it was not currently receiving any treatment for it. About 2 h prior to presentation, the cat became acutely and progressively ataxic at home, with one episode of vomiting, which was not characterized by the owner. Initial bloodwork at the primary care veterinarian revealed leukocytosis of 22.7 K/µl (reference interval [RI] 2.87–17.02) characterized by neutrophilia of 13.8 K/µl (RI 1.83–10.29) and lymphocytosis of 7.65 K/µl (RI 0.92–6.88), as well as mild azotemia with a blood urea nitrogen of 45 mg/dl (RI 16–36) and creatinine 2.2 mg/dl (RI 0.8–2.4). No manual differential was performed, and the remainder of the complete blood count (CBC) and biochemistry profile was otherwise unremarkable. Owing to progressive tetraparesis and concerns for respiratory depression, the cat was referred for further evaluation.

On presentation, the cat was bradycardic (heart rate [HR] 120 beats/min [bpm]) and tachypneic (48 breaths/min). Neurologic examination revealed stuporous mentation and tetraplegia with absent withdrawals and peripheral reflexes in all four limbs. The cat had a weak gag reflex and menace was absent bilaterally, but the remainder of the cranial nerve responses were intact. Short, shallow breaths were noted and venous blood gas analysis revealed mild hypercapnia (mixed venous oxygen tension [PvCO<sub>2</sub>] 43.4 mmHg) and mild azotemia (Table 1). A urinalysis collected prior to initiation of any intravenous (IV) fluid therapy via cystocentesis was performed, and showed a urine specific gravity of 1.018, moderate bacteriuria (monomorphic rods) with the rare presence of white blood cells and minimal red blood cells (RBCs; 0–3/high-power field). After further discussion with the owners, suspected accidental ingestion of a 10 mg baclofen tablet (2.1 mg/kg ingested dose) was reported 2–4 h prior to presentation. Owing to the rapidly progressive nature of the clinical signs and the decreased kidney function, hemodialysis was recommended for extracorporeal decontamination.

Initial management included IV fluid therapy with lactated Ringer's solution (LRS; Vetivex Lactated Ringer's Injection USP [Dechra Veterinary Products]) at 10 ml/h. An 8 Fr × 11 cm hemodialysis catheter (HemoCath silicone double lumen catheter; MedCOMP) was aseptically placed in the right jugular vein using a modified Seldinger technique. Approximately 1.5 h after presentation, hemodialysis was initiated in an intermittent hemodialysis platform (Phoenix; Gambro) with a neonatal extracorporeal circuit (LWL Cartridge blood set; Gambro) and dialyzer (F3 Optiflux; Fresenius Medical Care). Blood flow (Q<sub>b</sub>) was set at 90 ml/min to maximize the clearance of baclofen from systemic circulation, and the ultrafiltration flow rate (Q<sub>f</sub>) was set by the minimum requirement of the dialysis platform at 100 ml/h. The dialysis prescription consisted of 5 h hemodialysis to account for the high volume of distribution of baclofen, constant sodium profiling (150 mmol/l) to maintain isotonicity with the patient and to prevent in vivo fluid shifting, and supplementation with sodium phosphate (Fleet Saline Enema; CB Fleet Company) added to the acid solution to reach a concentration of 2 mg/dl and prevent hypophosphatemia and subsequent hemolysis. LRS (Vetivex Lactated Ringer's Injection USP; Dechra Veterinary Products) was increased to 150 ml/h to replace the ultrafiltration volume and provide additional volume support owing to the concern for potential hypotension. The patient was anticoagulated with unfractionated heparin (Heparin Sodium Injection 1000 USP units/ml; Parma) at a dose range of 10–24 units/kg/h delivered by the hemodialysis platform's integrated syringe driver, with a target activated clotting time (ACT; ACT II [Medtronic]) of 180–220 s (RI 80–120) scheduled to be measured every 20–30 mins.

**Table 1** Serial venous blood gas measurements before, during and after hemodialysis treatment

Test	12:14 pm	2:13 pm	3:15 pm	4:21 pm	7:19 pm	9:59 pm	9:00 am	12/20	RI
	Presentation	Start of HD	1 h after start of HD*	2 h after start of HD	End of HD	2 h after end of HD*	14 h after end of HD	1 week recheck	
pH	7.405	7.181		7.165	7.450		7.466	7.372	7.335–7.446
PvCO <sub>2</sub> (mmHg)	43.4	88.6	122.4	85.9	40.3	29.6	32.7	28.6	35–40
PvO <sub>2</sub> (mmHg)	40	45.1		49.4	47.8		34.5	32.0	32–62
SO <sub>2</sub> %	71.9	61.4		67	83.4		66.9	55.7	68–92
Hct (%)	43	28		26	25		27	23	40–52
Hb (g/dl)	14.1	9		8.5	8.4		8.7	7.5	14–26
Na (mmol/l)	150.7	151.8		149.3	143.3		151.9	150.4	146–151
K <sup>+</sup> (mmol/l)	3.86	3.22		3.47	3.88		4.23	4.63	3.98–4.41
Cl <sup>-</sup> (mmol/l)	111.5	114.8		113.5	112.1		119.8	120.3	108.5–116
Ca <sup>+</sup> (mmol/l)	1.29	1.45		1.23	1.29		1.28	1.29	1.18–1.35
Mg <sup>+</sup> (mmol/l)	0.61	0.51		0.38	0.44		0.49	0.79	0.51–0.65
Glucose (mg/dl)	384	255		237	177		87	111	87–111
Lactate (mmol/l)	1.6	0.9		2.9	0.9		0.7	1.2	0.4–1.5
BUN (mg/dl)	46	13		7	6		29	47	10–30
Creatinine (mg/dl)	1.4	0.5		0.5	0.7		1.4	2.7	0.8–1.5
HCO <sub>3</sub> <sup>-</sup> (mmol/l)	27.4	33.5		31.2	28.3		23.8	16.8	18–27
TCO <sub>2</sub> (mmol/l)	28.8	36.2		33.9	29.5		24.8	17.6	19–28

\*Only mixed venous carbon dioxide tension (PvCO<sub>2</sub>) was measured at the described time points; a full blood gas analysis was not performed  
 RI = reference interval; PvO<sub>2</sub> = mixed venous oxygen tension; SO<sub>2</sub> = oxygen saturation; Hct = hematocrit; Hb = hemoglobin; HD = hemodialysis; BUN = blood urea nitrogen; HCO<sub>3</sub><sup>-</sup> = bicarbonate;  
 TCO<sub>2</sub> = total carbon dioxide

Concerns for progressive hypoventilation prompted repeat blood gas analysis after the initiation of hemodialysis, which revealed progressive hypercapnia (PvCO<sub>2</sub> of 88.6 mmHg) and respiratory acidosis (pH 7.181). The patient was given 4 mg/kg IV of propofol (Propofol 200 mg/20 ml; Zoetis) for endotracheal intubation and maintained on a propofol continuous rate infusion (CRI; dose range 50–60 µg/kg/min) and manual ventilation. A repeat PvCO<sub>2</sub> measurement 1 h later revealed worsening hypercapnia, despite manual ventilation, so mechanical ventilation was initiated. Positive pressure ventilation was performed with synchronous intermittent mandatory ventilation volume-controlled mode (980 Ventilator System; Puritan-Bennett), initial fraction of inspired oxygen (FiO<sub>2</sub>) of 100% and positive end-expiratory pressure of 1 cmH<sub>2</sub>O. Additional ventilator settings include a respiratory rate of 18 breaths/min, a target tidal volume of 10.5 ml/kg and peak flow rate of 7.11/min. Owing to the anticipated short duration of mechanical ventilation, the FiO<sub>2</sub> was not decreased.

Approximately 2 h into treatment, severe hemorrhage from the hemodialysis catheter site was noted. The cat became hypotensive with a blood pressure that was too low to read via Doppler, with absent femoral pulses, as well as tachycardic (HR 225 bpm). An ACT at that time was markedly prolonged at >999 s and packed cell volume was measured at 24% (RI 37–55) so heparin therapy was temporarily discontinued. A bolus of 3 ml/kg hypertonic saline (Hypertonic Saline 7.2% Solution; Bimeda-MTC Animal Health) was administered IV for intravascular volume expansion. The cat was blood-typed; however, a cross-match was not performed owing to the acute nature of the hemorrhage. The cat was then administered 7.5 ml/kg type-specific feline packed RBCs and 5.7 ml/kg of fresh frozen plasma (FFP) over 1 h. Heparin therapy was restarted (dose range 10–24 units/kg/h) when an ACT measured 118 s immediately after transfusion. The patient remained hemodynamically stable thereafter. The total blood volume processed was 23.3 l and the total ultrafiltration volume was 470 ml. Heparinized whole-blood samples were collected, and serum samples were frozen to be sent at a later date for batch analysis of serum baclofen levels using mass spectrometry at an outside laboratory (Analytical Chemistry Research Laboratory; VA-MD College of Veterinary Medicine) at 0, 60, 180 and 300 mins during dialysis, and again 2 h post-dialysis. Though not available at the time of hospitalization, serum concentrations at these time points were as follows: 1495.4 ng/ml, 227.7 ng/ml, 168.4 ng/ml, 291.5 ng/ml and 333.3 ng/ml, respectively, for an overall percent reduction in serum baclofen concentration of 77.7%, after 5 h of hemodialysis (Figure 1).

Approximately 10 mins before the conclusion of dialysis, the cat was weaned from the ventilator and extubated as it started to take spontaneous breaths and attempted

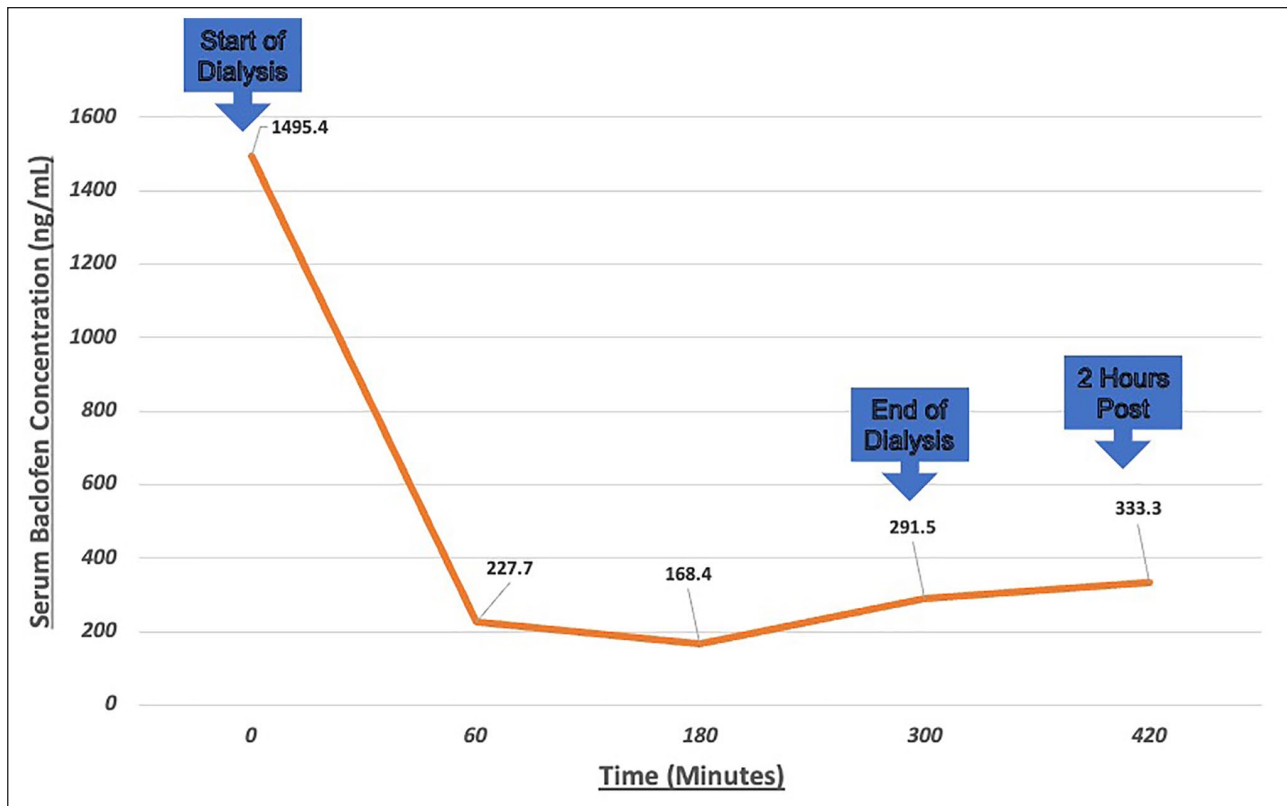
to chew on the endotracheal tube. Ongoing treatment included IV LRS at 50 ml/kg/day. It was noted to have a significant improvement in muscle tone, becoming weakly ambulatory within 1 h of the end of dialysis. Blood gas analysis 2 h after treatment revealed resolution of the hypercapnia and acidemia (Table 1), and neurologic signs had completely resolved 12 h after completion of dialysis. Owing to the CBC findings of leukocytosis by the cat's primary veterinarian, as well as the bacteria, pyuria and azotemia, there was concern for pyelonephritis and it was started empirically on cephalexin 23 mg/kg PO q8h, and management for CKD was recommended. Culture and sensitivity of the urine obtained at presentation was performed, and later revealed growth of *Escherichia coli* bacteria with a colony count of >1,000,000 colony-forming units/ml, which was susceptible to cephalexin. The patient was discharged 24 h after presentation.

The cat had a follow-up appointment 1 week later and the owner reported no recurrence of clinical signs, with normal behavior and appetite at home. Blood work performed revealed persistent mild azotemia (Table 1). Additionally, a CBC revealed a non-regenerative anemia of 18% (RI 34–51), with an aggregate reticulocyte count of 8.7 K/µl (RI 0–30) and a normal white blood cell count. Four months after discharge, the cat was reported to be doing well and was continuing treatment with the primary veterinarian for the pre-existing CKD.

## Discussion

This case report describes the management of severe baclofen toxicosis in a cat with severe neurologic signs, including tetraplegia, absent menace response and weak gag reflex, and ventilatory failure using hemodialysis and mechanical ventilation. The mechanism of action of baclofen is not well understood, but it is believed to reduce central excitatory neurotransmitter release in the presynaptic neuron and increase central inhibitory neuronal signals in the postsynaptic neuron.<sup>1</sup> In this cat the clinical signs manifested as CNS depression, vomiting, ataxia, flaccid paralysis and respiratory depression. Other clinical signs that this cat did not display but which are common in people with baclofen toxicosis include cardiac arrhythmias and seizures.<sup>4</sup> Owing to the flaccid paralysis and respiratory depression caused by baclofen, approximately 48% of cases acute intoxication in humans require the use of mechanical ventilation for supportive care with a median time of 32 h and a range from 2 h to 105 h.<sup>10</sup> In this case, mechanical ventilation was required for approximately 3 h. The extracorporeal blood removal of baclofen likely shortened the duration of mechanical ventilation required in this cat, improving its ventilatory function when plasma levels were decreased. To date, there have been no studies on the pharmacokinetics of baclofen in the cat to include peak serum concentrations,





**Figure 1** Serum baclofen concentrations in a cat with severe toxicity managed with hemodialysis and mechanical ventilation

half-life, volume of distribution or clearance. In humans without renal disease, the peak serum concentration occurs 2–3 h post-administration and the half-life ranges from 3 to 6.8 h.<sup>7</sup> Following first-order kinetics, approximately 60–85% of serum baclofen is predominantly cleared through passive glomerular filtration of the unchanged drug in the kidneys. The remaining 15% is metabolized in the liver through deamination.<sup>11</sup> Lethal doses have not been established as there are very few reported cases of baclofen ingestion in cats.<sup>4,5</sup>

Conventional therapy for baclofen overdose or intoxication includes decontamination via emesis in non-clinical patients, gastric lavage and a single administration of activated charcoal.<sup>4,12</sup> Owing to baclofen's moderately lipophilic nature, toxicosis has also been successfully managed with IV lipid emulsion therapy.<sup>4,13</sup> Owing to the severity of neurologic signs observed in this cat, conventional management was not indicated. The pharmacology of baclofen shows low molecular weight (214 Da), low-to-moderate volume of distribution (0.8–2.5 l/kg) and relatively low protein binding (30%).<sup>6,7</sup> For these reasons, hemodialysis with or without hemoperfusion are alternative therapeutic options for the management of severe baclofen toxicity. Hemodialysis has been successfully used to treat baclofen intoxication in people and dogs.<sup>4,8,14,15</sup> In one case report of a dog with severe baclofen toxicity, hemodialysis and mechanical ventilation were

used with a successful outcome.<sup>9</sup> In this cat, mechanical ventilation was required to support the patient while hemodialysis was being used to clear the toxin from its system.

It has been demonstrated that impaired renal function can increase the average half-life of baclofen up to 7.8–14.1 h in people with CKD.<sup>7,14</sup> Hemodialysis is a common therapeutic intervention in people with baclofen toxicosis and impaired renal function.<sup>16–19</sup> The use of hemodialysis has been shown to reduce the half-life of baclofen in people with impaired renal function, from 15.5 to 2.06 h and from 12.6 to 3.7 h in two cases, respectively.<sup>7</sup> Owing to large variation in the range of volume of distribution in people, and the unknown volume of distribution in cats, a 5 h hemodialysis session was performed to compensate for the suspected moderate volume of distribution and redistribution from the tissues over the course of a more extended session. Redistribution of baclofen was identified in the cat's serum baclofen analysis with a rebound concentration of 291 ng/ml at the end of dialysis and 333 ng/ml 2 h post-dialysis (Figure 1). The development of severe hypercapnia in this patient necessitating mechanical ventilation, coupled with the evidence of impaired renal function, would have very likely prolonged the time of ventilatory support and intensive care had hemodialysis not been performed.

Complications associated with hemodialysis include dialysis catheter occlusion and thrombosis, hemorrhage

from systemic heparinization during hemodialysis treatment, air embolization and blood loss through clotting of the extracorporeal circuit.<sup>20</sup> Hemodialysis can also reduce serum phosphorus levels below the normal range, increasing the risk of hemolysis and anemia. For this reason, phosphate supplementation was part of the dialysis prescription in this case, to prevent hypophosphatemia and risk of RBC lysis.<sup>21</sup>

In this cat, the anemia observed during the dialysis treatment and after dialysis was likely associated with acute hemorrhage, and not likely secondary to RBC lysis, but serum phosphorus levels were not monitored in this patient. Additionally, when evaluating spun PCV values during and after dialysis, there was no evidence of hemolysis in the serum. It is routine to frequently measure ACT, to monitor the degree of heparinization during hemodialysis. Despite frequent monitoring, over-heparinization can occur, placing the patient at risk of spontaneous bleeding. It was noted during the hemodialysis treatment that significant bleeding had occurred around the dialysis catheter and the cat was given a transfusion of both packed RBC and FFP. The total priming volume of the neonatal hemodialysis circuit and dialyzer is 68 ml, which corresponds to 24% of this patient's total blood volume (60 ml/kg). The tubing and filter were initially primed with LRS, which may have caused hemodilution and may have also contributed to this patient's decrease in hematocrit once dialysis was initiated. Priming the tubing and dialyzer with blood products could have potentially reduced the risk of complications secondary to hemodilution and acute hemorrhage secondary to over-heparinization. While preemptively performing a blood type and a crossmatch would have been ideal before the beginning of dialysis in preparation for a possible transfusion and to reduce the risk of a transfusion reaction, due to the emergent and critical nature of the case these tests were not performed. The rapid resolution of the clinical signs and shortened period of mechanical ventilation using hemodialysis in this cat suggest that the use of hemodialysis should be considered in the management of severe baclofen toxicosis in cats despite its potential complications.

While it is common to use a combination of therapeutic agents to facilitate mechanical ventilation, including propofol, ketamine, opioids, benzodiazepines and alpha-2 agonists, this cat was maintained on a single-agent CRI of propofol for the duration of mechanical ventilation. Propofol was selected as a single agent owing to the anticipated short duration of mechanical ventilation, the rapid onset of action and because clearance is primarily achieved via hepatic metabolism rather than renal excretion. Manual ventilation was initially selected over mechanical ventilation because a relative rapid return of neurologic function was anticipated once hemodialysis was initiated. Neurologic and respiratory function did not improve as rapidly as anticipated and a subsequent partial pressure of carbon dioxide (pCO<sub>2</sub>) measurement revealed progressive hypercapnia in the face of manual ventilation so

mechanical ventilation was initiated. In hindsight, mechanical ventilation would have been a more appropriate initial therapy and would likely be indicated over manual ventilation in future cases.

## Conclusions

This is the first report of baclofen toxicosis in a cat with renal dysfunction successfully treated with hemodialysis and mechanical ventilation. Treatment with hemodialysis therapy and mechanical ventilation could be considered in cases of acute baclofen toxicosis to improve outcome and reduce the time of mechanical ventilation in cats.

**Author note** This case report was presented as an abstract at the International Veterinary Emergency and Critical Care symposium, New Orleans, LA, 14–17 September 2018.

**Conflict of interest** The authors declared no potential conflicts of interest with respect to the research, authorship, and/or publication of this article.

**Funding** The authors received no financial support for the research, authorship, and/or publication of this article.

**Ethical approval** The work described in this manuscript involved the use of non-experimental (owned or unowned) animals. Established internationally recognized high standards ('best practice') of veterinary clinical care for the individual patient were always followed and/or this work involved the use of cadavers. Ethical approval from a committee was therefore not specifically required for publication in *JFMS Open Reports*. Although not required, where ethical approval was still obtained, it is stated in the manuscript.

**Informed consent** Informed consent (verbal or written) was obtained from the owner or legal custodian of all animal(s) described in this work (experimental or non-experimental animals, including cadavers) for all procedure(s) undertaken (prospective or retrospective studies). No animals or people are identifiable within this publication, and therefore additional informed consent for publication was not required.

**ORCID iD** Leonel A Londoño  <https://orcid.org/0000-0002-8023-926X>

## References

- 1 Ghanavati S and Armen D. **Baclofen**. In: StatPearls e-book. Baltimore, MD: National Center for Biotechnology Information National Institutes of Health, 2018.
- 2 Teague CT and Merrill DC. **Effect of baclofen and dantrolene on bladder stimulator-induced detrusor-sphincter dyssynergia in dogs**. *Urology* 1978; 5: 531–535.
- 3 Plumb DC. *Plumb's veterinary drug handbook*. 9th ed. Stockholm, WI: Wiley-Blackwell, 2018.
- 4 Khorzad R, Lee JA, Whelan M, et al. **Baclofen toxicosis in dogs and cats: 145 cases (2004–2010)**. *J Am Vet Med Assoc* 2012; 241: 1059–1064.
- 5 Castillo D and Pitts T. **Influence of baclofen on laryngeal and spinal motor drive during cough in the anesthetized cat**. *Laryngoscope* 2013; 123: 3088–3092.

- 6 Monaghan KN and Acierno MJ. **Extracorporeal removal of drugs and toxins.** *Vet Clin North Am Small Anim Pract* 2011; 41: 227–238.
- 7 Wolf E, Kothari NR, Roberts JK, et al. **Baclofen toxicity in kidney disease.** *Am J Kidney Dis* 2018; 71: 275–280.
- 8 Scott N, Francey T and Jandrey K. **Baclofen intoxication in a dog successfully treated with hemodialysis and hemoperfusion coupled with intensive supportive care.** *J Vet Emerg Crit Care* 2007; 17: 191–196.
- 9 Torre DM, Labato M, Rossi T, et al. **Treatment of a dog with severe baclofen intoxication using hemodialysis and mechanical ventilation.** *J Vet Emerg Crit Care* 2008; 18: 312–318.
- 10 Leung NY, Whyte IM and Isbister GK. **Baclofen overdose: defining the spectrum of toxicity.** *Emerg Med Australas* 2006; 18: 77–82.
- 11 Young RR and Delwaide PJ. **Drug therapy: spasticity.** *N Engl J Med* 1981; 304: 96–99.
- 12 Wismer T. **Baclofen overdose in dogs.** *J Vet Med* 2004; 99: 406–408.
- 13 Becker MD and Young BC. **Treatment of severe lipophilic intoxications with intravenous lipid emulsion: a case series (2011–2014).** *Vet Med (Auckl)* 2017; 8: 77–85.
- 14 Hsieh MJ, Chen SC, Weng TI, et al. **Treating baclofen overdose by hemodialysis.** *Am J Emerg Med* 2012; 30: 1654. DOI: 10.1016/j.ajem.2011.07.013.
- 15 Wu VC, Lin SL, Lin SM, et al. **Treatment of baclofen overdose by haemodialysis: a pharmacokinetic.** *Nephrol Dial Transplant* 2005; 20: 441–443.
- 16 Chen KS, Bullar MJ, Chien YY, et al. **Baclofen toxicity in patients with severely impaired renal function.** *Ann Pharmacother* 1997; 31: 1315–1320.
- 17 Porter LM, Merrick SS and Katz KD. **Baclofen toxicity in a patient with hemodialysis-dependent end-stage renal disease.** *J Emerg Med* 2017; 52: e99–e100.
- 18 Gee SW, Outsen S, Becknell B, et al. **Baclofen toxicity responsive to hemodialysis in a pediatric patient with acute kidney injury.** *J Pediatr Intensive Care* 2016; 5: 37–40.
- 19 Wuis EW, Dirks MJ, Termond ER, et al. **Plasma and urinary excretion kinetics of oral baclofen in healthy subjects.** *Eur J Clin Pharmacol* 1989; 37: 181–184.
- 20 Hothi DK and Harvey E. **Common complications of haemodialysis.** In: Warady BA and Alexander SR (eds). *Pediatric dialysis*, 2nd ed. New York: Springer, 2012, pp 345–374.
- 21 Haas T, Hillion D and Dongradi G. **Phosphate kinetics in dialysis patients.** *Nephrol Dial Transplant* 1991; 6(S2): 108–113.