

Development of a fast and low-cost age determination method in spotted deer, *Axis axis*

Authors: Vipin, , Sharma, Vinita, Gupta, Sandeep K., Sharma, Chandra P., Sankar, Kalyanasundaram, et al.

Source: *Folia Zoologica*, 67(3-4) : 186-197

Published By: Institute of Vertebrate Biology, Czech Academy of Sciences

URL: <https://doi.org/10.25225/fozo.v67.i3-4.a9.2018>

BioOne Complete (complete.BioOne.org) is a full-text database of 200 subscribed and open-access titles in the biological, ecological, and environmental sciences published by nonprofit societies, associations, museums, institutions, and presses.

Your use of this PDF, the BioOne Complete website, and all posted and associated content indicates your acceptance of BioOne's Terms of Use, available at www.bioone.org/terms-of-use.

Usage of BioOne Complete content is strictly limited to personal, educational, and non - commercial use. Commercial inquiries or rights and permissions requests should be directed to the individual publisher as copyright holder.

BioOne sees sustainable scholarly publishing as an inherently collaborative enterprise connecting authors, nonprofit publishers, academic institutions, research libraries, and research funders in the common goal of maximizing access to critical research.

Development of a fast and low-cost age determination method in spotted deer, *Axis axis*

Vipin^{1,2}, Vinita SHARMA^{1,2}, Sandeep K. GUPTA¹, Chandra P. SHARMA¹, Kalyanasundaram SANKAR^{1,3} and Surendra P. GOYAL^{1*}

¹ Wildlife Institute of India, Dehradun 248001, Uttarakhand, India; e-mail: vipinsharma_24@yahoo.com, vinita302003@gmail.com, skg@wii.gov.in, cpsharma@wii.gov.in, ksankar62@yahoo.com, goyalsp@wii.gov.in

² Department of Zoology, Central University of Jammu, Rahya-Suchani (Bagla), District Samba, Jammu 181143, Jammu and Kashmir, India

³ Salim Ali Centre for Ornithology and Natural History (SACON), Anaikatty P.O. Coimbatore, Tamil Nadu 641108, India

Received 29 December 2017; Accepted 15 October 2018

Abstract. We developed a protocol which determines age in spotted deer, *Axis axis* (Erxleben, 1777) through cementum layers in the tooth which is economical and requires lesser time (± 19 hours). The permanent first incisor teeth from mandibles of known estimated ages (2, 4, 5, 8 and 9 years) were ground longitudinally on median plane on a set of sandpapers with hand to a thickness of around 57 μm , decalcified, stained with hematoxylin, differentiated in acid alcohol and mounted on a glass slide and count cementum layers under microscope at 100 or 200 \times magnification. Presence of 1, 3, 4, 7 and 8 cementum layers was observed for the tooth of ages of 2, 4, 5, 8 and 9 years, respectively. The final age in the year was calculated by adding one to the counted number of cementum layer. Our results were in compliance with the pre-estimated age of the mandibles. This suggested protocol saves time and money and is easy to perform with minimum requirements. The technique was validated using “blind” duplicate test ($n = 2$) and the first molar tooth of known estimated age ($n = 1$). Our suggested protocol has significant relevance for estimating the age of other animals and wildlife forensics.

Key words: incisor, cementum layers, epoxy-tooth section complex, Sariska Tiger Reserve

Introduction

Determining age in a wide range of animals, both domestic and wild, has been practiced since the mid of the twentieth century throughout the world. Different methods starting from the tooth eruption (Andrews 1981), x-ray (Simon & Frydendall 1981), cementum layers count (Matson et al. 1993), tooth wear (Stander 1997) and the length of the telomere (Hausmann & Vleck 2002) have been the choice of researchers for determining the age. Among these methods, cementum analysis has been favoured for its maximum accuracy in determining the age of an animal (Mundy & Fuller 1964, Marks & Erickson 1966, Klevezal & Kleinenberg 1967, Craighead et al. 1970, Willey 1974, Johnston et al. 1987, Matson et al. 1993, Mbizah et al. 2016). The technique requires high level of expertise at each step i.e. extraction of the tooth from the bone, decalcification, taking fine section (longitudinal or transverse), staining and layers counting under a microscope. The technique

is too much costly and a time taking process. Due to these reasons this technique is not available to the laboratories where researchers are doing basic research related to age estimation and they completely have to depend on few laboratories which are present around the world for getting these services on commercial basis.

Therefore, we have developed a protocol which estimates the age using cementum layer count in the permanent first incisor tooth of spotted deer, *Axis axis* (Erxleben, 1777). We have made our protocol more economical by completely removing the main instrument required for taking the sections of tooth i.e. the microtome without compromising the quality of the results. We replaced the step of traditional sectioning of the tooth by microtome with a very simple and easy to perform hand grinding method giving a section of a thickness around 57 μm . Since, this is the first of its kind of study to determine age in spotted deer through cementum layers count a large research data on more

* Corresponding Author

number of individuals from different populations need to be developed to further prove its validation, precision, and accuracy. Hence, any researcher may use this protocol to estimate the age in spotted deer with minimum expertise, instrumentation, time and money requirements. The same technique holds a significant relevance for developing age estimation protocols in other animals also.

Though some studies have used grinding of the tooth from single (Roulichová & Anděra 2007) or both the sides (Gupta et al. 2014) but they have not used staining as we have done in the present study. Their results were also not comparable to the studies which have used both the histological sectioning and the staining.

Material and Methods

Sample collection: we used mandibles of the naturally dead or predator killed spotted deer collected from the Sariska Tiger Reserve, Rajasthan, India during 1988-1991. Incisor (left or right) was extracted without damaging root from these mandibles for determining age using cementum layers count. Teeth from five mandibles whose ages were predetermined previously for 2, 4, 5, 8 and 9 years from Matson's Laboratory, Manhattan, U.S.A. were used to estimate the age of spotted deer in this study (Fig. 1). The details about date of collection, tooth used, and age of the animal is given in Table 1.

The procedure followed for estimating age from incisor

Selection of tooth for grinding: the permanent first incisor tooth from mandible was selected mainly because of the ease of obtaining it from the mandible and of having only one root in comparison to more than one in premolars and molars. Out of three incisor teeth in a mandible only the first incisor of the left or right mandible, depending upon the availability, was selected because of its more straightness in comparison to other incisors which helps in easy grinding. The

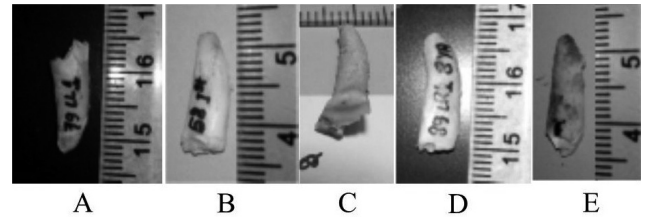


Fig. 1. The first incisor teeth of spotted deer of the ages of 2 (A), 4 (B), 5 (C), 8 (D) and 9 (E) years.

other reasons for the selection of the first incisor have been discussed in detail in the discussion section.

Selection of plane of the tooth for grinding: the median plane of the tooth was selected for grinding because grinding in the labiolingual plane may result in loss of some cementum layers leading to false age determination.

Taking a longitudinal section of the tooth by grinding on sandpapers with hand (timing: 40 min)

We took longitudinal sections instead of cross sections of teeth because of the following reasons. The cross section taken from a portion where two or more number of annuli is not distinct from one another, then this makes it very difficult to count the correct number of annuli (Miller 1974) and the cross section may not give the correct age estimation. Sometimes, it also has been seen that a portion of cementum has lost from the tooth and if, this portion is present in the transverse section then this also did not give the correct age estimation (Matson et al. 1993). These single point defects do not hinder the counting of correct number of cementum layers in longitudinal sections.

(1) The first incisor tooth from the mandible of spotted deer of the known estimated age of 2, 4, 5, 8, and 9 years was extracted with the help of a plier with utmost care so that cementum layers in root part of the tooth are not damaged. From here now we will describe the processing of one incisor tooth, and for the rest, same steps will apply (timing: 5 min/tooth).

Table 1. Details of the teeth used for age estimation.

S. No.	Tooth used	Mandible side	Mandible no.	Pre-estimated age of animal in years	Date of collection
1	the first incisor	Left	79	02	14-11-1989
2	the first incisor	Right	58	04	-
3	the first incisor	Right	91	05	02-08-1989
4	the first incisor	Right	89	08	-
5	the first incisor	Right	45	09	23-05-1988
6	the first incisors	Right & Left	289	Unknown	08-05-1991
7	the first molar	Right	82	04	03-11-1989

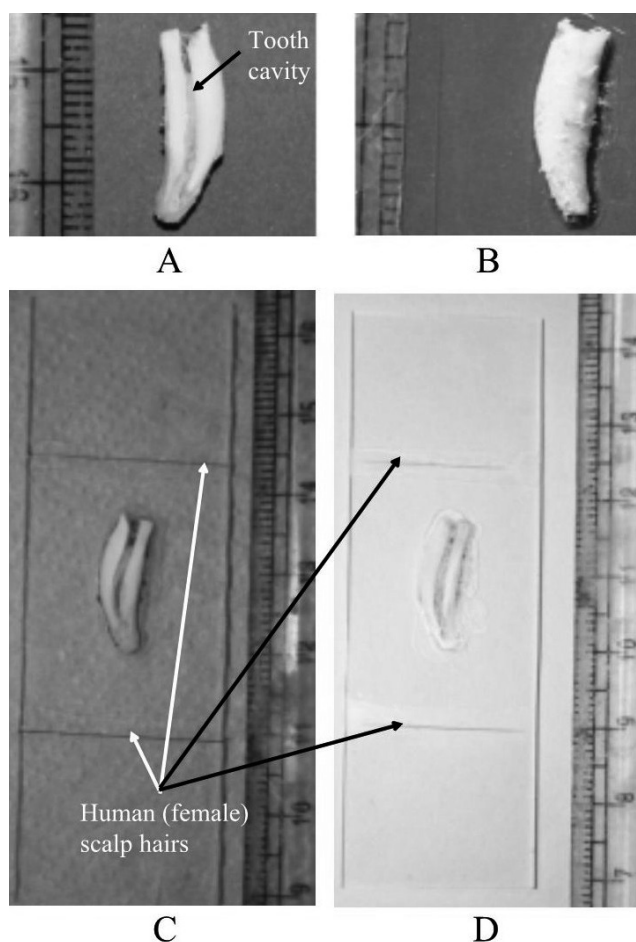


Fig. 2. Images of tooth ground from one side (A), tooth pasted on slide from the grounded side (B), two human (female) scalp hairs pasted on the flanking sides of tooth on slide (C) and slide showing tooth section grounded up to the thickness of hairs as pertinent from hair's ends also getting grounded (D).

(2) The tooth was ground longitudinally on the median plane with the help of a hand on a set of three sandpapers. Different sandpapers of 600, 1200 and 1500 grits (“DEERFOS” brand) were used in sequence to obtain a very fine surface. The tooth was ground till the tooth cavity appears, and it is grounded to the half of its diameter starting from crown to the root tip (Fig. 2A), (timing: 15 min).

(3) The tooth from the side of the ground face was pasted on a clean glass slide with the help of an instant epoxy adhesive “Fevi kwik” and left for five minutes (Fig. 2B), (timing: 5 min).

(4) Two human (female) scalp hairs, one on each side of the fixed tooth on a glass slide, were pasted using instant epoxy adhesive “Fevi kwik” (Fig. 2C).

(5) The other non-ground side of the tooth was grounded as per the step two until the hairs on both sides start touching the sandpaper. As the thickness of female human scalp hair is 57 μm , the longitudinal




Fig. 3. Epoxy-tooth section complex.

section we got will be of a thickness around 57 μm (Neste 2004), (Fig. 2D); (timing: 15 min).

Decalcification (timing: 18 hours)

(1) The slide having the longitudinal section of the tooth was placed in a 60 \times 15 mm glass Petri dish with tooth section facing upside.

(2) 10 ml of Jenkin's fluid (Culling 1957), the decalcification solution, was added to the Petri dish, covered with glass lid and left for decalcification for 18 hours. The decalcification solution was made by mixing 73 ml of absolute ethyl alcohol, 10 ml distilled water, 10 ml chloroform, 3 ml glacial acetic acid and 4 ml concentrated hydrochloric acid.

(3) The complete decalcification was confirmed by the disappearance of the crown from the tooth section.

Removal of decalcification solution from tooth section through washing with distilled water (timing: 6 min)

(1) After 18 hours the epoxy having embedded decalcified tooth section in it automatically detaches itself from the glass slide. We named this epoxy embedded decalcified tooth section as “epoxy-tooth section complex” in further steps of the protocol

until the tooth section is detached from this complex (Fig. 3). This “epoxy-tooth section complex” has a very crucial role in maintaining the original shape of longitudinal section of the tooth in successive steps which will be explained later.

(2) The “epoxy-tooth section complex” was washed in 10 ml of distilled water in a glass Petri dish for two minutes thrice to remove the decalcification solution.

Staining and washing (timing: 1.16 hour)

(1) We used a modified method of hematoxylin staining method to get the differential cementum layers (Cable 1958, Goodwin & Ballard 1985). Our staining procedure is different as we used “epoxy-tooth section complex” for staining in place of directly using the tooth section which is done in most of the studies (Cable 1958, Goodwin & Ballard 1985, Matson et al. 1993).

(2) A 2 ml centrifuge tube was filled with 1 ml of hematoxylin staining solution and the washed “epoxy-tooth section complex” was dipped vertically into it with the help of a very fine painting brush, and the lid was closed. The care was taken that the entire “epoxy-tooth section complex” was fully dipped into the hematoxylin staining solution.

(3) The centrifuge tube was then placed vertically in a shaker water bath for incubation at 45 °C for one hour.

(4) After taking out the centrifuge tube from the water bath, the staining solution was decanted in a clean glass Petri dish. After this, the “epoxy-tooth section complex” either remained in centrifuge tube, or it comes in Petri dish. Whichever it might be the case the “epoxy-tooth section complex” was rinsed in running tap water for five minutes.

(5) After that, the “epoxy-tooth section complex” was transferred to a glass Petri dish filled with 10 ml of distilled water with the help of a fine painting brush of zero size.

(6) At this step, the longitudinal tooth section is separated from the epoxy in “epoxy-tooth section complex”. This step was very critical and therefore, carried out very patiently and with soft hands. The epoxy was held by pressing it gently from the margin at the crown end portion of the tooth with the help of a fine forcep in water-filled Petri dish. Then from the side of holding the end, the tip of a very fine brush was inserted below the longitudinal tooth section and moved around the margins so that the tooth section get separated from the epoxy. The root portion of the tooth having cementum layers deposits needs to be detached with utmost care because only at this step are the maximum chances of cementum layers being get lost (timing: minimum 5 min).

Differentiation, mounting, and visualization of tooth sections (timing: 3.3 min)

(1) The longitudinal tooth section was differentiated in acid alcohol (1 % HCl in 70 % ethanol; Goodwin & Ballard 1985) for 10 seconds. This step may be repeated, usually 2-3 times, till we get very clear and distinct cementum layers visible under a microscope.

(2) The tooth section was washed in 10 ml of distilled water in a glass Petri dish for two minutes using a fine brush.

(3) The tooth section was then placed in 1 ml of saturated lithium carbonate solution (Goodwin & Ballard 1985) in a glass Petri dish for one minute which changes its colour from purple to blue.

(4) The tooth section was washed in 10 ml distilled water in a glass Petri dish for 10 seconds and mounted on a clean glass slide with distilled water and covered with a coverslip; the care was taken that no air bubble remained between slide and coverslip. The extra water was absorbed with the help of a tissue paper by pressing it gently around the sides of the coverslip on the slide.

(5) The images were taken under the light compound microscope at 100× and 200×.

Calculation of age from cementum layers

The layers formed by acellular cementum, annually, during the winter season in the root of a tooth which stains dark with hematoxylin stain (Matson et al. 1993) were counted for the estimation of age in spotted deer. The thin growth line forming during the period of autumn to winter which is also called as “rest line” and the other wide growth layers formed during spring to summer (Azorit et al. 2002a) were clearly differentiable from each other. The presence of one dark cementum layer or first rest line in the permanent first incisor tooth of spotted deer indicates that the animal has lived one winter season. The permanent first incisor tooth in spotted deer is present at the age of 13 months (Chapple 1989), so the final age of sectioned tooth may be estimated as a minimum of one year when first rest line is present very close to the dentine-cementum junction but at a clear differentiable distance. However, the age of all five incisors were pre-estimated in this study and the first rest lines in all teeth sections were separated by a broad distance of light growth layers. Therefore, the age of teeth were calculated by adding one to the counted number of dark cementum layer. To calculate the age in months the knowledge of date of death or tooth extraction from live animal should be known. As all teeth used in the present study

were from the mandibles which were collected from already dead animals from Sariska Tiger Reserve, so no information about the date of their death was available. Hence, the age in months could not be calculated here. We believe that if the date of death

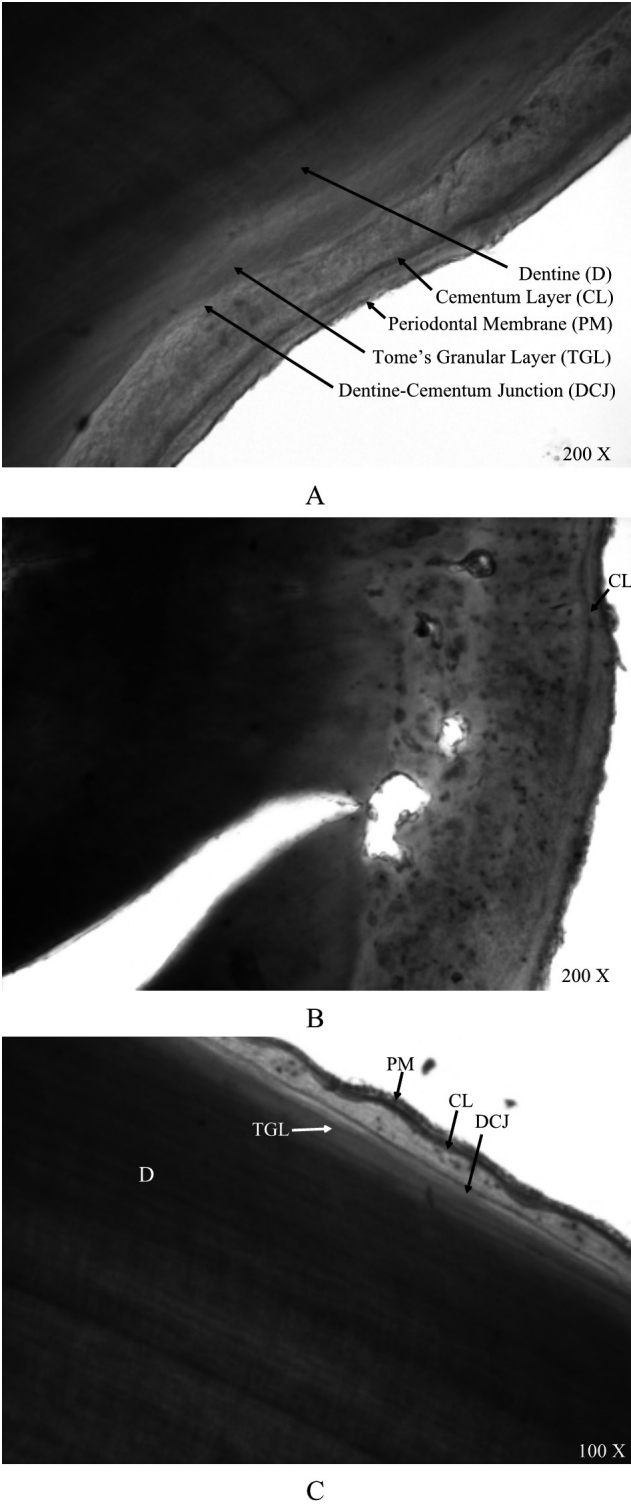


Fig. 4. Two years age tooth (tooth no. 79) showing one cementum layer on the right (A), base (B) and left side (C) of the root part.




Fig. 5. Four years age tooth (tooth no. 58) showing three cementum layers on the left (A) and right (B) side of root part.

or tooth extraction from live spotted deer is known then the age in months may also be calculated with the help of present protocol. While counting the cementum layers we have only counted the major annual component, which is the darkly stained layer and remain prominent throughout the longitudinal section of tooth, in contrast to the minor component or false layers which remain weekly stained. Thus we have avoided the over or underestimation of age through cementum layers count.

Results

The images of hematoxylin stained teeth sections for the estimated ages of 2, 4, 5, 8 and 9 years have been given in (Figs. 4A, B and C), (Fig. 5A, B), (Fig. 6A, B), (Fig. 7A, B) and (Fig. 8A, B), respectively. The cementum layers in different parts of root portion were counted as 1, 3, 4, 7 and 8 for the tooth of ages 2, 4, 5, 8 and 9 years, respectively. The age determined




Fig. 6. Five years age tooth (tooth no. 91) showing four cementum layers on the right (A) and left side (near the base), (B) of root part.




Fig. 7. Eight years age tooth (tooth no. 89), arrows showing seven cementum layers on the left (A) and right (B) side near the base of root part.

for each incisor was similar to pre-estimated age of the respective mandible used in the present study.


It is to mention here that we did not specify any particular location in the root of the tooth for counting cementum layers. But the efforts have been made to include cementum layers photographs from left, right and base of the root. Hence, wherever the cementum layers were clear and distinct, they were photographed.

Validation of current method using a “blind” duplicate test and a tooth of known age


According to the Matson et al. (1993), the two best tests to check the reliability of cementum aging techniques are first, the “blind” duplicate test where two teeth from the same animal are used for aging and second, aging a known age tooth without the prior knowledge of age. Since we could not get the teeth of spotted deer from an animal of known age, we validated our results using above mentioned two tests.

“Blind” duplicate test: we determined the age of right and left permanent first incisor teeth from the jaw bones of an animal of unknown age (mandible no. 289). In results, we got six cementum layers and there was a broad gap of light growth layers in each tooth which indicated that the animal was of seven years of age (6 + 1), (Fig. 9A, B).

Known estimated age tooth was aged without the prior knowledge of age: we determined the age of a right side mandible (mandible no. 82) of known estimated age, however, its age was not revealed to us until we calculated its age using the current method. Because no incisor tooth was present in the mandible we processed the single root of the first molar tooth. In results, four cementum layers were observed which indicated that the age of animal was of four years, which also coincides with the predetermined age of mandible i.e. four years (Fig. 10A, B and C).



A




B

Fig. 8. Nine years age tooth (tooth no. 45) showing eight cementum layers on the right side of root (A) and near the base (B).


Discussion

Though many studies in a number of species have used tooth grinding techniques for the estimation of age but either the sections made by them were not of a good quality or they have not done staining or if they have done the both then the results were not up to their satisfaction (Low & Cowan 1963, Roulichová & Anděra 2007, Gupta et al. 2014). We describe a technique for the estimation of age from incisor in spotted deer which uses hand ground tooth section with a thickness of around 57 μm and stained with hematoxylin.

The tooth sections ranging between thicknesses of 10 to 95 μm have been used by different researchers in the past for the estimation of age through cementum layers (Low & Cowan 1963, Erickson & Seliger 1969,



A



B

Fig. 9. Longitudinal sections of left (A) and right (B) the first incisor tooth from the same spotted deer individual showing six cementum layers.

Stoddart 1974, Goodwin & Ballard 1985, Matson et al. 1993). Determination of age of mule deer (*Odocoileus hemionus*) using the permanent first incisor teeth through cementum layers have shown that the tooth section of a thickness of 95 μm can generate the as accurate result as a section of 10 μm can give (Low & Cowan 1963, Erickson & Seliger 1969). Therefore, we believe that our estimated thickness (around 57 μm) should be sufficient enough to reveal all necessary structures in a tooth section which are required to calculate the age through cementum layers.

Mostly, the first incisor or molar has been widely used in age estimation using cementum layers count in deer species (Sergeant & Pimlott 1959, Mitchell 1963,




Fig. 10. „Blind“ test performed on a single root of the right first molar tooth (tooth no. 82) of spotted deer showing four cementum layers in three different regions (A, B and C).

1967, Grue & Jensen 1979, Hamlin et al. 2002). Low & Cowan (1963) also used first incisors to determine age in mule deer (*Odocoileus hemionus*) through cementum layers on the merits of having a single root

which makes them easy to handle in comparison to molars and they are the first replacement dentition. Lastly, to have a better comparison between the results obtained earlier from Matson's laboratory and our aging methods we did not change the tooth type i.e. the first incisors.

It has been found that the first rest line in the permanent first incisor tooth is formed during the second winter in an animal's life and not during the first winter (Azorit et al. 2002b). This is why it is necessary to add one to the number of counted lines in order to obtain the correct age (Klevezal & Kleinenberg 1967, Erickson & Seliger 1969). However, the general rule of adding one to the number of lines is not always adequate, as some authors noted in other species of ungulate and carnivore or teeth and it can also vary with the type of tooth and its eruption (Zapata et al. 1995, Azorit et al. 2004).

The information about the first rest line formation in spotted deer is not available, so it is very difficult to say anything specific about it until more research data is collected on this topic. As it has earlier been mentioned that the first permanent incisor in spotted deer is present at the age of thirteen months (Chapple 1989) so, we added one to the counted number of cementum layers to calculate the correct age. Some authors have preferred the first molars since they are the first permanent teeth to appear while incisors have milk predecessor that may take time to be replaced (Mitchel 1967, Azorit et al. 2002b, 2004). We had to use the first molar of known age of four years, as we did not have extra incisors to perform the validation of our method, where we observed four cementum layers instead of three as in incisors. Because, in spotted deer, the permanent first molar teeth erupt at the age five months (Chapple 1989), so we assumed that first winter line should be present in the first year of an animal's life and we found four cementum layers in the tooth of four years of age. Stoddard (1974) used the first lower molar teeth which are well grown at four to five months of age to determine the age in roe deer (*Capreolus capreolus*) using cementum layers. He found the same number of cementum layers, for most of the teeth studied, as was their age which was determined by tooth wear. However, more data on cementum analysis for permanent first molars in spotted deer need to be generated to validate and prove our assumption. The present methodology has reconfirmed the age in years for the mandibles of five age classes as was estimated earlier by the Matson's Laboratory, the results of this methodology are comparable with microtome procedure because

Matson's Laboratory had also used microtome while determining the ages of same mandibles earlier through incisors.

The accuracy of age determination method through cementum layers has been a key issue. Hamlin et al. (2000) while primarily using the first incisor teeth of known ages from 1 to 14 years found that cementum layers method of Matson's Laboratory determined their ages with accuracy of 97.3 %, 92.6 % and 85.1 % for Rocky Mountain elk (*Cervus elaphus*), mule deer (*Odocoileus hemionus*) and white-tailed deer (*Odocoileus virginianus*), respectively. Our data of age estimation based on cementum layers count is similar and matched to what has been estimated by Matson's Laboratory. The present paper is basically to describe a simple protocol, therefore, we suggest to generate more and more data to further study the accuracy. It has also been seen that the accuracy percentage decreases on the higher side of age in comparison to lower side of age (Hamlin et al. 2000). Seasonal nutritional fluctuations, geographic and physiological differences are known to affect age estimation through cementum layers count. So we suggest that all these factors need to be analyzed for spotted deer with additional samples in future.

The suggested technique has relevance in determining the age in years of other wild and domestic animal species through cementum layers count. The researchers doing age-related studies may use this technique for calculating the age from the tooth. Provided that the current technique is fast and cost-effective a large numbers of teeth can also be processed to get more robust results for age estimation by the researchers without worrying for time and money. The technique may be used in wildlife forensics to know the age of a victim animal from the tooth, if present, especially when there is a need of age-related data for a particular species in illegal wildlife trade to know which age class of that species is, more prone to poaching. This will help authorities in paying more attention towards that targeted group.

The proposed technique has worldwide direct applications in age determination from tooth sections, however, our protocol may be used where microscopic thin sections of other hard materials are regularly made for different scientific studies by scientists and researchers throughout the world.

Advantages, disadvantages, precautions, and troubleshooting

The advantages of suggested technique at different stages are as follows: in brief, the main advantages

of this technique are its cost-effectiveness, easy to perform and less time-consuming in comparison to other techniques which are used in age determination through cementum layers count in the root of a tooth. In detail, they are listed as:

(1) Reversal of order of steps for making microscopic tooth section: we made tooth section first instead of decalcifying it before it is sectioned which was routinely practiced previously by the researchers. This cut the time required in decalcification, minimized the damages caused by the prolonged contact of decalcification solution to the structure of the tooth and also removed the very critical step of setting of the decalcified tooth in the correct orientation while making of wax block.

(2) Making longitudinal sections by hand grinding: making longitudinal section of the tooth by grinding on a set of sandpapers with the help of hands removes the need of a costly electric grinder. Hand grinding also gives a thorough control on grinding as the incisor tooth is very small in size and thickness and the use of electric grinder may do over grinding if speed is not controlled very carefully.

(3) Instant fixing of a ground tooth on glass slide: the use of instant epoxy adhesive "Fevi kwik" reduces the time of fixing of a ground tooth on a glass slide to five minutes, while other epoxy adhesives take more time.

(4) Removal of the need for a costly microtome and other steps involved in microtomy: making longitudinal section of the tooth as thin as 57 µm by grinding on a set of sandpapers with hands without using a microtome is the main key feature of this technique. The tooth section quality is equal to that of published in the literature using a microtome while determining age through cementum layers count in teeth of different animal species. Thus costly microtome is not needed. It also reduces other steps involved in microtomy like tissue fixation, making of wax blocks, taking sections and the expertise and labor required in all these steps.

(5) Fast and cost-effective decalcification of tooth: this method uses around 57 µm thin tooth sections for decalcification which takes very less time i.e. 18 hours. However, in other studies, the decalcification time was between 36-72 hours because the complete tooth was used for decalcification (Goodwin & Ballard 1985, Roulichová & Anděra 2007). The chemical reagents required (concentrated hydrochloric acid, chloroform, ethanol, and water) to make Jenkin's fluid are generally present in all molecular laboratories. So, it is very easy to make decalcification solution which also costs much less (around 0.2 USD/10 ml as

required for each tooth section) in comparison to other commercially available decalcification solutions.

(6) Time and water saving acid removal from tooth: in most of the previous studies the acid removal from the tooth is done under the flow of running water for 24 or more hours (Culling 1957), which may be because in these studies the complete tooth was decalcified and it took more time to completely remove the acids from it. However, this method takes only six minutes (three times for two minutes) time and 30 ml of distilled water to completely remove the acids from a decalcified tooth section as it's thickness is very less in comparison to a whole tooth.

(7) Maintaining of shape of tooth section through acid removal and staining phases by the invention of a unique structure "epoxy-tooth section complex": though, the "epoxy-tooth section complex" helps in maintaining the original shape of the longitudinal tooth section when it passes through the different steps of removal of decalcification solution, staining and again washing in running water, but its main important role is in preventing the cementum as well as complete tooth section from turning wavy or becoming curly under the effect of temperature during staining in hot water bath as it happened when we have not invented the "epoxy-tooth section complex". Hence, the complex keeps tooth section stretched and prevented it from becoming deformed. When the tooth section is stained without the use "epoxy-tooth section complex" in the entire process, the cementum layers appeared wavy and created a problem in proper counting of them, and false age count results were obtained in that case.

(8) No deformation of tooth section structure was noticed after a prolonged decalcification: we did not notice any deformation effect on the structure of tooth section after it was left in decalcification solution for a week. The deformation in original tooth section was observed when decalcification was done for a prolonged period in other studies (Evans et al. 2007).

Disadvantages

Complete consumption of tooth: the main disadvantage of this technique is that it utilizes the complete tooth when processing it for getting a longitudinal section. However, when weighed against the results of a microtome made section it is equivalent to that as only the longitudinal section from median region contains all cementum layers. Thus we do not think complete consumption of tooth is a draw-back when estimating the age using cementum layers count or unless the part of a tooth has to be saved for some other purpose.

Precautions

Avoiding causes of error while determining age through cementum layers: we advise to the readers to consider all precautions like keeping in view the variable distance of the first growth layer from the dentine-cementum junction, reading of complex layers correctly to avoid over or under age determination, taking care of an abnormal or missing portion of the tooth and of indistinctly stained layers. All these precautions have been suggested and well described in detail by Matson et al. (1993) for avoiding sources of errors when determining age through cementum layers count. The same has also been taken care in the present methodology.

Troubleshooting

The ultimate goal of this protocol is to get the clearly distinct and countable cementum layers in the root part of a tooth for estimating the accurate age of spotted deer. If there is any difficulty in reaching final and conclusive results about estimating of age, there might be any of the reason given below with suggestive measures for troubleshooting them.

(1) Loss of periodontal membrane and cementum layers: a) Improper extraction of tooth: improper extraction of the tooth from mandible may destroy periodontal membrane and cementum layers resulting in false age estimation. Suggested solution: repeat with another incisor tooth.

b) Improper separation of tooth section from epoxy: sometimes periodontal membrane, as well as cementum layers, remains attached on epoxy while separating tooth section from epoxy in "epoxy-tooth section complex". To confirm this epoxy may be mounted on a glass slide with water, covered with a coverslip and examined for lost structures under the light compound microscope. Suggested solution: if confirmed, then we do not have any choice but to try again with a second incisor tooth.

c) Oblique grinding of tooth: when the tooth is ground obliquely, and away from the median plane then tooth section do not present all cementum layers. Due to this less age is estimated for a tooth. Suggested solution: presence of inconsistent tooth cavity in a longitudinal section confirms that the section is oblique. Here, we have to start the entire process again with a new incisor tooth.

(2) No distinct cementum layers: a) Over differentiation of stained tooth: over differentiation of hematoxylin-stained tooth when left in acid alcohol for a longer period than required may result in removal of adequate stain necessary for clear cementum layers

visualization. Suggested solution: wash the tooth section in 10 ml of distilled water for two minutes three times. After this the steps from “Staining and washing (timing: 1.16 hour)” to “Differentiation, mounting, and visualization of tooth sections (timing: 3.3 min)” in material and methods section should be repeated until we get desirable cementum layers.

b) Over or under exposure to light in microscope: sometimes under or over-exposure of light in compound light microscope may cause an error in correct cementum layers counting. Suggested solution: the correct light setting, focusing and other microscope adjustments are suggested until we get clear cementum layers.

c) Shrinkage of tooth section: when the slide is kept for a longer period on the stage of the microscope the heat of light source may cause tooth section to shrink. Suggested solution: we suggest taking out the slide from the microscope and applying distilled water on

the margins of coverslip with the help of a dropper, tapping the coverslip very gently to remove the air and remove the extra water by swabbing with a tissue paper. Another way is to completely re-mount the section again on the slide.

Acknowledgements

We gratefully acknowledge the support of the director and dean, Wildlife Institute of India (WII), Dehradun for allowing this study to be conducted. We would like to thank Dr. Y.V. Jhala, Nodal Officer, Wildlife Forensic and Conservation Genetics Cell and WII for providing the necessary support to carry out this study. We thank Dr. P.K. Mukharji, scientist, Wadia Institute of Himalayan Geology, Dehradun for his valuable suggestions. We thank Mohammad Yaseen, senior technician, WII for helping in systematic arrangement of mandibles. We acknowledge Professor N.K. Tripathi, the dean, School of Life Sciences and Head of the Department, Department of Zoology, Central University of Jammu, Jammu and Kashmir for his valuable suggestions about this study. This study was funded by a grant-in-aid of the Ministry of Environment, Forest and Climate Change, Government of India.

Literature

- Andrews A.H. 1981: Use of second molar eruption in age estimation of cattle. *Res. Vet. Sci.* 31: 65–68.
- Azorit C., Analla M., Hervás J. et al. 2002b: Growth marks observation: preferential techniques and teeth for ageing of Spanish red deer (*Cervus elaphus hispanicus*). *Anat. Histol. Embryol.* 31: 303–307.
- Azorit C., Analla M., Hervás J. et al. 2004: Aging through growth marks in teeth of Spanish red deer (*Cervus elaphus hispanicus*). *Wildlife Soc. Bull.* 32: 702–710.
- Azorit C., Munoz-Cobo J. & Analla M. 2002a: Seasonal deposition of cementum in first lower molars from *Cervus elaphus hispanicus*. *Mamm. Biol.* 67: 1–3.
- Cable R.M. 1958: An illustrated laboral of parasitology, 4th ed. Burgess Minneapolis, Minnesota.
- Chapple R.S. 1989: The biology and behaviour of chital deer (*Axis axis*) in captivity. PhD Thesis, Department of Animal Health, University of Sydney, N.S.W., Australia.
- Craighead J.J., Craighead F.C. & McCutchen H.E. 1970: Age determination of grizzly bears from fourth premolar tooth sections. *J. Wildlife Manage.* 34: 353–363.
- Culling C.E.A. 1957: Handbook of histopathological technique. Butterworth and Co., London.
- Erickson J.A.A. & Seliger W.G. 1969: Efficient sectioning of incisors for estimating ages of mule deer. *J. Wildlife Manage.* 33: 384–388.
- Evans K., Kemper C., McKenzie J. et al. 2007: Age determination of marine mammals using tooth structure. *South Australian Museum, North Terrace, Adelaide.*
- Goodwin E.A. & Ballard W.B. 1985: Use of tooth cementum for age determination of gray wolves. *J. Wildlife Manage.* 49: 313–316.
- Grue H. & Jensen B. 1979: Review of the formation of incremental lines in tooth cementum of terrestrial mammals. *Dan. Rev. Game Biol.* 11: 1–48.
- Gupta P., Kaur H., Shankari G.S. et al. 2014: Human age estimation from tooth cementum and dentine. *J. Clin. Diagn. Res.* 8: ZC07–ZC10.
- Hamlin K., Pac D.F. & Sime C.A. et al. 2000: Evaluating the accuracy of ages obtained by two methods for Montana ungulates. *J. Wildlife Manage.* 64: 441–449.
- Hausmann M.F. & Vleck C.M. 2002: Telomere length provides a new technique for aging animals. *Oecologia* 130: 325–328.
- Johnston D.H., Joachim D.G., Bachmann P. et al. 1987: Aging furbearers using tooth structure and biomarkers. In: Novak M., Baker J.A., Obbard M.E. & Malloch B. (eds.), Wild furbearer management and conservation in North America. *Ontario Ministry of Natural Resources, Toronto, Ontario*: 228–243.
- Klevezal G.A. & Kleinenberg S.E. 1967: Age determination of mammals from annual layers in teeth and bones. *Severtsov Institute of Animal Morphology, Academy of Science of the USSR, Moscow. (in Russian)*
- Low W.A. & Cowan I.McT. 1963: Age determination of deer by annular structure of dental cementum. *J. Wildlife Manage.* 27: 466–471.
- Marks S.A. & Erickson P.W. 1966: Age determination in black bear. *J. Wildlife Manage.* 30: 389–410.
- Matson G., Daele L.V., Goodwin E. et al. 1993: A laboratory manual for cementum age determination of Alaskan brown bear first premolar teeth. *Matson's Laboratory, Milltown, Montana.*
- Mbizah M.M., Steenkamp G. & Groom R.J. 2016: Evaluation of the applicability of different age determination methods for estimating age of the endangered African wild dog (*Lycaon Pictus*). *PLOS ONE* 11: e0164676.
- Miller F.L. 1974: Age determination of caribou by annulations in dental cementum. *J. Wildlife Manage.* 38: 47–53.
- Mitchell B. 1963: Determination of age in Scottish red deer from growth layers in dental cement. *Nature* 198: 350–351.

- Mitchell B. 1967: Growth layers in dental cement for determining the age of red deer (*Cervus elaphus*). *J. Anim. Ecol.* 36: 279–293.
- Mundy K.R.D. & Fuller W.A. 1964: Age determination in grizzly bear. *J. Wildlife Manage.* 28: 863–866.
- Neste D.V. 2004: Thickness, medullation and growth rate of female scalp hair are subject to significant variation according to pigmentation and scalp location during ageing. *Eur. J. Dermatol.* 14: 28–32.
- Roulichová J. & Anděra M. 2007: Simple method of age determination in red fox, *Vulpes vulpes*. *Folia Zool.* 56: 440–444.
- Sergeant D.E. & Pimlott D.H. 1959: Age determination in moose from sectioned incisor teeth. *J. Wildlife Manage.* 23: 315–321.
- Simon D.E. & Frydendall M.J. 1981: Age study of Minnesota red fox using cementum annulae counts and tooth x-rays. *JMAS* 46: 2–5.
- Stander P.E. 1997: Field age determination of leopards by tooth wear. *Afr. J. Ecol.* 35: 156–161.
- Stoddart D.M. 1974: Age determination of roe deer (*Capreolus capreolus*) from annual growth layers in the dental cementum. *J. Zool. Lond.* 174: 511–537.
- Willey C.H. 1974: Aging black bears from first premolar tooth sections. *J. Wildlife Manage.* 38: 97–100.
- Zapata S.C., Travaini A. & Delibes M. 1995: Comparacion entre varias tecnicas de estimacion de la edad en zorros, *Vulpes vulpes*, de Doñana (sur de la peninsula iberica). *Doñana Acta Vertebrata* 22: 29–50.