



## **MORPHOLOGY OF THE LARVAL STAGES OF *Elaeophora schneideri* IN THE INTERMEDIATE AND DEFINITIVE HOSTS WITH SOME OBSERVATIONS ON THEIR PATHOGENESIS IN ABNORMAL DEFINITIVE HOSTS \***

Authors: HIBLER, CHARLES P., and METZGER, CAROL J.

Source: Journal of Wildlife Diseases, 10(4) : 361-369

Published By: Wildlife Disease Association

URL: <https://doi.org/10.7589/0090-3558-10.4.361>

---

BioOne Complete ([complete.BioOne.org](https://complete.BioOne.org)) is a full-text database of 200 subscribed and open-access titles in the biological, ecological, and environmental sciences published by nonprofit societies, associations, museums, institutions, and presses.

Your use of this PDF, the BioOne Complete website, and all posted and associated content indicates your acceptance of BioOne's Terms of Use, available at [www.bioone.org/terms-of-use](https://www.bioone.org/terms-of-use).

Usage of BioOne Complete content is strictly limited to personal, educational, and non - commercial use. Commercial inquiries or rights and permissions requests should be directed to the individual publisher as copyright holder.

---

BioOne sees sustainable scholarly publishing as an inherently collaborative enterprise connecting authors, nonprofit publishers, academic institutions, research libraries, and research funders in the common goal of maximizing access to critical research.

## MORPHOLOGY OF THE LARVAL STAGES OF *Elaeophora schneideri* IN THE INTERMEDIATE AND DEFINITIVE HOSTS WITH SOME OBSERVATIONS ON THEIR PATHOGENESIS IN ABNORMAL DEFINITIVE HOSTS\*

CHARLES P. HIBLER and CAROL J. METZGER, Wild Animal Disease Center  
Colorado State University, Fort Collins, 80521, USA.

**Abstract:** Morphology of the larval stages of *Elaeophora schneideri* from the horse fly and the normal definitive host (*Odocoileus hemionus*) are described. Development of larvae in the horsefly begins in the fat bodies, but larvae enter the haemocoel early in the first-stage of development and remain in the haemocoel until they are third-stage (infective) and then migrate to the head and mouth parts. Infective larvae in the definitive host begin development in the leptomeningeal arteries and are immature adults in 2 weeks. At 3.5-4 weeks they migrate into the carotid arteries and grow to sexual maturity about 4.5 months later. In abnormal definitive hosts (*Cervus canadensis* or *Ovis aries*) larvae remain in the leptomeningeal arteries for 5 weeks or longer initiating the clinical manifestations of elaeophorosis.

### INTRODUCTION

When horse flies were incriminated as intermediate hosts of *Elaeophora schneideri* Wehr and Dikmans, 1935, larval collections were initiated to describe the morphology of developmental stages in the arthropod. Concurrently, experimental infections were initiated to study and describe the pathogenesis and pathology of the disease in elk calves, mule deer and domestic sheep.<sup>1-6</sup> In most of these experiments, additional animals were included to determine how infective larvae reached the circulatory system, when they arrived in the cephalic arterial system, the length of time required for growth and development in the definitive host, where growth and development occurred, the time and stage of development when they returned to the carotid arteries, and to acquire specimens for morphologic description of development.

### MATERIALS AND METHODS

Larval *E. schneideri* dissected from horse flies were preserved in 10% formalin, alcohol-formalin-acetic acid, or 70% ethanol with 5% glycerin added (v/v). They were cleared for study with glycerin or lacto-phenol. Illustrations were made with the aid of a camera-lucida.

Larval and immature adult *E. schneideri* were collected from a number of experimentally infected domestic sheep, mule deer and elk calves. Some of these animals were examined at 12, 24, 48 and 72 hours post-infection; others were examined from 1 to 5 weeks post-infection.

Previous experience with postmortem examinations of animals naturally infected with larval *E. schneideri* indicates that the parasites concentrate primarily in the cephalic arterial system.<sup>1</sup> Blood obtained from the carotid arteries and jugular vein was hemolyzed using a solution containing 2% saponin and 2%

\* This research was supported by the New Mexico Department of Game and Fish and NIH Grant 6 ROI EY00474-06.

sodium citrate. Four volumes of this solution were added to one volume of blood. After hemolysis occurred, the solution was allowed to stand overnight, decanted, and the sediment examined for parasites. The maceration technique was employed for the examination of tissues in the head region. Finely chopped tissues were soaked in physiological saline for at least 6 hours, the tissues strained off, and the liquid examined for parasites. Tissues examined using this technique were: facial skin, especially about the site of inoculation; ears; muzzle; tongue; and all lymph nodes in the head region. Meninges were stripped from the brain and these, as well as the anterior pituitary gland (with the cerebral retia attached) were examined similarly, but after soaking for 6 hours they were then digested using the pepsin-hydrochloric acid technique. This was done in an effort to obtain a more accurate record of the number of larvae in these blood vessels. Eyes were removed, preserved in 10% formalin and examined histologically for parasites. The entire skull was cut into 4-8 pieces and soaked in physiological saline. Parasites collected from these tissues were preserved and cleared for study in the same manner as those from horse flies.

## RESULTS

Over the last 5 years, numerous larvae of *E. schneideri* have been collected from naturally infected species of *Tabanus* and *Hybomitra*, but the majority came from *Hybomitra laticornis* (Hine), the predominant species in the Gila Forest, New Mexico.<sup>3</sup> Since these larval stages came from naturally infected horse flies, no information is available on the time required for development of the microfilaria to the third-stage (infective) larva ( $L_3$ ). Moreover, and despite the large numbers of larvae examined, none were found in the act of molting; therefore, any statements about "first" ( $L_1$ ) or "second" ( $L_2$ ) stages must be considered somewhat subjective.

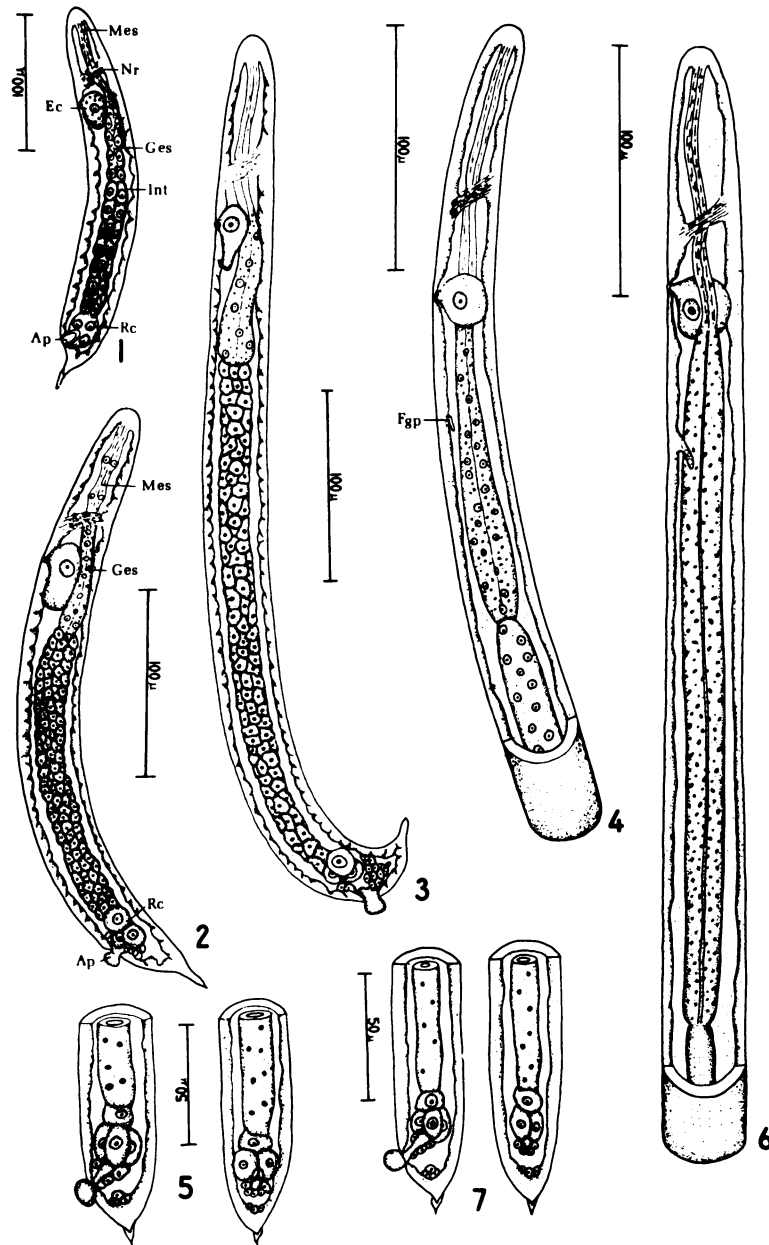
## Development in the intermediate host

The earliest developmental stages in the horse fly were found in the fat bodies lining the abdomen. Larval stages found here had already developed into an  $L_1$  and the representative larva illustrated (Fig. 1) was 240  $\mu\text{m}$  long and 36  $\mu\text{m}$  in diameter. The muscular esophagus, glandular esophagus and intestine were all recognizable. Only three rectal cells were evident in most larvae at this stage in growth, but in some later larvae four cells could be recognized. As in all filarioid larvae, an anal plug of cuticle sealed the rectum.

The larva grows and develops within the fat bodies until it reaches a length of 350-400  $\mu\text{m}$  and a width of 35-40  $\mu\text{m}$ . It then leaves the fat bodies and all subsequent development occurs in the haemocoel. The larva illustrated in figure 2 differs significantly from the larva in figure 1, in that the glandular esophagus, muscular esophagus and intestine are much more distinct. In most specimens the anal plug protruded. As with the previous larva, only three rectal cells were evident.

Subsequent growth and development of an  $L_1$  in the haemocoel is manifest primarily by an increase in length. The larva illustrated in figure 3 is 525  $\mu\text{m}$  long and 40  $\mu\text{m}$  in diameter, but internal development is not appreciably different from the larva in figure 2. This larva is presumed to be an  $L_1$  as yet, but shortly thereafter some significant changes occur internally, suggesting that a molt from  $L_1$  to  $L_2$  has occurred.

Growth and development of a larva presumed to be an  $L_2$  is marked by many significant changes. Intestinal cells lose their distinct boundaries and become syncytial-like in appearance (fig. 4). When this occurs a fourth rectal cell can be clearly seen between the three rectal cells observed earlier and the intestine (fig. 5). Of more importance, the early female genital primordium can be seen in well-preserved specimens (fig. 4). In a few specimens, the early male genital primordium could be distinguished (fig. 10). The larva illustrated in figures 4 and



FIGURES 1-7. *Elaeophora schneideri*. 1. L<sub>1</sub> from fat bodies. 2. L<sub>1</sub> from haemocoel. 3. Late L<sub>1</sub>. 4. Anterior extremity of early L<sub>2</sub>. 5. Posterior extremity of early L<sub>2</sub>. 6. Anterior extremity of late L<sub>2</sub>. 7. Posterior extremity of late L<sub>2</sub>. Abbreviations: Ap, anal plug; Ec, excretory cell; Fgp, female genital primordium; Ges, glandular esophagus; Int, intestine; Mes, muscular esophagus; Nr, nerve ring; Rc, rectal cell.

5, and presumed to be an early  $L_2$ , measured 1.75 by 0.048 mm.

Further growth and development of the  $L_2$  is manifest primarily by a marked increase in the length of the glandular esophagus. There is also some growth of the female genital primordium, but no marked changes are evident in the male genital primordium. The larva illustrated in figures 6 and 7 is considered to be a mature  $L_2$  and measured 3.75 by 0.058 mm.

The  $L_2$  molts to an  $L_3$  while in the haemocoel and after a period of growth and further maturation the  $L_3$  migrates into the head and mouthparts. An  $L_3$  is easily recognizable because the anal plug is lost. Pertinent measurements for the infective  $L_3$  are given in Table 1.

The anterior and posterior extremity of a typical female infective  $L_3$  is illustrated in figures 8 and 9. The male and female genital primordia are illustrated in figures 11 and 12. The infective  $L_3$  has two characteristic morphologic features for identification. The first and most important are the three protuberances on the caudal extremity (fig. 9).

Adult *E. schneideri* also have these protuberances. The second is the cephalic papillae (fig. 13).  $L_3$  have the same number and arrangement of papillae as an adult.<sup>6</sup>

#### Development in the definitive host

Observations on development within the definitive hosts must be considered somewhat subjective because of the limited number of animals available for experimental infections, postmortem migration of parasites, and possible aberrant migration or development of parasites in abnormal definitive hosts.

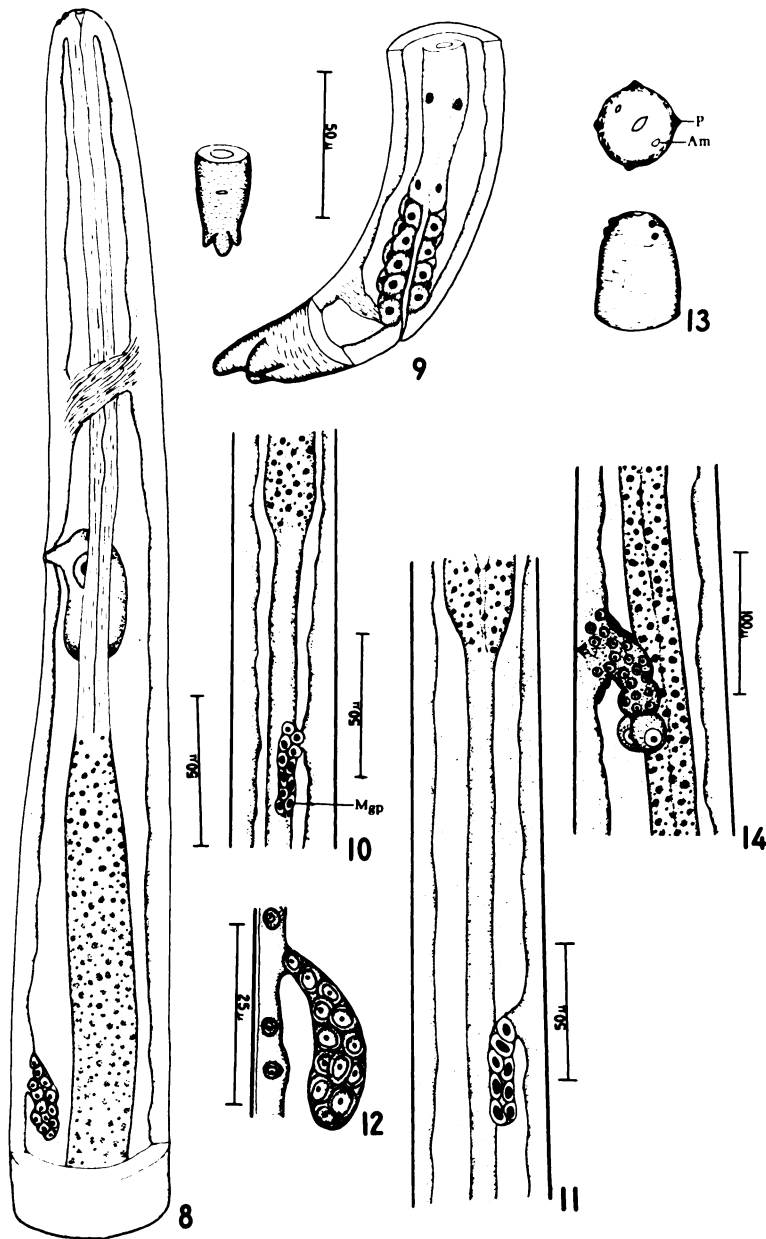
Data obtained from mule deer and domestic sheep indicate that infective larvae remain in the dermis for 6 to 12 hours and then are carried to the heart, presumably by way of the venous circulation, where they make the usual circuit through the lungs and enter the arterial circulation. By some means presently unknown most of the larvae enter the common carotid arteries and are distributed in the cephalic arterial system. The

TABLE 1. Measurements of third-stage (infective) larvae of *Elaeophora schneideri* from horseflies. All values are given in microns. The average is given first, the range is in parenthesis.

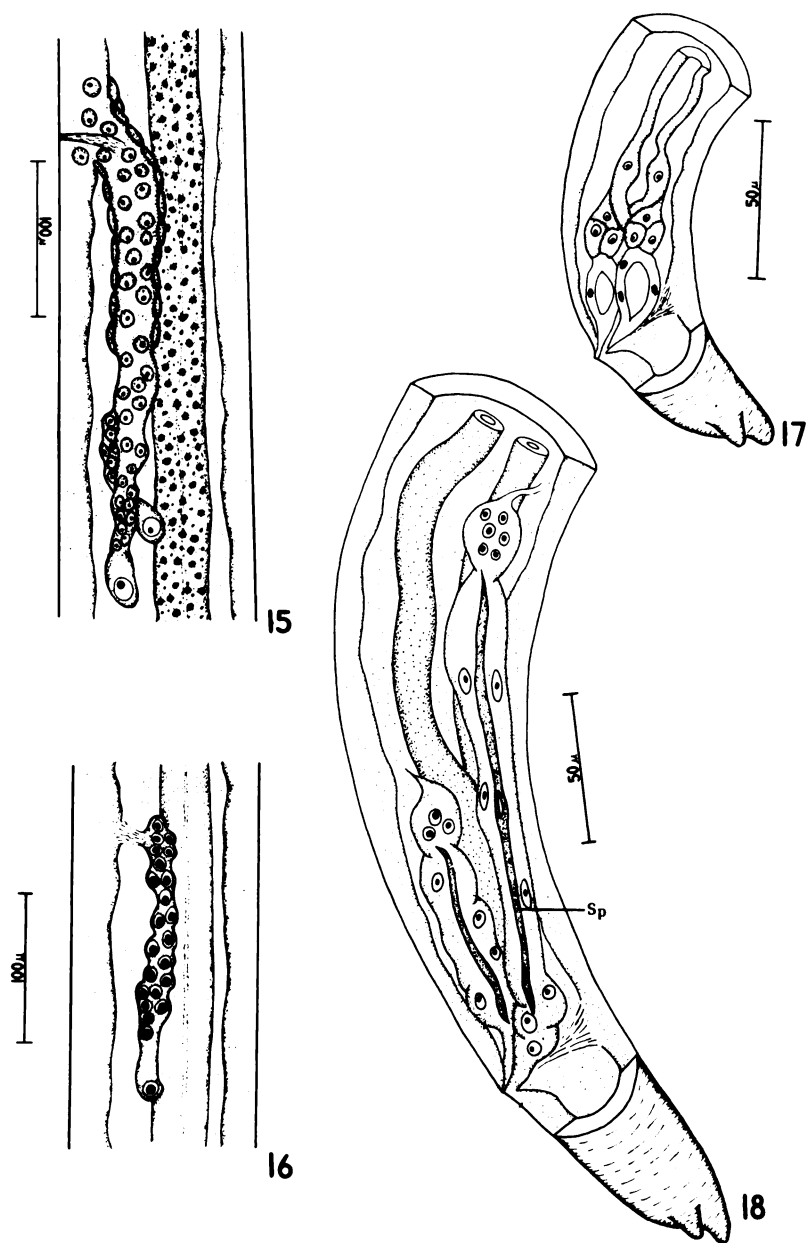
	Male	Female
Length	4446 (3296-5032)	4451 (3848-5032)
Width	44.7 (36.7-55)	49.6 (40-56.9)
Nerve Ring*	125 (110-128.5)	122 (110-128.5)
Esophagus		
Muscular length	273.6 (220-313)	270.8 (238.6-293.6)
Muscular width	21.4 (18.4-25.7)	22.5 (18.4-31)
Glandular length	1943.4 (1407.8-2146)	1902.7 (1645-2092.8)
Glandular width	21.4 (18.4-23.9)	22.5 (18.4-23.9)
Excretory Pore*	197.6 (179.8-201.9)	195.3 (165.2-201.9)
Genital Primordium*	2285 (1924-2516)	323.4 (293.6-348.7)
Anus**	55.6 (51.4-62.4)	54 (47.7-62.4)

\* Measurements from Anterior end of body

\*\* Measurements from Posterior end of body



FIGURES 8-14. *Elaeophora schneideri*. 8. Anterior extremity of infective L<sub>3</sub>. 9. Posterior extremity of infective L<sub>3</sub>. 10. Male genital primordium in L<sub>2</sub>. 11. Male genital primordium in L<sub>3</sub>. 12. Female genital primordium in L<sub>3</sub>. 13. En face view and ventro-lateral view of L<sub>3</sub>. 14. Female genital primordium in late L<sub>3</sub>. Abbreviations: Am, amphid; Mgp, male genital primordium; P, papilla.



FIGURES 15-18. *Elaeophora schneideri*. 15. Early L<sub>4</sub> female reproductive system. 16. Early L<sub>4</sub> male reproductive system. 17. L<sub>4</sub> spicule development. 18. Early L<sub>5</sub> spicule development. Abbreviation: Sp, spicule.

great majority then enter cerebral arteries, but some have been recovered from branch arteries throughout the entire cephalic arterial system; here they commence development from the infective stage to an adult.

As in the horse fly, no molts were observed in developmental stages collected from the definitive hosts. When the infective larva is introduced it measures an average of 4.45 by 0.048 mm. Subsequent growth is manifest by a rapid increase in length and development of the reproductive system. Development of the female reproductive system apparently begins as soon as larvae are introduced (figs. 14 and 15), but no significant changes are observed in males for about 1 week, when the primordium begins to grow (fig. 16) and the spicules begin to develop (figs. 17 and 18).

Development from the infective stage to the immature adult requires 14 days. Immature adult females are easily recognizable because they have lost the cuticular lining to the vagina; males introduced at the same time are assumed to be adults if the spicules are completely developed. Females are 11 to 13 mm long and 0.13 to 0.15 in diameter. Males are 10 to 13 mm long and 0.11 to 0.14 in diameter. Both sexes are minute replicas of the mature parasite, internally and externally. Since the adult has been described, the reader is referred to that information.<sup>6</sup>

In mule deer, the parasite apparently migrates into the larger arteries as it develops from the infective larva to an adult. Infective larvae occur in leptomeningeal arteries, but immature adults are usually found in cerebral arteries. In this host, immature adults migrate into the internal maxillary and common carotid arteries at 3.5 to 4 weeks. The parasites measure 18 to 20 mm in length and 0.15 to 0.18 mm in diameter when they return to the carotid arteries. In elk and sheep, however, developing parasites frequently occupy the smaller branch arteries supplying the brain for 5 weeks or longer and reach a length of 30 to 40 mm. Death of these hosts is often caused by rupture of cerebral retial arteries when the parasite attempts to cross this meshwork and enter the carotid arteries.

In mule deer *E. schneideri* become sexually mature and begin producing microfilariae as early as mid-November, making the pre-patent period 5.5 months; however, microfilariae are difficult to demonstrate by biopsy before mid-December or early January.

#### DISCUSSION

A number of studies have been published on the development of filarioid nematodes in their intermediate hosts,<sup>2,5,11</sup> and a few are available on development in the definitive host.<sup>4,10</sup> The intent of this article was to provide information on the morphology, site of development and time required for development as an aid in identification of *E. schneideri* rather than enter into an exhaustive discussion on comparative morphology of filarioid nematodes. If the reader is interested, the articles referenced should be consulted.

The most important stages for identification of *E. schneideri* are the L<sub>3</sub> from either intermediate or definitive hosts, and immature adults from the definitive hosts. L<sub>3</sub> have the three protuberances on the caudal extremity while the immature adults are minute replicas of the sexually mature specimens.

The mule deer is considered to be the normal definitive host for *E. schneideri* while domestic sheep, elk, and moose are considered to be abnormal definitive hosts.<sup>1,8,9,12</sup> Consequently, our observations on development within the definitive host were based on the behavior of *E. schneideri* in the mule deer. As pointed out earlier, a limited number of animals were available and some caution must be exercised in interpretation. A comparison of the behaviour of *E. schneideri* in mule deer with domestic sheep and elk calves reveals that in mule deer the larval stages migrate into larger arteries as they grow, while in domestic sheep and elk they remain in the smaller arteries for a longer period of time, effectively inhibiting flow of blood. In an abnormal host this is the first critical period after infection with *E. schneideri* and clinical signs of blindness, deafness and circling



develop in 7 to 14 days. Animals frequently become comatose and die within 24 hours after signs of elaeophorosis develop.

The second critical period after infection of an elk or a sheep is when the immature adults traverse the cerebral retia to take up residence in the common carotid or internal maxillary arteries. In the mule deer, immature adults traverse the cerebral retia at 3.5 to 4 weeks post-infection, while in sheep and elk passage is delayed by at least a week and often longer. The parasite grows considerably during this time and a frequent consequence is rupture of a cerebral rete artery, resulting in sudden death from cerebral hemorrhage.

On occasion sheep and elk have died 7 to 8 weeks post-infection, a time interval sufficient for all parasites to be in the carotid arteries. At postmortem examination the findings invariably are thrombosis of cerebral arteries with at least one parasite proximal to the thrombus. Our interpretation, based on the absence of any organization of the thrombus, is that these parasites have entered the carotid arteries and then returned to the cerebral arteries a week or two later.

If an elk calf or yearling survives these first two critical periods, the third critical period is during the interval when parasites are growing in the carotid arteries. They are 30 to 40 mm in length when they arrive, and over the next 5 months develop to sexually mature adults. If considerable numbers are present in elk, and this is not unusual, growth mechanically interferes with blood flow; moreover, thrombosis develops and the lumina of the carotid arteries become almost obliterated by intimal proliferation and subsequent fibrosis.<sup>1</sup> This type of re-

sponse is seldom seen in mule deer or domestic sheep and when it does occur the response is minimal. Additionally, elk apparently have no resistance to excessive numbers of *E. schneideri*, which undoubtedly compounds this problem.

If elk survive these critical periods, the parasites die about the time they become sexually mature, but some may live long enough to produce microfilariae for a short period of time. Present evidence from three experimentally infected animals and over 150 hunter-killed animals indicates that if elk survive the initial infection they develop an immunity to reinfection.

In elk, developmental stages of *E. schneideri* have been found in nearly every artery large enough to accommodate them if infections with 50 or more occur, but the great majority enter branches of the cephalic arterial system. Undoubtedly, even in light infections, many arteries other than the cephalic arterial system are occupied but with fewer numbers the parasites are difficult to find. With a few exceptions, developmental stages of *E. schneideri* recovered from domestic sheep and mule deer have been found in the leptomeningeal arteries. As with elk, they no doubt occur elsewhere because it is not unusual to find domestic sheep with digital arteries occupied by adult parasites. On one occasion, considerable numbers of adults were recovered from the femoral arteries of a naturally infected mule deer; moreover, some of the 87 parasites found in an experimentally infected deer may have migrated to such sites as the brachial arteries following death; but they could also have developed in the branches of these arteries and established in the brachial arteries as adults.<sup>8</sup>

#### Acknowledgements

The authors wish to express their appreciation to G. H. Gates and B. R. Donaldson of the New Mexico Department of Game and Fish for their cooperation and support.

#### LITERATURE CITED

1. ADCOCK, J. L. and C. P. HIBLER. 1969. Vascular and neuro-ophthalmic pathology of elaeophorosis in elk. Path. Vet. 6: 185-213.

2. ANDERSON, R. C. 1956. The life cycle and seasonal transmission of *Ornithofilaria fallisensis* Anderson, a parasite of domestic and wild ducks. Can. J. Zool. 34: 485-525.
3. CLARK, G. G. and C. P. HIBLER. 1973. Horse flies and *Elaeophora schneideri* in the Gila Forest, New Mexico. J. Wildl. Dis. 9: 21-25.
4. CROSS, J. B. and J. A. SCOTT. 1947. The developmental anatomy of the fourth stage and adults of *Litosomoides carinii*, a filarial worm of the cotton rat. Trans. Am. Micr. Soc. 66: 1-21.
5. HIBLER, C. P. 1963. Onchocercidae (Nematoda; Filarioidea) of the American magpie *Pica pica hudsonia* (Sabine), in northern Colorado. Dissertation, Colorado State University. 189 pp.
6. HIBLER, C. P. and J. L. ADCOCK. 1968. Redescription of *Elaeophora schneideri* Wehr and Dikmans, 1935 (Nematoda:Filarioidea). J. Parasitol. 54: 1095-1098.
7. ———, ———, R. W. DAVIS and Y. Z. ABDELBAKI. 1969. Elaeophorosis in deer and elk in the Gila Forest, New Mexico. J. Wildl. Dis. 5: 27-30.
8. ———, ———, G. H. GATES and R. WHITE. 1970. Experimental infection of domestic sheep and mule deer with *Elaeophora schneideri* Wehr and Dikmans, 1935. J. Wildl. Dis. 6: 110-111.
9. ———, G. H. GATES and B. R. DONALDSON. 1974. Experimental infection of immature mule deer (*Odocoileus hemionus*) with *Elaeophora schneideri*. J. Wildl. Dis. 10: 44-46.
10. ORIHEL, T. C. 1961. Morphology of the larval stages of *Dirofilaria immitis* in the dog. J. Parasitol. 47: 251-262.
11. TAYLOR, A. E. R. 1960. The development of *Dirofilaria immitis* in the mosquito *Aedes aegypti*. J. Helminthol. 34: 27-38.
12. WORLEY, D. E., C. K. ANDERSON and K. R. GREER. 1972. Elaeophorosis in moose from Montana. J. Wildl. Dis. 8: 242-244.

Received for publication 7 February 1974