



Paragonimus kellicotti INFECTION IN WILD CARNIVORES IN SOUTHWESTERN ONTARIO: I. PREVALENCE AND GROSS PATHOLOGIC FEATURES *

Authors: RAMSDEN, ROBERT O., and PRESIDENTE, PAUL J. A.

Source: Journal of Wildlife Diseases, 11(1) : 136-141

Published By: Wildlife Disease Association

URL: <https://doi.org/10.7589/0090-3558-11.1.136>

BioOne Complete (complete.BioOne.org) is a full-text database of 200 subscribed and open-access titles in the biological, ecological, and environmental sciences published by nonprofit societies, associations, museums, institutions, and presses.

Your use of this PDF, the BioOne Complete website, and all posted and associated content indicates your acceptance of BioOne's Terms of Use, available at www.bioone.org/terms-of-use.

Usage of BioOne Complete content is strictly limited to personal, educational, and non - commercial use. Commercial inquiries or rights and permissions requests should be directed to the individual publisher as copyright holder.

BioOne sees sustainable scholarly publishing as an inherently collaborative enterprise connecting authors, nonprofit publishers, academic institutions, research libraries, and research funders in the common goal of maximizing access to critical research.

Paragonimus kellicotti* INFECTION IN WILD CARNIVORES IN SOUTHWESTERN ONTARIO: I. PREVALENCE AND GROSS PATHOLOGIC FEATURES

ROBERT O. RAMSDEN and PAUL J. A. PRESIDENTE

Abstract: *Paragonimus kellicotti* Ward, 1908 was recovered from 16 of 105 mink (*Mustela vison*), 14 of 244 striped skunks (*Mephitis mephitis*), 10 of 446 red foxes (*Vulpes vulpes*), 1 of 31 coyotes (*Canis latrans*), 0 of 326 raccoons (*Procyon lotor*) and 0 of 8 weasels (*Mustela* spp.) collected from southwestern Ontario. The majority of carnivores harboring *P. kellicotti* was collected from two counties (Huron and Bruce) bordering the east shore of Lake Huron where 6.0% of the animals (excluding raccoons) were infected. There were extensive adhesions between the lungs and parietal pleura and dorsal mediastinal pleura in 25 of 301 raccoons collected from these two counties. This lesion was thought to be associated with a reaction to migrating *P. kellicotti*.

This is the first time *P. kellicotti* has been reported in the striped skunk and red fox from Ontario and apparently the first record of this parasite in the coyote.

INTRODUCTION

Distribution of the lung fluke *Paragonimus kellicotti* Ward, 1908 in North America is apparently restricted to the area inhabited by its first intermediate host, *Pomatiopsis lapidaria*. This amphibious snail is found in southeastern and midwestern regions of the United States and southern Ontario in Canada.¹⁰ Crayfishes (principally *Cambarus* spp.) are the second intermediate host and specimens harboring metacercariae have been collected from many sites within these areas.¹⁰ Among wild mammal populations mature *P. kellicotti* has been reported from mink,^{1,4,5,9-11,18,21,23,27,28} red foxes,^{8,25} bobcats (*Lynx rufus*),^{15,20,24} muskrats (*Ondatra zibethicus*),^{3,4,13} opossums (*Didelphis virginianus*),^{7,20} striped skunks^{6,20}

and raccoons.^{12,20} In Ontario *P. kellicotti* has been found in the muskrat,¹³ ranch-reared foxes^{16,17} and mink.¹⁸

MATERIALS AND METHODS

From 1972 to 1974 a total of 1,157 wild carnivores were submitted for necropsy to the Wildlife Diseases Section of the Ontario Veterinary College. One hundred and five mink, 244 striped skunks, 446 red foxes, 31 coyotes, 8 weasels and 323 raccoons were examined (Table 1). Carcasses were obtained from fall- and winter-trapped animals and road-killed or sick animals. At the time of submission many of these carcasses were autolyzed or frozen. The number of nodules containing *P. kellicotti* was re-

*Joint contribution from the Fish and Wildlife Branch, Ontario Ministry of Natural Resources, Maple, Ontario, Canada (Ramsden) and the Department of Pathology, Ontario Veterinary College, University of Guelph, Guelph, Ontario (Presidente).

Supported by the Fish and Wildlife Research Branch, Wildlife Section of the Ontario Ministry of Natural Resources (Ramsden), and the National Research Council of Canada and Ontario Ministry of Agriculture and Food (Presidente).

† Addison, E. M. 1974. Pers. comm. *Paragonimus kellicotti* was found in a muskrat from the Lake Erie area and reported in the Annual Project Report of the Research Branch of the Ontario Department of Lands and Forests, 1969.

TABLE 1. Prevalence of *Paragonimus kellicotti* Infection in 834 Wild Carnivores (Five Species) and of Pleural Adhesions in 323 Raccoons Collected in Southwestern Ontario, 1972-1974.

Species of Carnivore		Number examined	Number positive	Percentage positive
Lung flukes recovered				
Mink	<i>Mustela vison</i>	105	16	15.2
Striped skunk	<i>Mephitis mephitis</i>	244	14	5.7
Red fox	<i>Vulpes vulpes</i>	446	10	2.2
Coyote	<i>Canis latrans</i>	31	1	3.2
Weasel	<i>Mustela</i> spp.	8	0	0.0
TOTALS		834	41	4.9
Pleural Adhesions				
Raccoon	<i>Procyon lotor</i>	323	26	8.0

corded, but flukes were recovered from only a small number of the carnivores. Tissues from various organs were fixed in 10% buffered formalin, paraffin-embedded, sectioned and stained in hematoxylin and eosin (H&E) for histopathologic examination. Lung tissue from several raccoons was cultured by routine methods for isolation of pathogenic bacteria or mycoplasma.

Carcasses from the mink, striped skunks, red foxes, coyotes and weasels were obtained from ten counties in southwestern Ontario: Kent, Lambton, Huron, Bruce, Grey, Waterloo, Wellington, Simcoe and York (Fig. 1). In addition, 323 raccoons were collected from five of these counties (Huron, Bruce, Grey, Waterloo and Wellington) (Fig. 2).

RESULTS

The prevalence of *P. kellicotti* infection in mink, striped skunk, red fox, coyote and weasel is given (Table 1) and geographic location of total positive cases shown (Fig. 2). The majority of carcasses (563) was obtained from the two counties (Huron and Bruce) bor-

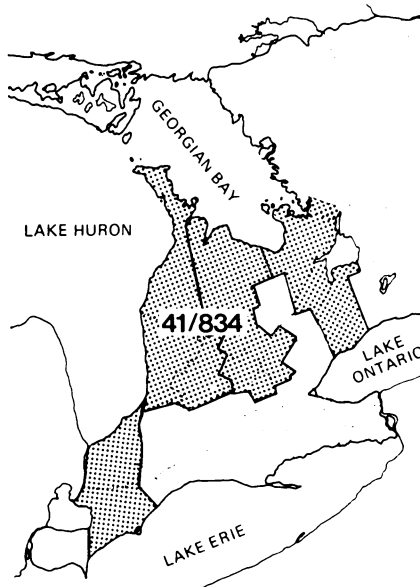


FIGURE 1. Prevalence of *Paragonimus kellicotti* in five species of wild carnivore collected from Southwestern Ontario, 1972-1974. Numerator = number infected; denominator = number examined.

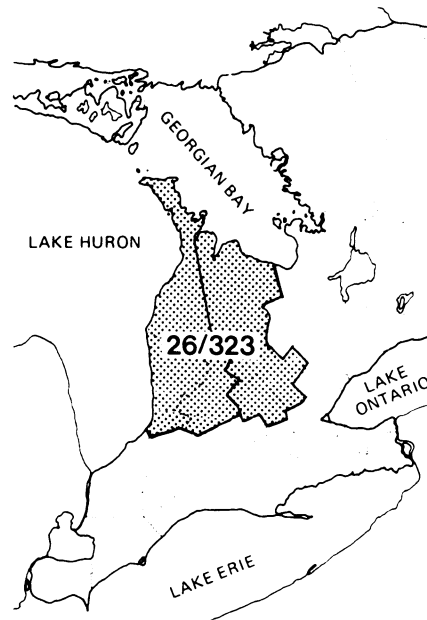


FIGURE 2. Prevalence of pleural adhesions that may be associated with *Paragonimus kellicotti* infection in raccoons collected from Southwestern Ontario, 1973-1974. Numerator = number affected; denominator = number examined.

dering the east shore of Lake Huron and in this area the greatest number of infected carnivores (34; 6.0%) was found. Eleven of 33 mink (33.3%), 13 of 180 skunks (7.2%), 9 of 323 red foxes (2.8%) and 1 of 22 coyotes (4.5%) harbored *P. kellicotti*.

Gross Pathologic Features of *Paragonimus kellicotti* Infection

Of the 32 infected carnivores from which the number of nodules containing *P. kellicotti* was recorded, 14 had 'several', 11 had single nodules, and seven animals had two nodules in the lungs. A difference in the proportions of infected animals in these categories was not evident when each species of carnivore was separately considered. The single infected coyote had several nodules.

Mink

The nodules containing *P. kellicotti* were spherical, 1-1½ cm in diameter and firm on palpation. The pulmonary pleura overlying the nodules was smooth and translucent. Their color varied from a deep red to a dark brown, depending on the stage of infection. Nodules were seen in all lobes of the lungs and when cut open, a clear gelatinous mass exuded from the cavity; two flukes were commonly recovered from each. Hard nodules within the pulmonary parenchyma were found in one mink.

Skunk

The nodules were similar in size and shape to those seen in mink. They were elevated above the surface of the lung and the overlying pulmonary pleura was normal. Flukes were up to 15 mm in length and four *P. kellicotti* were recovered from one nodule. In two skunks, large cysts 2-3 cm in diameter, were found on the liver and these contained mature flukes. In association with these lesions there were adhesions of the liver to the diaphragm and between liver lobes.

Red fox

The nodules were 1½-2 cm in diameter, dark red and hemorrhagic. The overlying pleura was rough and covered with fibrinous exudate. Two or three flukes were recovered from each nodule. In all infected foxes, a large quantity of dark brown flocculent fluid was found in the thoracic cavity. In most animals there was a fibrinous inflammatory reaction of the pulmonary and parietal pleura. This lesion was usually unilateral, but one side was not more frequently involved than the other. In the region of the nodules loose fibrinous attachments to the thoracic wall were occasionally seen. In one fox, nodules were not seen but five immature *P. kellicotti*, 2-5 mm long, were found in the thoracic cavity.

Coyote

The nodules were thick-walled and hard on palpation but similar in shape

and color to those described in mink. Many of the nodules were located in the left diaphragmatic lobe where surrounding parenchyma was consolidated. The pleura overlying the nodules and the adjacent parenchyma was opaque and gray.

Weasel

The susceptibility of weasels to *P. kellicotti* was not established in this study because of the small sample size (Table 1). There were no lesions attributed to *P. kellicotti* noted.

Raccoon

Although *P. kellicotti* was not recovered from any of the 323 raccoons examined, adhesions of the pulmonary pleura to the parietal pleura were seen in 26 carcasses (Table 1; Fig. 2). Most of the raccoons (25 of 301) with pleural adhesions were collected in the counties of Huron and Bruce on the east shore of

Lake Huron. In the majority of raccoons, the dorso-anterior aspect of the lungs was involved, with adhesion to the dorsal mediastinal pleura. Adhesion of the apical to cardiac lobes was also seen (Fig. 3). In raccoons in which the lesion was more extensive, the cardiac lobe was adherent to the pericardial sac. The diaphragmatic lobes were adherent to the parietal pleura of the diaphragm in only a few animals. There was adhesion of the entire pulmonary pleura to adjacent pleural surfaces in one raccoon and hard white granulomas found between adherent pleural surfaces in another. Fluid was not seen in the thoracic cavity of any of these raccoons. Attempts to isolate pathogens from affected lungs and surrounding tissues in five animals with adhesions were negative.

DISCUSSION

The prevalence of *P. kellicotti* in mink (15%) in southwestern Ontario is similar to that reported from Michigan (9-17%),^{1,4,23} greater than that from Minnesota (2-8%)^{9,27} and North Carolina (2%),²¹ but much lower than was found in Ohio (35-44%).^{5,10} The gross appearance of the nodules in the lungs of mink was similar to that reported by others.^{4,11,18,27} The confined nature of this lesion in mink as well as the greater prevalence of infection in this host (compared with that found in the other carnivores examined), provides additional support for the conclusion that the mink is the normal definitive host.^{2,4,20,27}

Recovery of *P. kellicotti* from 5.7% of the striped skunks examined constitutes the first report for the lung fluke in this host in Ontario and only the third time it has been recorded in the striped skunk. It was previously found in 6 of 41 skunks (15%) examined from two areas in Georgia³⁰ and in a single animal from Minnesota.⁶ Although the flukes grow very large in striped skunks,²⁰ the histopathologic features of this infection²² suggest that this host is not well adapted to *P. kellicotti*. The host-parasite association may be poorly adapted because crayfish are not frequently eaten by striped skunks.⁶ Lesions on the liver as-

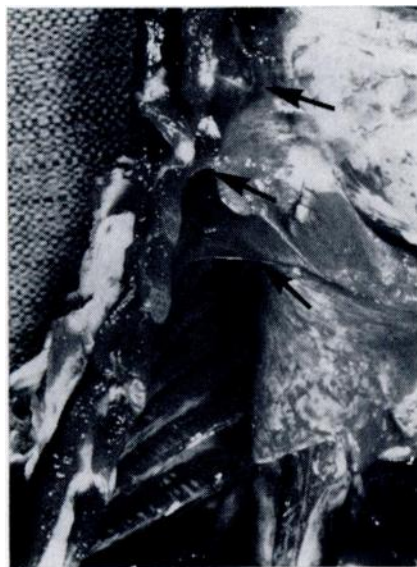

FIGURE 3. Adhesions between the anterior lobes of the right lung and the thoracic wall (arrows) of a raccoon thought to have been infected with *Paragonimus kellicotti*.

sociated with *P. kellicotti* in skunks have not been previously reported. However, Wallace²⁷ reported finding encapsulated lung flukes or egg masses in various places in the body cavity of mink.

Although *P. kellicotti* has been recorded in ranch-reared foxes in Ontario,^{16,17} this is the first time it has been reported in free-ranging red foxes in the province. The low prevalence is similar to that reported by Erickson⁶ in Minnesota, but less than was found recently in a small sample of foxes in Michigan.²⁵ Extensive fibrinous pleuritis and hemothorax as well as the severe pulmonary reaction seen on histologic examination²² indicate that *P. kellicotti* may be pathogenic to the red fox. These findings are in agreement with gross observations made on infected foxes by Stuht and Youatt²⁸ in Michigan.

Recovery of lung flukes from one coyote apparently constitutes the first record for *P. kellicotti* in this carnivore. This parasite has not been recovered from coyotes in a number of helminth surveys,^{8,14,26} although many of these were conducted outside the established enzootic area for *P. kellicotti*. The coyote was trapped on November 4, 1972 in Goderich Township near Clinton, Ontario. The strong fibrous reaction around *P. kellicotti*²² and low prevalence of infection suggest that the coyote is probably quite resistant to infection. Since crayfish are probably not frequently

eaten by coyotes, infection may have been acquired by ingesting rats or mink harboring migrating flukes.²

The absence of *P. kellicotti* in the 323 raccoons examined was consistent with the conclusion drawn by previous workers that the raccoon is a resistant host.^{1,2,4,20} The lung fluke has been found only in helminth surveys of raccoons in Georgia^{12,20} and North Carolina.²² However, the frequent finding of pleural adhesions in raccoons collected from the two counties (Huron and Bruce) where the highest prevalence of *P. kellicotti* was found in other hosts, as well as the absence of pathogenic bacteria or mycoplasma as etiologic agents suggested that the lesion was associated with lung fluke infection. The histopathologic features of the pulmonary reaction at the pleural surface²² provided additional evidence that the reaction was probably in response to migrating *P. kellicotti*. Ameel¹ reported that in a young raccoon fed *P. kellicotti* metacercariae there were adhesions of the lungs to the thoracic wall.

The small number of weasels examined during this investigation was not sufficient to form any conclusions regarding the susceptibility of this carnivore to *P. kellicotti* infection. However, Ameel¹ did not find lung flukes in 22 weasels he examined from Michigan and Erickson⁹ found none in 343 weasels (comprising three species) from Minnesota.

Acknowledgements

The authors wish to thank the Interministerial Rabies Committee of Ontario whose activities made this study possible, and trappers and personnel of the Ontario Ministry of Natural Resources for their co-operation in providing specimens and location data. We gratefully acknowledge the assistance of Messrs. Dave Johnston, Paul Coppin and Ian Watt, each of whom contributed substantially to this investigation.

LITERATURE CITED

1. AMEEL, D. J. 1931. More data on the lung fluke, *Paragonimus*, in North America. *Science* 74: 493-494.
2. AMEEL, D. J. 1932. Life history of the North American lung fluke of mammals. *J. Parasit.* 18: 264-268.
3. AMEEL, D. J. 1932. The muskrat, a new host for *Paragonimus*. *Science* 75: 382.
4. AMEEL, D. J. 1934. *Paragonimus*, its life history and distribution in North America and its taxonomy (Trematoda: Troglotrematidae). *Am. J. Hyg.* 19: 279-319.

5. BECKETT, J. V. and V. GALLICCHIO. 1966. Occurrence of the lung fluke, *Paragonimus kellicotti* Ward, 1908, in Ohio mink. J. Parasit. 52: 511.
6. BEMRICK, W. J. and J. C. SCHLOTTHAUER. 1971. *Paragonimus kellicotti* (Ward, 1908) in a Minnesota skunk. J. Wildl. Dis. 7: 36.
7. BYRD, E. E., R. J. REIBER and M. V. PARKER. 1941. The opossum, *Didelphis virginiana*, a new host for *Paragonimus westermanii* in the United States. J. Tenn. Acad. Sci. 16: 356-357.
8. ERICKSON, A. B. 1944. Helminths of Minnesota canidae in relation to food habits and a host list and key to species reported from North America. Am. Midl. Nat. 32: 358-372.
9. ERICKSON, A. B. 1946. Incidence of worm parasites in Minnesota Mustelidae and host lists and keys to North American species. Am. Midl. Nat. 36: 494-509.
10. GESINSKI, R. M., R. E. THOMAS and V. GALLICCHIO. 1964. Survey of *Paragonimus* in Ohio mink. J. Parasit. 50: 151.
11. GRAVES, E. F. 1937. *Paragonimus westermani* in mink. J. Am. vet. med. Ass. 90: 667-668.
12. HARKEMA, R. and G. C. MILLER. 1964. Helminth parasites of the raccoon, *Procyon lotor* in the southeastern United States. J. Parasit. 50: 60-66.
13. HARLEY, J. P. 1972. *Paragonimus kellicotti* in Kentucky. Am. Midl. Nat. 88: 474-475.
14. HOLMES, J. C. and R. PODESTA. 1968. The helminths of wolves and coyotes from the forested regions of Alberta. Can. J. Zool. 46: 1193-1204.
15. JORDAN, H. E. and E. E. BYRD. 1958. *Paragonimus* in wild and domesticated animals in Georgia. J. Parasit. 44: 470.
16. KENNEDY, A. H. 1949. *Paragonimus* infestation in a ranch-raised fox. Rept. Ont. Vet. Coll., pp. 132-137.
17. KINGSCOTE, A. A. 1930. A case of paragonimiasis in the Ontario domestic fox. Rept. Ont. Vet. Coll., p. 40.
18. KINGSCOTE, A. A. 1931. A case of *Paragonimus kellicotti* (lung fluke) infestation in ranch-raised mink. Rept. Ont. Vet. Coll., p. 62.
19. La RUE, G. R. and D. J. AMEEL. 1937. The distribution of *Paragonimus*. J. Parasit. 23: 382-388.
20. McKEEVER, S. 1958. Observations on *Paragonimus kellicotti* Ward from Georgia. J. Parasit. 44: 324-327.
21. MILLER, G. C. and R. HARKEMA. 1964. Studies on helminths of North Carolina vertebrates. V. Parasites of the mink, *Mustela vison* Schreber. J. Parasit. 50: 717-720.
22. PRESIDENTE, P. J. A. and R. O. RAMSDEN. 1975. *Paragonimus kellicotti* infection in wild carnivores in southwestern Ontario: II. Histopathologic features. (MS submitted to J. Wildl. Dis.)
23. SEALANDER, J. A. 1943. Notes on some parasites of the mink in southern Michigan. J. Parasit. 29: 361-362.
24. SMITH, A. J. 1911. Ova of *Shistosoma japonicum*; ova of *S. mansoni*; ova of *Paragonimus westermanii*. Proc. Path. Soc. Phila., n. s. 14: 64.
25. STUHT, J. N. and W. G. YOUATT. 1972. Heartworms and lung flukes from red foxes in Michigan. J. Wildl. Mgmt 36: 166-170.
26. THORNTON, J. E., R. R. BELL and M. J. REARDON. 1974. Internal parasites of coyotes in southern Texas. J. Wildl. Dis. 10: 232-236.
27. WALLACE, F. G. 1931. Lung flukes of the genus *Paragonimus* in American mink. J. Am. vet. med. Ass. 78: 229-234.
28. WALLACE, F. G. 1931. The North American lung fluke. Science 73: 481-482.

Received for publication 4 October 1974