

## **FIBROUS OSTEODYSTROPHY IN AN OPOSSUM**

Authors: LONG, GERALD G., STOOKEY, JAMES L., TERRELL, TIMOTHY G., and WHITNEY, GEORGE D.

Source: Journal of Wildlife Diseases, 11(2) : 221-223

Published By: Wildlife Disease Association

URL: <https://doi.org/10.7589/0090-3558-11.2.221>

---

BioOne Complete ([complete.BioOne.org](https://complete.BioOne.org)) is a full-text database of 200 subscribed and open-access titles in the biological, ecological, and environmental sciences published by nonprofit societies, associations, museums, institutions, and presses.

Your use of this PDF, the BioOne Complete website, and all posted and associated content indicates your acceptance of BioOne's Terms of Use, available at [www.bioone.org/terms-of-use](https://www.bioone.org/terms-of-use).

Usage of BioOne Complete content is strictly limited to personal, educational, and non - commercial use. Commercial inquiries or rights and permissions requests should be directed to the individual publisher as copyright holder.

---

BioOne sees sustainable scholarly publishing as an inherently collaborative enterprise connecting authors, nonprofit publishers, academic institutions, research libraries, and research funders in the common goal of maximizing access to critical research.

## FIBROUS OSTEODYSTROPHY IN AN OPOSSUM

GERALD G. LONG and JAMES L. STOOKEY, Pathology Division, U.S. Army Medical Research Institute of Infectious Diseases, Ft. Detrick, Frederick, Maryland 21701, U.S.A.

TIMOTHY G. TERRELL, Department of Pathology, College of Veterinary Medicine, University of California, Davis, California 95616, U.S.A.

GEORGE D. WHITNEY, Whitney Veterinary Clinic, Orange, Connecticut 06477, U.S.A.

**Abstract:** A free living opossum (*Didelphis marsupialis*) was found to have severe fibrous osteodystrophy of the maxilla and mandibles. No significant lesions were found in the kidneys, ruling out an etiology of renal secondary hyperparathyroidism. An etiology of primary hyperthyroidism or nutritional secondary hyperparathyroidism is suggested.

### INTRODUCTION

Fibrous osteodystrophy (osteitis fibrosa cystica) has been reported in many species. A recent review<sup>7</sup> lists several reports of degenerative bone disease in opossum. One of these reports<sup>2</sup> describes "osteosarcomata" in four opossums. Lesions described are compatible with those of fibrous osteodystrophy. Other reports were not available. To the best of our knowledge, fibrous osteodystrophy has not been reported in the opossum in current literature.

Fibrous osteodystrophy is classically characterized by bone resorption, fibrous replacement of marrow spaces, accelerated formation of nonmineralizing osteoid, and cystic degeneration in the fibrous tissue. The cause is an excess of parathyroid hormone, which may be either primary or secondary.<sup>9</sup> Primary hyperparathyroidism, due to a parathyroid adenoma, has rarely been reported in animals. Secondary hyperparathyroidism, commonly reported in animals, may be either nutritional or due to renal disease. Nutritional deficiencies of either vitamin D or calcium, or excessive dietary phosphorus may also cause hyperparathyroidism in many mammals, birds, and reptiles.<sup>4,5,9,10</sup> Renal insufficiency commonly causes fibrous osteodystrophy

(renal rickets, rubber jaw syndrome) in the dog.<sup>1,6,9</sup> Inability of the kidney to excrete phosphorus or a failure in the metabolic pathway of vitamin D leads to lowered blood calcium and hyperparathyroidism. The facial bones and mandibles are usually most severely affected.

### CASE HISTORY AND NECROPSY FINDINGS

An adult male opossum was found with prominent swellings in both maxillary regions. The animal drank water, but was anorectic, and apparently unable to close its mouth.

Necropsy was performed following euthanasia with an overdose of barbiturate. The enlargements in the maxillary regions were bilaterally symmetrical, about 3 cm in thickness as viewed from the oral surface and extended from just posterior to the canine teeth to the rear of the dental arcade (Fig. 1). The overlying gingiva was ulcerated, and the teeth were loosened. The entire maxillary bone was thickened, was generally firm, but pliable, with small gritty foci, and cut easily with a scalpel. The mandibles were similarly, but less severely, affected being about 1 cm thick and cut with more resistance. No other gross lesions were found.

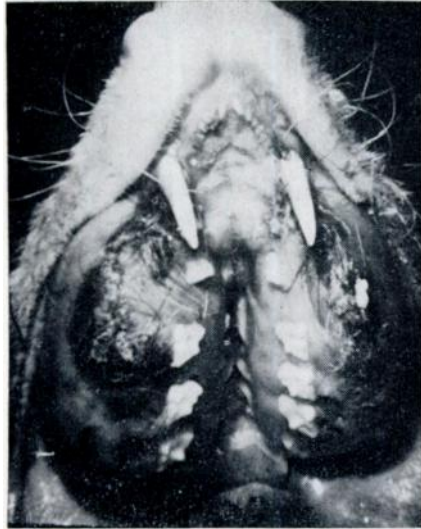

FIGURE 1. Opossum with fibrous osteodystrophy. Bilateral swelling of maxillae with ulceration of gums and displacement of the teeth.

Representative tissues were fixed in 10% neutral buffered formalin, embedded in paraffin, sectioned at 5-6  $\mu$ m, and stained with hematoxylin and eosin. Histologically, there was extensive proliferation of fibrous tissue in the marrow spaces of the maxilla and mandible. Cortical bone was greatly thinned or absent in some areas. Small trabeculae of osteoid were scattered throughout the mass (Fig. 2). Nonmineralized osteoid seams were present on the surface of many trabeculae. Numerous osteoclasts were within notches of remaining bone spicules.

Marked depletion of colloid was present throughout the thyroid. Minimal hemosiderin deposits in the spleen, mild colitis and a minimal lymphocytic infiltrate in the liver were noted. The kidney was histologically normal. Unfortunately, the parathyroids were not located.

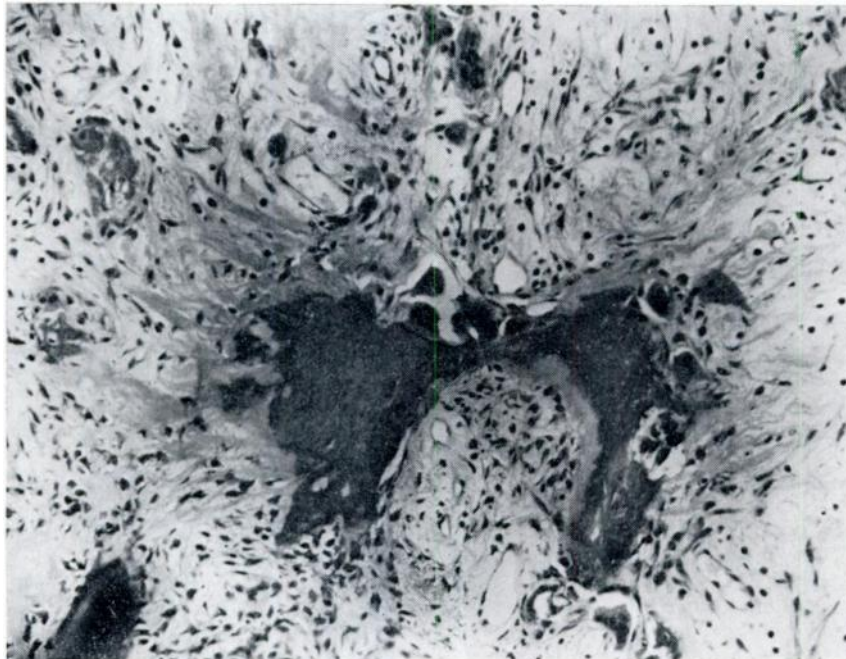


FIGURE 2. Fibrous proliferation, osteoclastic bone resorption, and osteoid production, maxilla, opossum. H & E  $\times 128$

## DISCUSSION

This case of fibrous osteodystrophy in an opossum resembled the changes in maxillary bones and mandibles commonly noted in dogs with chronic renal disease.<sup>1,4,9</sup> The kidneys in this case, however, were found not to be diseased. Hence, the presumed hyperparathyroidism was primary, or secondary, due to a nutritional imbalance. Although rarely

reported in animals, a functional parathyroid adenoma can not be ruled out in this case. Since the natural diet of the opossum is varied,<sup>8</sup> future cases should be investigated for a possible nutritional etiology. Furthermore, the kidneys should be thoroughly examined in cases of fibrous osteodystrophy, since a high incidence of renal disease has been reported in captive members of this species.<sup>8</sup>

## LITERATURE CITED

1. BRADEY, R. S. 1954. Renal osteitis fibrosa cystica in a Wirehaired Fox Terrier. J. Am. vet. med. Ass. 124: 275-278.
2. FOX, H. 1923. *Disease in Captive Wild Mammals and Birds*. Lippincott Co., Philadelphia, Pennsylvania. 359-369.
3. HAMILTON, W. J., JR. 1951. The food of the opossum in New York State. J. Wildl. Mgmt 15: 258-264.
4. HUNT, R. D., F. G. GARCIA and D. M. HEGSTED. 1967. A comparison of vitamin D<sub>2</sub> and D<sub>3</sub> in New World primates. I. Production and regression of osteodystrophia fibrosa. Lab. Anim. Care 17: 222-234.
5. KROOK, L., R. B. BARRETT, U. KAZUYA, R. E. WOLKE. 1963. Nutritional secondary hyperparathyroidism in the cat. Cornell Vet. 53: 224-240.
6. NIELSEN, S. W. and B. J. McSHERRY. 1954. Renal hyperparathyroidism (rubber jaw syndrome) in a dog. J. Am. vet. med. Ass. 124: 270-274.
7. POTKAY, S. 1970. Diseases of the opossum (*Didelphis marsupialis*): a review. Lab. Anim. Care 20: 502-511.
8. SHERWOOD, B. B., D. T. ROWLANDS, JR., D. B. HACKEL and J. C. LEMAY. 1969. The opossum, *Didelphis virginiana*, as a laboratory animal. Lab. Anim. Care 19: 494-499.
9. SMITH, H. A., T. C. JONES and R. D. HUNT. 1972. *Veterinary Pathology*, 4th ed. Lea and Febiger, Philadelphia, 1063-1067.
10. WALLACH, J. D. and C. HOESSLE. 1968. Fibrous osteodystrophy in green Iguanas. J. Am. vet. med. Ass. 153: 863-865.

Received for publication 30 August 1974