

SPONTANEOUS DERMATOPHILOSIS IN TWIN WHITE-TAILED DEER FAWNS 1

Author: ROSCOE, DOUGLAS E.

Source: Journal of Wildlife Diseases, 11(3) : 398-401

Published By: Wildlife Disease Association

URL: <https://doi.org/10.7589/0090-3558-11.3.398>

BioOne Complete (complete.BioOne.org) is a full-text database of 200 subscribed and open-access titles in the biological, ecological, and environmental sciences published by nonprofit societies, associations, museums, institutions, and presses.

Your use of this PDF, the BioOne Complete website, and all posted and associated content indicates your acceptance of BioOne's Terms of Use, available at www.bioone.org/terms-of-use.

Usage of BioOne Complete content is strictly limited to personal, educational, and non - commercial use. Commercial inquiries or rights and permissions requests should be directed to the individual publisher as copyright holder.

BioOne sees sustainable scholarly publishing as an inherently collaborative enterprise connecting authors, nonprofit publishers, academic institutions, research libraries, and research funders in the common goal of maximizing access to critical research.

SPONTANEOUS DERMATOPHILOSIS IN TWIN WHITE-TAILED DEER FAWNS[†]

DOUGLAS E. ROSCOE, Northeastern Research Center for Wildlife Diseases,
University of Connecticut, U-89, Storrs, Connecticut 06268, USA

ROBERT C. LUND, New Jersey Division of Fish, Game and Shellfisheries,
Clinton Wildlife Management Area, R.D., Clinton, New Jersey 08809, USA

MORRIS A. GORDON and IRA F. SALKIN, Division of Laboratories and Research,
New York State Department of Health, Albany, New York 12201, USA

Abstract: Twin white-tailed deer (*Odocoileus virginianus*) fawns captured in Morris County, New Jersey, displayed papular, darkly pigmented scabs principally on the skin overlying the nasal bones, dentary, commissure of the lips and ears. Histopathological and bacterial examinations revealed *Dermatophilus congolensis*. The epidermitis caused by this bacterium apparently had developed within the first 12 to 14 days after birth and had begun to regress by one month of age. The location of the lesions suggested transmission during nursing from an infected doe. This is believed to be the first confirmed report of this zoonotic disease in white-tailed deer, with isolation of the etiologic agent, outside the State of New York. Epizootiological considerations are discussed.

INTRODUCTION

Dermatophilosis is a zoonotic, exudative epidermitis. This condition is also termed streptothricosis, lumpy wool and strawberry foot rot, which is caused by the bacterial agent, *Dermatophilus congolensis*.^{4,5} Roberts has suggested that "dermatophilosis" is an appropriate name for the disease.¹⁰

Dermatophilosis is worldwide in distribution, although the disease is most pronounced in countries with tropical and subtropical climates. The incidence of clinical cases has a positive correlation with wet weather, wetting of scabs releases motile zoospores, thus probably spreading the lesions on a given host.^{8,9}

Spontaneous dermatophilosis has been diagnosed in man and a wide variety of domestic and wild animals.^{11,12} Four cases of dermatophilosis of white-tailed deer have been reported.^{3,6,18,14} Three of these were from New York State and one

from South Carolina. The researchers in the latter case attributed death of a fawn to dermatophilosis, but *D. congolensis* was not isolated.

This paper describes the first cases of dermatophilosis from the State of New Jersey, found in twin white-tailed deer fawns.

CASE HISTORY

Twin male and female fawns approximately 2 to 6 days old, found by residents of Chester Township, Morris County, New Jersey during the first week of June 1974, were taken into captivity and bottle-fed for 10 days. At some time prior to the end of bottle feeding darkly pigmented bumps and encrustations on the muzzle and ears of both fawns became noticeable and their captors, suspecting disease, submitted them to the New Jersey Division of Fish, Game and Shellfisheries. The six people who came

[†] The authors wish to express their appreciation for the cooperation and assistance of Dr. Ward B. Stone, Associate Wildlife Pathologist, New York State Department of Environmental Conservation, Albany, New York.

in contact with the fawns reportedly did not develop skin lesions. The fawns were transported to the New York State Department of Environmental Conservation's Wildlife Research Laboratory for examination and observation. Crusts and a biopsy of lesions from the muzzle and ears of the 4-week old animals were taken to the Division of Laboratories and Research of the New York State Department of Health for bacterial examination and culture. After 45 days of observation the fawns were killed for necropsy and histopathologic study.

Gross Pathology

The buck fawn displayed more extensive lesions than did the doe. In both animals the primary sites involved were the skin overlying the nasal bones, dentary, ears and commissures of the lips. The dark, scab-covered papules, 6 to 9 mm

in diameter, tended to coalesce. Small abscesses were evident in the skin of the ears. When the fawns were 1 month old there was little exudate from the lesions, and dry, denuded wrinkled areas had developed around the papules on the muzzle (Fig. 1). The buck had one small skin lesion of the right metatarsus. Internal organs of both animals appeared normal at necropsy.

Histopathology

In Giemsa-stained 10 μ m frozen sections from skin lesions, long, parallel chains and individual coccoid cells characteristic of *D. congolensis* were evident primarily in the stratum corneum, with foci of these organisms frequently associated with hair follicles (Fig. 2). Hyperkeratosis, delamination and erosion of the stratum corneum resulted from local proliferations of these bacteria. The cel-



FIGURE 1. White-tailed deer buck fawn with papules of dermatophilosis on the muzzle and ear margin.

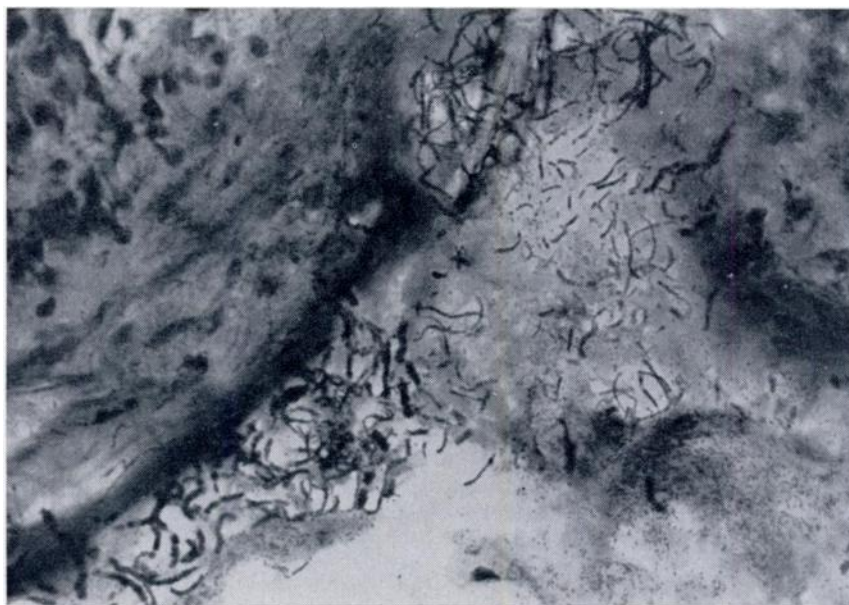


FIGURE 2. *Dermatophilus congolensis* chains and cocci proliferating in the stratum corneum at a hair follicle. Giemsa. x 440.

lular inflammatory response was characterized principally by monocytes and lymphocytes in the superficial dermis. Occasionally, coccoid chain fragments were observed in dermal macrophages.

Bacteriology

Crusts were washed in dishes of sterile distilled water in order to remove superficial contaminating microorganisms, and the moist underside of each was rubbed on an approximately 2 cm² area of a beef heart infusion-horse blood agar plate; this material was then streaked for bacterial isolation with an inoculating loop, and plates were incubated at 35 C. Colonies of *D. congolensis* (0.5-1 mm, opaque, white to yellowish, raised, bumpy, adherent; leaving growth in the agar when removed) were identifiable among bacterial and fungal contaminants within 48 h on a majority of inoculated plates, and pure cultures were obtained by transfer to beef heart infusion agar slants.

Following inoculation of the culture medium, the same crusts were rubbed on microscope slides and the resulting films stained by either methylene blue or Giemsa methods. Examination showed parallel-beaded filaments and hyphal and coccoid forms typical of *D. congolensis*.

DISCUSSION

The gross appearance of the lesions on the muzzle, jaw and ears was similar to "milk scald" in calves,¹¹ and is similar to that previously described in a nursing fawn.¹³

In cattle the initial site of infection is frequently the groin area, possibly as a result of a predilection of vector ticks for this site.¹¹ Contact with wet skin, as might be expected to occur during nursing, facilitates the transmission of motile zoospores in sheep.⁷ The restriction of lesions primarily to the rostral area suggests that the microorganisms may have been transmitted during nursing from an

infected doe. No livestock were present in the location where the fawns were captured, nor were they exposed to livestock during their captivity, so this source of disease seems unlikely. The small skin lesion on the hind leg of the buck may have been the result of this animal's habit of scratching its head with its hind hoof.

The incubation period for dermatophilosis in lambs and calves is from 2 to 14 days,¹¹ which corresponds well with observations of lesions on the fawns at about 12 to 14 days of age.

The dry, denuded, wrinkled areas occurring around the scabs on the muzzle are indicative of healing.¹¹ The difficulty in locating bacterial foci in histological sections also indicated spontaneous remission.

The discovery of dermatophilosis in deer in New Jersey may reflect a spread

of this disease from neighboring eastern New York State, where three cases in wild deer have been reported since 1961.^{9,13,14} As has been suggested by Stone,¹³ perhaps the relatively recent (since 1961) discovery of dermatophilosis in domestic animals and wildlife of North America is the result of foreign livestock and exotic wildlife importations. Dermatophilosis of deer has been transmitted spontaneously to man and experimentally to domestic livestock.⁸ Its establishment in a wild host as widely distributed as the white-tailed deer could be a serious epizootiological problem, especially since the disease causes livestock and economic (i.e., hide damage) losses^{1,2} and has been implicated in the death of a deer in the United States.⁶ The zoonotic nature of *D. congolensis* is an additional argument against the removal of fawns from the wild for pets.

LITERATURE CITED

1. AUSTWICK, K. C. and E. T. DAVIES. 1958. Mycotic dermatitis in Great Britain. *Vet. Rec.* 70: 1081-1086.
2. COLEMAN, C. H. 1967. Cutaneous streptothricosis of cattle in West Africa. *Vet. Rec.* 81: 251-254.
3. DEAN, D. J., M. A. GORDON, C. W. SEVERINGHOUS, E. T. KROLL and J. P. REILLY. 1961. Streptothricosis: a new zoonotic disease. *N.Y. State J. Med.* 61: 1283-1287.
4. GORDON, M. A. 1962. Speciation of *Dermatophilus*. *Annual Rep. N.Y. St. Dept. Health Div. Lab. Res.* 1961: 83-84.
5. ———. 1964. The genus *Dermatophilus*. *J. Bact.* 88: 509-522.
6. KISTNER, T. P., E. B. SHOTTS, Jr. and E. W. GREENE. 1970. Naturally occurring cutaneous streptothricosis in a white-tailed deer (*Odocoileus virginianus*). *J. Am. vet. med. Ass.* 157: 633-635.
7. LeRICHE, P. D. 1968. The transmission of dermatophilosis (mycotic dermatitis) in sheep. *Aust. Vet. J.* 44: 64-67.
8. ROBERTS, D. S. 1963. The release and survival of *Dermatophilus dermatonomus* zoospores. *Aust. J. Agric. Res.* 14: 386-399.
9. ———. 1963. Chemotactic behavior of infected zoospores of *Dermatophilus dermatonomus*. *Ibid.* 14: 400-411.
10. ———. 1967. *Dermatophilus* infection. *Vet. Bull.* 37: 513-521.
11. STEWART, G. H. 1972. Dermatophilosis: a skin disease of animals and man. Part I. *Vet. Rec.* 91: 537-544.
12. ———. 1972. Dermatophilosis: a skin disease of animals and man. Part II. *Vet. Rec.* 91: 555-561.
13. STONE, WARD B. 1972. Dermatophilosis (cutaneous streptothricosis) in a white-tailed deer fawn. *N.Y. Fish and Game J.* 19: 92-95.
14. ———. 1972. Another case of dermatophilosis in white-tailed deer. *N.Y. Fish and Game J.* 19: 184.

Received for publication 24 January 1975