

ECTOPIC FETUSES IN TWO COTTONTAIL RABBITS 1

Authors: JACOBSON, HARRY A., KIBBE, DOUGLAS P., and KIRKPATRICK, ROY L.

Source: Journal of Wildlife Diseases, 11(4) : 540-542

Published By: Wildlife Disease Association

URL: <https://doi.org/10.7589/0090-3558-11.4.540>

BioOne Complete (complete.BioOne.org) is a full-text database of 200 subscribed and open-access titles in the biological, ecological, and environmental sciences published by nonprofit societies, associations, museums, institutions, and presses.

Your use of this PDF, the BioOne Complete website, and all posted and associated content indicates your acceptance of BioOne's Terms of Use, available at www.bioone.org/terms-of-use.

Usage of BioOne Complete content is strictly limited to personal, educational, and non - commercial use. Commercial inquiries or rights and permissions requests should be directed to the individual publisher as copyright holder.

BioOne sees sustainable scholarly publishing as an inherently collaborative enterprise connecting authors, nonprofit publishers, academic institutions, research libraries, and research funders in the common goal of maximizing access to critical research.

ECTOPIC FETUSES IN TWO COTTONTAIL RABBITS¹

HARRY A. JACOBSON, DOUGLAS P. KIBBE² and ROY L. KIRKPATRICK,
Department of Fisheries and Wildlife Sciences, Virginia Polytechnic Institute and
State University, Blacksburg, Virginia 24061, USA

Abstract: Mummified fetuses were discovered in the abdominal cavities of two cottontail rabbits (*Sylvilagus floridanus*) collected during separate years from the same geographical location in Virginia. One of these rabbits had a patent opening through the vaginal wall to the abdominal cavity. The uterus and vagina of the second rabbit appeared normal.

CASE REPORT

During separate research projects on free-living cottontail rabbits (*Sylvilagus floridanus*) in Montgomery Co., Virginia in 1968 and 1974, two female rabbits were collected with fetuses present in the abdominal cavity. Both rabbits appeared to be in very good condition and weighed 1545 and 1556 g, respectively.

The rabbit collected in 1968 had eight fully formed fetuses, with placentas attached, in the abdominal cavity. Five fetuses were individually encapsulated within tough connective tissue membranes formed around the fetal membranes. The other three were contained within a single capsule. No fluid was present within the capsules, and the fetuses although well preserved, appeared dehydrated. The total weight for all fetuses and placentas was 139 g, and all were of approximately the same size. The uterus was empty and the gross appearance of the reproductive tract was similar to that of a nonpregnant female. The cephalic vaginal walls were extremely thin and a small (approximately 4 mm) patent opening was present from the vagina to the abdominal cavity. The cervixes were located in the horns cephalic to the external bifurcation rather than caudal as in a normally developed female rabbit. Ovaries of

this rabbit contained six fully developed corpora lutea and numerous corpora albicantia which protruded from the ovarian surface and were more prominent than those normally seen.

The rabbit collected in 1974 had two individually encapsulated fetuses free in the abdominal cavity, five normal fetuses in the uterus and one fetus being resorbed within the uterine horns (Figure 1). The encapsulated fetuses were dehydrated but well preserved. These two fetuses together with their surrounding tissues weighed 18.0 and 15.1 g. Mean crown-rump measurement of the five normal fetuses was 16 mm. The fetus being resorbed was an amorphous mass contained within a uterine swelling. No openings into the abdomen or other abnormalities were detected in the genital tract. Six corpora lutea were present on the ovaries.

DISCUSSION

This is the first report known to us of ectopic fetuses in *Sylvilagus*, although the condition has been reported in members of the genera *Lepus* and *Oryctolagus*.^{3,4,5} The ectopic fetuses of the first rabbit probably arrived in the abdominal cavity through the opening in the vaginal wall

¹ Contribution No. FiW 75-53.

² Present address: NUS Corp., 1910 Cochran Road, Pittsburgh, PA 15220, USA.

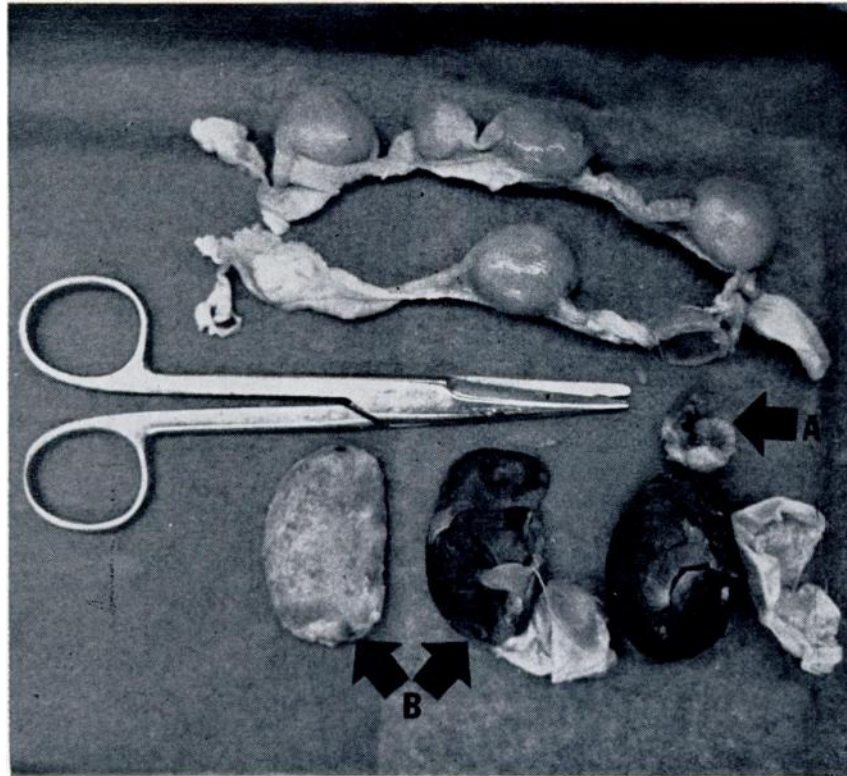


FIGURE 1. Uterus and fetuses (ectopic and normal) taken from a cottontail rabbit. A. Fetus removed from the uterine horn. B. Ectopic fetus split longitudinally to show fetus and surrounding connective tissue.

during attempted parturition. Although mummified, their weight and general appearance indicated they were near term.⁶ Conception or implantation apparently was not occurring in this rabbit as evidenced by the empty uterus and the presence of well-developed corpora lutea. Since all lagomorphs are believed to be induced ovulators,¹ the presence of corpora lutea is indicative of copulation. The presence of numerous corpora albicantia along with the corpora lutea can be interpreted as indicating a series of recurring pseudopregnancies. The length of pseudopregnancy in the cottontail has

been suggested at 15 to 16 days.¹ One might expect the corpora albicantia of the previous pseudopregnancy to be less regressed than those present on ovaries after a normal pregnancy, since a shorter time span is available in pseudopregnancy for these structures to regress.

As there was no indication that the reproductive tract of the second rabbit had ruptured, possibly the ectopic fetuses found in this animal developed within the abdominal cavity. Implantation with subsequent development of fetuses to full term was postulated to have occurred within the abdomen of a black-tailed jack rabbit.⁴ Moreover, there

is a postulation that fetuses within the abdomen can only result from tubular expulsion or from rupture of the genital tract.³ Although abdominal pregnancy has been reported in humans,² we are unaware of any documented case of abdominal implantation with subsequent development to full-term.

LITERATURE CITED

1. ASDELL, S. A. 1964. *Patterns of Mammalian Reproduction*. Cornell Univ. Press, Ithaca, N.Y. 670 p.
2. BREEN, J. L. 1970. A 21 year survey of 654 ectopic pregnancies. *Am. J. Obstet. Gynec.* 106: 1004-1019.
3. EALES, N. B. 1932. Abdominal pregnancy in animals, with an account of a case of multiple ectopic gestation in a rabbit. *J. Anat.* 67: 108-117.
4. EVANS, J. and R. E. GRIFFITH. 1972. Reproductive anomalies in black-tailed jackrabbits. *J. Mammal.* 53: 192-194.
5. FLUX, J. C. 1967. Reproduction and body weights of the hare *Lepus europaeus* Pallas, in New Zealand. *N.Z. J. Sci.* 10: 357-401.
6. RONGSTAD, O. J. 1969. Gross prenatal development of cottontail rabbits. *J. Wildl. Manage.* 33: 164-168.

Received for publication 7 January 1975