



## **RABIES IN A PRONGHORN ANTELOPE, *Antilocapra americana* 1**

Author: WEMPE, J. M.

Source: Journal of Wildlife Diseases, 12(3) : 347-348

Published By: Wildlife Disease Association

URL: <https://doi.org/10.7589/0090-3558-12.3.347>

---

BioOne Complete ([complete.BioOne.org](https://complete.BioOne.org)) is a full-text database of 200 subscribed and open-access titles in the biological, ecological, and environmental sciences published by nonprofit societies, associations, museums, institutions, and presses.

Your use of this PDF, the BioOne Complete website, and all posted and associated content indicates your acceptance of BioOne's Terms of Use, available at [www.bioone.org/terms-of-use](http://www.bioone.org/terms-of-use).

Usage of BioOne Complete content is strictly limited to personal, educational, and non - commercial use. Commercial inquiries or rights and permissions requests should be directed to the individual publisher as copyright holder.

---

BioOne sees sustainable scholarly publishing as an inherently collaborative enterprise connecting authors, nonprofit publishers, academic institutions, research libraries, and research funders in the common goal of maximizing access to critical research.

## RABIES IN A PRONGHORN ANTELOPE, *Antilocapra americana*<sup>□</sup>

J. M. WEMPE, Department of Veterinary Science, Animal Disease Research and Diagnostic Laboratory, South Dakota State University, Brookings, South Dakota 57006, USA

**Abstract:** A ten week old antelope died from rabies 35 days after being bitten on the left hock by a skunk. The result of the direct fluorescent antibody test for rabies was positive.

### INTRODUCTION

There is a paucity of information on the occurrence of rabies in the pronghorn antelope (*Antilocapra americana*) although at least one case is reported to have occurred in the United States.<sup>2</sup> The purpose of this report is to document a case of rabies in an antelope during July, 1975, in South Dakota.

### CASE REPORT

A 10 week-old antelope fawn was found by a child in western South Dakota during the first week of June, 1975. Twenty-one days later, during early evening, the antelope was bitten on the left hock by a skunk, which escaped. The owner observed the incident, which took place in a barn on the owner's premises. Thirty-three days after the bite, the fawn became lethargic and anorectic and died two days later.

Impression smears of the hippocampus were positive for rabies antigen by the fluorescent antibody test (FAT).<sup>1</sup> Three mice were inoculated intracranially with 0.03 ml of a suspension of ground hippocampus in 0.75% bovine albumen solution (pH 7.7, Fraction V). Twenty-five

days after inoculation, one mouse developed central nervous signs. This mouse brain was positive for rabies by FAT. The other two mice failed to develop signs during a 45 day observation period. These two mice were not examined by FAT.

After the hippocampus was removed, the remainder of the brain was fixed in 10% buffered formalin. Hematoxylin-eosin stained sections were prepared by conventional methods from paraffin embedded tissue.

Histologic examination of the medulla revealed severe non-suppurative inflammation characterized by focal and diffuse gliosis, and lymphocytic perivascular cuffing (Fig. 1). Eosinophilic intracytoplasmic inclusion bodies were present (Fig. 2) and were most prominent in large neurons at the approximate level of cranial nucleus X. Small aggregates of lymphocytes were scattered throughout the leptomeninges of the cerebellum and a few Purkinje cells contained intracytoplasmic inclusions. Minimal lymphocyte accumulations were in the leptomeninges of the cerebral cortex, and occasional small lymphocytic perivascular cuffs were in the cerebral white matter.

### Acknowledgement

The author would like to acknowledge Dr. M. E. Bergeland for histologic examination of the antelope brain tissue and Dr. G. E. Wheeler of Sturgis, South Dakota, the attending veterinarian.

<sup>□</sup> Approved for publication by the director, Agriculture Experiment Station, South Dakota State University as Journal Series No. 1386.

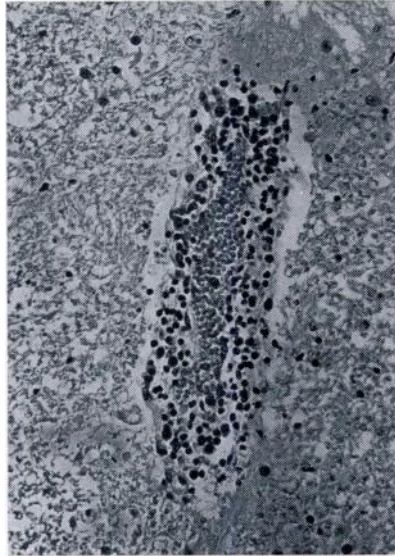


FIGURE 1. Lymphocytic perivascular cuffing of a blood vessel in the pons from a rabid antelope. H-E stain x 80.

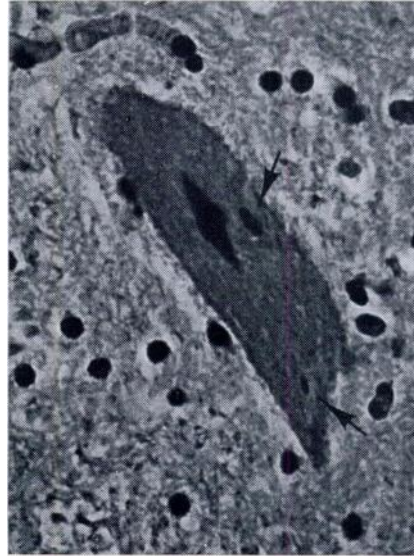


FIGURE 2. Two Negri bodies (arrows) within the cytoplasm of a neuron in the medulla from a rabid antelope. H-E stain x 800.

#### LITERATURE CITED

1. DEAN, D. J. 1966. Laboratory Technique in Rabies: World Health Organization, Geneva, Switzerland. pp. 59-68.
2. KAPPUS, K. A list of animal species reported positive for rabies in the United States 1938-1971. (Unpublished; obtained from W. G. Winkler, Center for Disease Control, Atlanta, Georgia).

*Received for publication 3 February 1976*