



INCLUSION BODY DISEASE OF FALCONS (HERPESVIRUS INFECTION) IN AN AMERICAN KESTREL

Authors: KOCAN, A. ALAN, POTGIETER, L. N. D., and KOCAN, K. M.

Source: Journal of Wildlife Diseases, 13(2) : 199-201

Published By: Wildlife Disease Association

URL: <https://doi.org/10.7589/0090-3558-13.2.199>

BioOne Complete (complete.BioOne.org) is a full-text database of 200 subscribed and open-access titles in the biological, ecological, and environmental sciences published by nonprofit societies, associations, museums, institutions, and presses.

Your use of this PDF, the BioOne Complete website, and all posted and associated content indicates your acceptance of BioOne's Terms of Use, available at www.bioone.org/terms-of-use.

Usage of BioOne Complete content is strictly limited to personal, educational, and non - commercial use. Commercial inquiries or rights and permissions requests should be directed to the individual publisher as copyright holder.

BioOne sees sustainable scholarly publishing as an inherently collaborative enterprise connecting authors, nonprofit publishers, academic institutions, research libraries, and research funders in the common goal of maximizing access to critical research.

INCLUSION BODY DISEASE OF FALCONS (HERPESVIRUS INFECTION) IN AN AMERICAN KESTREL

A. ALAN KOCAN,^[1] L. N. D. POTGIETER^[2] and K. M. KOCAN^[3]

Abstract: Postmortem examination of a captive-bred American kestrel (*Falco sparverius*) showed numerous white necrotic foci 1-2 mm in diameter throughout the liver and spleen. The results of light and electron microscopic studies and experimental transmission to a captive American kestrel and a barred owl (*Strix varia*) suggests a herpesvirus similar to those described for owls and other falcons in the U.S. This is the first report of a naturally occurring case of inclusion body disease of falcons in the American kestrel.

INTRODUCTION

A viral disease characterized by necrosis of components of the reticuloendothelial system and liver has been reported from a variety of raptors in North America. A herpesvirus has been incriminated as the etiological agent.^{1,2,3,4,6} The disease is characterized by a short clinical course with anorexia and listlessness. Postmortem findings are multiple necrotic foci of the liver, spleen, bone marrow, and intestinal wall. Intranuclear inclusions are commonly associated with cells adjacent to the necrotic regions. Lesion material has been reported for embryonated chicken egg, chicken embryo fibroblasts (CEF) and duck embryo fibroblasts (DEF). Lesion and culture material also have been reported infective in experimental infections of kestrels, owls, and other raptors.^{1,3,6}

CASE HISTORY

A female American kestrel (*Falco sparverius*), 6 to 7 months old, died following several days of anorexia, listlessness and weight loss. The bird had been captive bred and purchased by a falconer. The bird was maintained uneventfully as a captive falcon for six months. Two

days prior to the onset of these clinical signs, a 20-day-old pigeon squab had been fed to the falcon.

MATERIALS AND METHODS

At necropsy, the bird showed a marked hepatomegaly and splenomegaly. The liver and spleen had numerous pale foci of necrosis.

Liver tissues were fixed in 10% buffered formalin and washed with 0.8 M cacodylate buffer with 0.18 M sucrose. The tissues then were fixed in 2% glutaraldehyde in 0.08% cacodylate buffer at pH 7.2 for two h and washed in 0.08% cacodylate buffer with 0.18 M sucrose. They were then post-fixed for one h in aqueous osmium tetroxide in 0.8% cacodylate buffer, dehydrated in graded alcohols, and embedded in Dow Epoxy Resins. Thick sections (1.5-2.0 μ m) were cut on a Porter-Blum MT-2 microtome and were stained with Richardson's blue.⁴ Thin (silver reflective) sections were cut and stained with 5% aqueous uranyl acetate and lead citrate,⁶ and examined with a Phillips 200 electron microscope. Liver and spleen tissues were cultured on blood agar plates and examined for bacterial growth. Liver

[1] Department of Veterinary Parasitology, Microbiology and Public Health, Oklahoma State University, Stillwater, Oklahoma 74074, USA.

[2] Oklahoma Animal Disease Diagnostic Laboratory, Oklahoma State University.

[3] Department of Physiological Sciences, Oklahoma State University.

tissue was frozen at -20 C for subsequent characterizations.

Subsequently, a captive American kestrel and a barred owl (*Strix varia*) were inoculated intramuscularly with an 0.5 ml suspension of liver tissue from the naturally-infected kestrel.

RESULTS

Escherichia coli was isolated from the liver and spleen. No additional abnormalities or gross changes were noted.

Light microscopic examination of plastic embedded thick sections of liver revealed numerous foci of caseous necrosis. Numerous intranuclear inclusion bodies in association with necrotic hepatocytes were evident, adjacent to normal tissue (Figure 1).

Electron microscopic examination of liver tissue showed numerous intranuclear viral particles; chromatin masses were peripherally located (Figure 2).

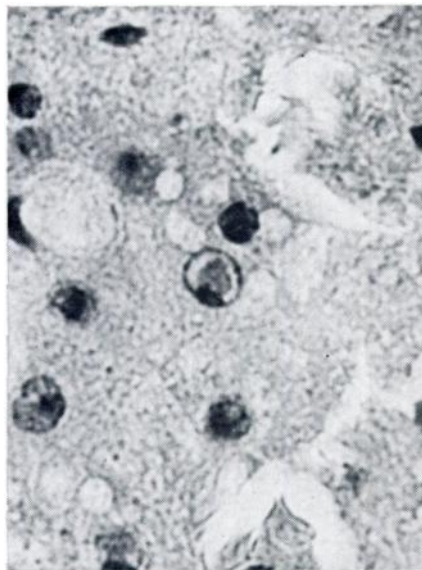


FIGURE 1. Liver of an American kestrel with naturally-acquired infection of inclusion body disease of falcons. Note large intranuclear inclusion in hepatocyte nuclei. H and E, approx X 700.

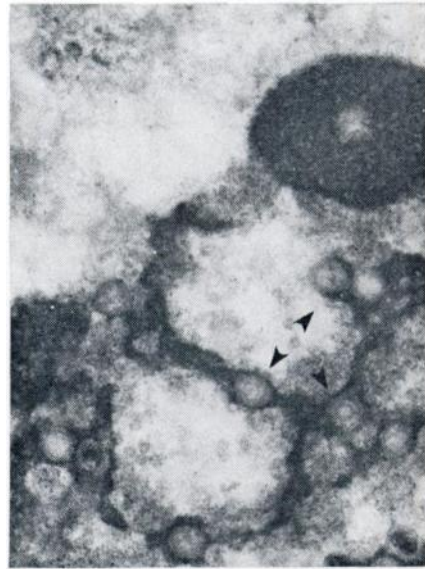


FIGURE 2. Portion of hepatocyte nucleus containing numerous nonenveloped viral particles from naturally-occurring infection of IBDF in an American kestrel. Magnification, X 30,000.

The experimentally inoculated American kestrel and barred owl developed clinical signs 12 days after infection and were killed 2 days later. Gross lesions, and light and electron microscopic studies of tissues, were similar to those observed in the naturally-infected kestrel.

DISCUSSION

This is the first report of a naturally occurring case of inclusion body disease of falcons in the American kestrel. The gross lesions and histologic changes, including intranuclear inclusions and demonstrable virus-like particles, are indistinguishable from those previously reported as herpesvirus infections from other raptors. Further characterizations and the determinations of host susceptibilities are presently under investigation for this isolate.

LITERATURE CITED

1. GRAHAM, D. L., C. J. MARE, F. P. WARD and M. C. PECKHAM. 1975. Inclusion body disease (Herpesvirus infection of falcons [IBDF]). J. Wildl. Dis. 11: 83-91.
2. MARE, C. J. and D. L. GRAHAM. 1973. Falcon herpesvirus, the etiologic agent of inclusion body disease of falcons. Infect. Imm. 7: 118-126.
3. SILEO, L., H. C. CARLSON and S. C. CRUMLEY. 1975. Inclusion body disease in a great horned owl. J. Wildl. Dis. 11: 92-96.
4. RICHARDSON, K. C., L. JARETT and E. H. FINKE. 1960. Stain Technol. 35: 313.
5. VENABLE, J. H. and R. COGGESHALL. 1965. A simplified lead citrate stain for use in electron microscopy. J. Cell Biol. 25: 407-408.
6. WARD, F. P., D. G. FAIRCHILD and J. V. VUICICH. 1971. Inclusion body hepatitis in a prairie falcon. J. Wildl. Dis. 7: 120-124.

Received for publication 14 October 1976
