

VIRAL INCLUSIONS IN RACCOON LIVER CELLS 1

Authors: SANGER, V. L., BICKNELL, E. J., TRAPP, A. L., ROEGE, E., ROBERTS, W., et al.

Source: Journal of Wildlife Diseases, 14(2) : 240-243

Published By: Wildlife Disease Association

URL: <https://doi.org/10.7589/0090-3558-14.2.240>

BioOne Complete (complete.BioOne.org) is a full-text database of 200 subscribed and open-access titles in the biological, ecological, and environmental sciences published by nonprofit societies, associations, museums, institutions, and presses.

Your use of this PDF, the BioOne Complete website, and all posted and associated content indicates your acceptance of BioOne's Terms of Use, available at www.bioone.org/terms-of-use.

Usage of BioOne Complete content is strictly limited to personal, educational, and non - commercial use. Commercial inquiries or rights and permissions requests should be directed to the individual publisher as copyright holder.

BioOne sees sustainable scholarly publishing as an inherently collaborative enterprise connecting authors, nonprofit publishers, academic institutions, research libraries, and research funders in the common goal of maximizing access to critical research.

VIRAL INCLUSIONS IN RACCOON LIVER CELLS[□]

V. L. SANGER,[□] E. J. BICKNELL,[□] A. L. TRAPP,[□] E. ROEGE,[□] W. ROBERTS[□] and R. F. LANGHAM[□]

Abstract: Three young raccoons (*Procyon lotor*), two from Michigan and one from Arizona, died suddenly from acute infections. Intranuclear inclusion bodies and viral particles typical of herpesvirus were seen in liver cells from all three. Inclusions also were seen in the nuclei of endothelial cells in the lung, liver, glomeruli and reticuloendothelial cells of the spleen. The source of the infection was not determined, but possible transmission from other species could not be ruled out.

INTRODUCTION

Raccoons (*Procyon lotor*) are naturally or experimentally susceptible to a number of different viral diseases. These include: canine distemper (paramyxovirus),^{4,10,14,18} infectious canine hepatitis (adenovirus),^{3,9,17} Eastern, Venezuelan and Western equine encephalomyelitis (togaviruses),^{2,16} pox virus¹ and pseudorabies (herpesvirus),¹⁹ rabies and vesicular stomatitis (rhabdovirus),^{12,13} feline enteritis (parvovirus)^{5,7,20} and encephalomyocardial disease (picornavirus).² This report describes a possible new viral disease in raccoons.

Case 1

Two immature raccoons were picked up along the highway at different times during the summer 1971 in western Michigan. They were taken to an animal orphanage to be nursed back to health before being released into the wild. At the orphanage they were caged with a tame, healthy kinkajou (*Potos flavus*). Five weeks after being placed in the cage one raccoon developed anorexia and was inactive. A rectal temperature of 40°C was recorded. The animal died two days later during a convulsion.

Necropsy revealed necrosis of the skin of the feet and slight enlargement of the spleen, iliac and lumbar lymph nodes. *Babesia*-like organisms were seen in erythrocytes on a stain blood smear. No pathogenic microorganisms were cultured from the internal organs.

Microscopically, the lesions included necrosis of germinal centers in the spleen and lymph nodes and focal necrosis throughout the liver. In addition, large basophilic intranuclear inclusions were seen in hepatic cells (Fig. 1), reticuloendothelial cells of the spleen and lymph nodes, and in capillary endothelial cells in the lungs and liver. The dense inclusions were large and numerous and usually filled the nucleus, although sometimes a halo was apparent. Their density obscured internal detail. Hepatic cells containing the inclusions were somewhat swollen and projected into the sinusoidal spaces.

The second animal died suddenly. Necropsy revealed hemorrhages in the skin, oral and gastric mucous membranes, and the cerebrum and cerebellum. Focal areas of necrosis were visible on the liver surface. The spleen was enlarged, and *Babesia*-like organisms were

[□] Michigan Agriculture Experiment Station Journal Article No. 6925

[□] Department of Pathology, Michigan State University, East Lansing, Michigan 48824, USA

[□] Veterinary Science Department, Mesa Experiment Station, University of Arizona, Mesa, Arizona 85201, USA

[□] Department of Microbiology and Public Health, Michigan State University, East Lansing, Michigan 48824, USA

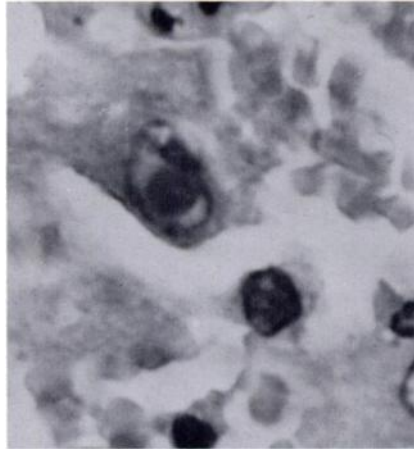


FIGURE 1. A dense intranuclear inclusion body in a hepatic cell from a young raccoon. H & E stain. $\times 4100$.

seen in erythrocytes on a stained blood smear. No pathogenic microorganisms were cultured from internal organs.

Microscopically, necrosis and hemorrhage were observed throughout the liver, lymph nodes and spleen. Generally, the necrotic areas in the liver were adjacent to the central veins. Large basophilic intranuclear inclusion bodies were seen in many hepatic cells and capillary endothelial cells in the kidney.

Case 2

A weaned female raccoon was purchased from a pet store in Arizona. At 10 weeks of age, she developed clinical signs of anorexia, malaise and diarrhea. Forty-eight hrs. later she was presented at an animal clinic. At this time, the visible mucous membranes were pale and the body temperature was subnormal. A tentative diagnosis of feline distemper was made. Fluids, corticosteroids and antibiotics were administered, but the animal died six hrs. later.

Necropsy examination revealed swollen kidneys, enlarged mesenteric lymph nodes and a small spleen. Microscopically, intranuclear inclusion bodies were

seen in endothelial cells of the renal glomerular tufts, in hepatocytes, and in the reticuloendothelial cells of the spleen and lymph nodes. These inclusions were indistinguishable from those seen in the other two animals. Hemorrhage was seen in the lymph nodes, and necrosis of lymphocytes had occurred.

Only formalin-fixed tissue was available for transmission electron microscopic examination (TEM). Nevertheless, TEM examination of inclusion bodies in hepatic cells from all three animals revealed many viral particles typical of herpesvirus (Fig. 2). With rare exception, all the viral particles were within the nucleus.

Tissue sections from five other raccoons submitted to this laboratory for a variety of reasons were examined for inclusion bodies, but none was found.

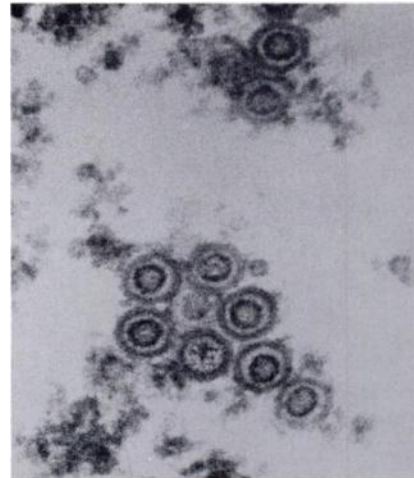


FIGURE 2. Viral particles typical of herpesvirus in the nucleus of a hepatic cell. Lead citrate, uranyl acetate stain. $\times 91000$.

DISCUSSION

The fact that no pathogenic microorganisms were isolated from the three raccoons strongly suggests that the

herpesvirus observed in intranuclear inclusions was the causative agent of this acute and fatal disease. The lesions, particularly the large intranuclear inclusions, were strikingly similar to lesions seen in raccoons infected with infectious canine hepatitis (ICH), an adenovirus.³ Although no description of such a herpesvirus disease in raccoons was found in the literature, J. King (pers. comm.) stated that he had seen inclusion bodies in a raccoon typical of ICH, but upon TEM examination, they contained herpesvirus. Similar acute hepatic diseases caused by herpesviruses have been reported in chinchillas and a variety of birds.^{6,11,15,21}

It is interesting to note that two of the raccoons were in contact with a kinkajou and the third was purchased from a pet store. Thus, it can be speculated that cross-species transmission occurred. Alternatively, it is possible that the herpesvirus was latent in the raccoons, and the stresses incidental to captivity activated the disease. In any event, herpesvirus "inclusion body hepatitis" may represent a new disease which must be considered when dealing with ICH-like lesions in raccoons. It is unfortunate that the virus was not isolated (no attempt was made) because validation of the disease will require characterization of the virus and pathogenicity studies.

LITERATURE CITED

1. ALEXANDER, A.D., V. FLYGER, Y.F. HERMAN, S.J. McCONNEL, N. ROTHSTEIN and R.H. YAGER. 1972. Survey of wild mammals in a Chesapeake Bay area for selected zoonoses. *J. Wildl. Dis.* 8: 119-126.
2. BIGLER, W.J., J.H. JENKINS, P.M. CUMBIC, G.L. HOFF and E.C. PRATHER. 1975. Wildlife and environmental health: Raccoons as indicators of zoonoses and pollutants in the southeastern United States. *J. Am. vet. med. Ass.* 167: 592-597.
3. BALIN, V.S., N. JARNEVIC and J.A. AUSTIN. 1958. Infectious canine hepatitis virus with special reference to passage of raccoon tissue cultures. *Proc. Soc. Exp. Biol. Med.* 98: 414-418.
4. BRUNER, D.M. and J.H. GILLESPIE (eds.). 1973. *Hagan's Infectious Diseases of Domestic Animals*. Cornell University Press, Ithaca. Sixth ed. Ch. 44, pp. 10-88.
5. BURGER, D. 1961. The relationship of mink virus enteritis to feline panleukopenia virus. M.S. thesis, Washington State University, Pullman.
6. BURTSCHER, H. 1975. Viral inclusion body hepatitis and splenitis in owls. *Zentbl. Allg. Path. Anat.* 107: 96.
7. GOSS, L.J. 1942. Diagnosis and treatment of diseases of wild animals in captivity. *Cornell Vet.* 32: 155-161.
8. DOUGLAS, P., and J.S. GILROY. 1970. Spontaneous herpes-like viral infection in a chinchilla (*Chinchilla laniger*). *J. Wildl. Dis.* 6: 175-179.
9. GREEN, R.G., C.A. EVANS and H.Y. YANAMURA. 1943. Susceptibility of the raccoon to fox encephalitis. *Proc. Soc. Exp. Biol. Med.* 53: 186-187.
10. HABERMAN, R.T., C.M. HERMAN and F.P. WILLIAMS. 1958. Distemper in raccoons and foxes suspected of having rabies. *J. Am. vet. med. Ass.* 132: 31-35.
11. HOWELL, J., D.W. MACDONALD and R.G. CHRISTIAN. 1970. Inclusion body hepatitis in chickens. *Can. Vet. J.* 11: 99-101.

12. KAPPAS, K.D., W.J. BIGLER, R.G. MCLEAN and H.A. TREVINO. 1970. The raccoon as an emerging rabies host. *J. Wildl. Dis.* 6: 507-509.
13. KARSTAD, L.H., E.V. ADAMS, R.P. HANSON and D.H. FERRIS. 1956. Evidence for the role of wildlife in epizootics of vesicular stomatitis. *J. Am. vet. med. Ass.* 129: 95-96.
14. KARSTAD, L.H., and J. BUDD. 1964. Distemper in raccoons characterized by giant cell pneumonitis. *Can. Vet. J.* 5: 326-330.
15. LEHNER, N.M.D., B.C. BULLOCK and T.B. CLARKSON. 1967. Intranuclear inclusion disease of pigeons. *J. Am. vet. med. Ass.* 151: 939-941.
16. PARKER, R.L., V.J. CABASSO, D.J. DEAN and E.L. CHEATUM. 1961. Serologic evidence of certain virus infections in wild animals. *J. Am. vet. med. Ass.* 138: 437-440.
17. PEREIRA, H.G., R.J. HUEBNER, H.S. GINSBERG and J. VAN DER VEERS. 1963. A short description of the adenovirus group. *Virology* 20: 613-620.
18. ROBINSON, V.B., J.W. NEWBERNE and D.M. BROOKS. 1957. Distemper in the American raccoon (*Procyon lotor*). *J. Am. vet. med. Ass.* 131: 276-278.
19. TRAINER, D.O., and L.H. KARSTAD. 1963. Experimental pseudorabies in some wild North American mammals. *Zoonoses Research* 2: 135-151.
20. WALLER, E.E., 1940. Infectious gastroenteritis in raccoons (*Procyon lotor*). *J. Am. vet. med. Ass.* 96: 266-268.
21. WARD, F.P., D.G. FAIRCHILD and J.V. VAICICH. 1971. Inclusion body hepatitis in a prairie falcon. *J. Wildl. Dis.* 7: 120-124.

Received for publication 9 September 1977
