



ENDOPARASITES OF SELECTED POPULATIONS OF COTTONTAIL RABBITS (*Sylvilagus floridanus*) IN THE SOUTHEASTERN UNITED STATES 1

Authors: ANDREWS, CHARLES L., and DAVIDSON, WILLIAM R.

Source: Journal of Wildlife Diseases, 16(3) : 395-401

Published By: Wildlife Disease Association

URL: <https://doi.org/10.7589/0090-3558-16.3.395>

BioOne Complete (complete.BioOne.org) is a full-text database of 200 subscribed and open-access titles in the biological, ecological, and environmental sciences published by nonprofit societies, associations, museums, institutions, and presses.

Your use of this PDF, the BioOne Complete website, and all posted and associated content indicates your acceptance of BioOne's Terms of Use, available at www.bioone.org/terms-of-use.

Usage of BioOne Complete content is strictly limited to personal, educational, and non - commercial use. Commercial inquiries or rights and permissions requests should be directed to the individual publisher as copyright holder.

BioOne sees sustainable scholarly publishing as an inherently collaborative enterprise connecting authors, nonprofit publishers, academic institutions, research libraries, and research funders in the common goal of maximizing access to critical research.

ENDOPARASITES OF SELECTED POPULATIONS OF COTTONTAIL RABBITS (*Sylvilagus floridanus*) IN THE SOUTHEASTERN UNITED STATES[□]

CHARLES L. ANDREWS and WILLIAM R. DAVIDSON, Southeastern Cooperative Wildlife Disease Study, Department of Parasitology, College of Veterinary Medicine, University of Georgia, Athens, Georgia 30602, USA.
ERNEST E. PROVOST, School of Forest Resources, University of Georgia, Athens, Georgia 30602, USA.

Abstract: During the fall of 1966 and spring of 1967, 260 cottontail rabbits (*Sylvilagus floridanus*) were collected from 13 sites in 8 southeastern states and examined for endoparasites. In order of prevalence, the endoparasites found were: *Obeliscoides cuniculi*, *Trichostrongylus calcaratus*, *Trichostrongylus affinis*, *Taenia pisiformis* (cysticerci), *Raillietina salmoni*, *Eimeria* spp., *Longistriata noviberiae*, *Cittotaenia variabilis*, *Hasstilesia tricolor*, *Trichuris leporis*, *Dermatoxys veligera*, *Passalurus ambiguus*, *Dirofilaria scapiceps*, *Sarcocystis* sp., *Linguatula serrata*, *Nematodirus leporis*, and *Gongylonema pulchrum*. Data are presented on prevalence and intensity of infection with each parasite along with information on geographic distribution. Cottontail rabbits in the southeastern United States show a higher level of parasitism than has been reported from other regions, although these higher parasite burdens were not necessarily associated with increased host morbidity.

INTRODUCTION

Considerable parasitologic literature is available on cottontail rabbits (*Sylvilagus floridanus*) of the midwest and eastern United States.^{1,3,6-8,19,21} The parasitologic information on rabbits in the Southeast is limited and fragmentary,^{11,12,15-18,23} and no region-wide survey appears in the literature. The present study was undertaken to establish base-line data on endoparasites of cottontail rabbits in the southeastern United States. Specific objectives were: (1) identify the endoparasite fauna; (2) determine the prevalence and intensity of parasitic infections; and (3) where possible, evaluate the pathogenicity of each parasite species encountered.

MATERIALS AND METHODS

Between August, 1966, and June, 1967, 260 adult rabbits were collected from 13 sites in 8 southeastern states (Figure 1). From each site, 10 rabbits were collected between August and December followed 6 months later by another 10 rabbit collection between February and June. All specimens were collected by shooting, and the carcasses were immediately placed in individual plastic bags and kept on ice until necropsy. After skinning, major internal organs were removed and representative tissue samples for histopathologic studies were placed in a 10% formalin solution. Following fixation, tissue samples were processed according to standard histologic procedures.

[□] This study was supported by an appropriation from the Congress of the United States. Funds were administrated and research coordinated under the Federal Aid in Wildlife Restoration Act (50 Stat. 917) and through Contract No. 14-16-0008-744, Fish and Wildlife Service, U.S. Department of the Interior.

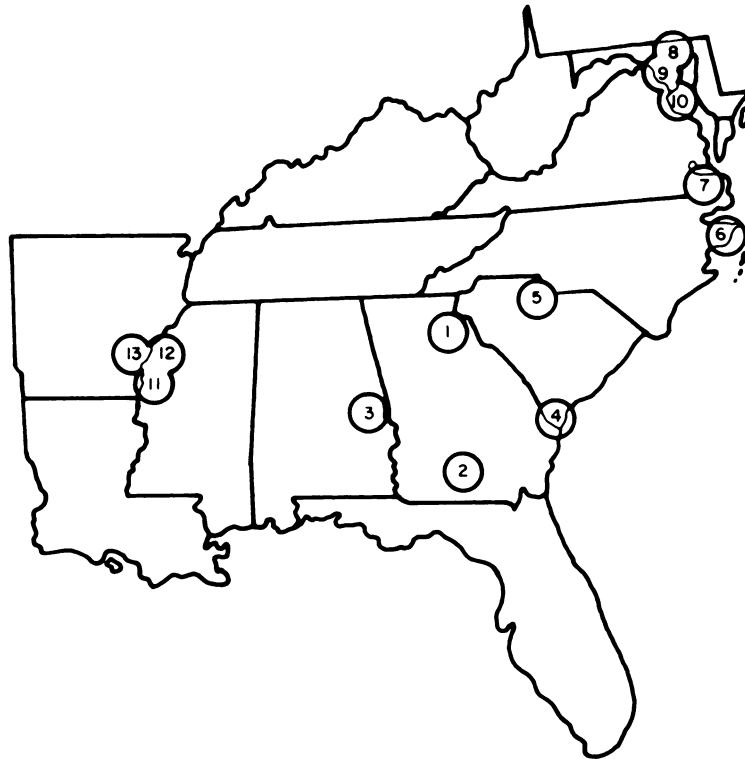


FIGURE 1. Distribution of collection sites within the southeastern United States. Location of sites are as follows: (1) Clarke County, Georgia; (2) Irwin County, Georgia; (3) Lee County, Alabama; (4) Hampton County, South Carolina; (5) Chester County, South Carolina; (6) Beaufort County, North Carolina; (7) Surry County, Virginia; (8) Howard County, Maryland; (9) Montgomery County, Maryland; (10) St. Marys County, Maryland; (11-12) Bolivar County, Mississippi; and (13) Desha County, Arkansas.

Each organ system was carefully examined for parasites. The gastrointestinal tract was split longitudinally, scraped, and the contents washed in a 100 mesh screen. The retained material was preserved in a solution containing formalin (5%) and acetic acid (2.5%). A 20% aliquot of the contents was taken to estimate the total parasite burden. Complete counts were made on parasite burdens with fewer than 500. When more than one species within a genus occurred, the percentage of each species was based

on a randomly taken sample of 10 males. Other parasite identifications were made utilizing conventional parasitologic techniques.

RESULTS AND DISCUSSION

Examination of 260 cottontail rabbits revealed parasitism by 2 protozoan, 1 trematode, 3 cestode, 10 nematode, and 1 pentastomid species (Table 1). Mention of parasites is in the order of prevalence within each phylogenetic group.

TABLE 1. Endoparasites recovered from cottontail rabbits collected in the South-east.

| Parasite | Percent Prevalence | Number per Infection | | Distribution |
|--|-----------------------|-------------------------|----------|---------------|
| | | Mean | Range | |
| PROTOZOA | | | | |
| <i>Eimeria</i> spp. (3,4)* | 52 | ..** | - | 1-13† |
| <i>Sarcocystis</i> sp. (5) | 11 | - | - | 1,3,5-9,11-13 |
| TREMATODA | | | | |
| <i>Hasstilesia tricolor</i> (3) (75425)†† | 37 | 3854 | 1-18,178 | 3-13 |
| CESTODA | | | | |
| <i>Taenia pisiformis</i> (cysticerci) (6,7) (75426) | 65 | 17 | 1-460 | 1-13 |
| <i>Raillietina salmoni</i> (3) (75428) | 53 | 30 | 1-282 | 1-8,10,11,13 |
| <i>Cittotaenia variabilis</i> (3) (75427) | 42 | 6 | 1-70 | 1-13 |
| NEMATODA | | | | |
| <i>Obeliscoides cuniculi</i> (2) (75434) | 93 | 86 | 1-1,736 | 1-13 |
| <i>Trichostrongylus calcaratus</i> (3) (75437) | 85 | 423 | 1-6,395 | 1-13 |
| <i>Trichostrongylus affinis</i> (3) (75436) | 71 | 219 | 1-3,862 | 1-13 |
| <i>Longistriata noviberiae</i> (3) (75432) | 51 | 138 | 1-1,598 | 2-6,11-13 |
| <i>Trichuris leporis</i> (4) (75438) | 29 | 5 | 1-108 | 1,3,5,7-13 |
| <i>Dermatoxys veligera</i> (4) (75429) | 27 | 9 | 1-115 | 1-6,8,10-13 |
| <i>Passalurus ambiguus</i> (4) (75435) | 17 | 2674 | 1-85,046 | 2,4-6,8 |
| <i>Dirofilaria scapiceps</i> (6) (75430) | 15 | 6 | 1-25 | 2,4-7,11,13 |
| <i>Gongylonema pulchrum</i> (1) (75431) | 1 | 4 | 1-6 | 3,5 |
| <i>Nematodirus leporis</i> (3) (75433) | 1 | 23 | 1-80 | 8,9 |
| PENTASTOMIDA | | | | |
| <i>Linguatula serrata</i> (7) | 2 | 2 | 1-4 | 2,3,9,11 |

*The numbers in parentheses indicate locations in the host: (1) esophagus, (2) stomach, (3) small intestine, (4) cecum and large intestine, (5) muscle, (6) subcutaneous, (7) body cavities.

**Value not determined.

†Numbers refer to Figure 1.

††Numbers in parentheses represent USNM Helm. Coll. Numbers.

Protozoa

Intestinal coccidia of the genus *Eimeria* were the most common protozoan parasites observed during the study. Although several authors^{6,15,19,24} have reported hemorrhagic lesions, catarrhal enteritis, denuded mucosa, and/or diarrhea, similar lesions were not found during the present study. The lack of salient coccidiosis lesions in this study, in conjunction with an absence of any cases of clinical coccidiosis in numerous wild rabbits examined by our regional wildlife disease diagnostic service (SCWDS, unpubl.), suggests that the pathogenicity of coccidian parasites in wild cottontails has been overestimated.

Sporozoan cysts were demonstrated by histologic examination of skeletal muscle tissue in 29 rabbits and tentatively designated as *Sarcocystis* sp. Investigators^{5,9} have demonstrated that the life cycle of *Sarcocystis leporum* may involve either domestic cats (*Felis domestica*) or raccoons (*Procyon lotor*). Crum and Prestwood⁵ further speculated that raccoons may be more frequent natural definitive hosts. *Sarcocystis* occurred in rabbits from all collection areas with the exception of St. Clement's Island, Maryland, which reportedly was free of terrestrial carnivores.

Trematoda

Hasstilesia tricolor, the rabbit intestinal trematode, was the only trematode recovered during the study. The scarcity of other trematodes in rabbits may be related to the dietary habits of rabbits, which result in infrequent ingestion of infected intermediate hosts and encysted larval forms.

Trematodes were attached to the mucosa in the proximal third of the small intestine, embedded among villi, or free in the intestinal lumen. Other authors^{14,19} have noted pathologic processes attributable to this parasite, but lesions associated with *H. tricolor* were considered minimal during the present study.

Cestoda

Cysticerci of *Taenia pisiformis* occurred frequently and infection sites included the thoracic, abdominal, and pelvic cavities, viscera, and subcutaneous tissues at the base of the tail. Previous reports^{1,15} have shown that heavy infections of this parasite can be pathogenic. Lesions attributable to *T. pisiformis* larvae were commonly observed as yellowish-white foci in the liver and, occasionally, other organs. Histologic lesions typically were focal granulomas with a center of caseous necrosis surrounded by a zone of fibroblasts, lymphocytes, and plasma cells. Frequently, cysticerci were not recovered at necropsy but histologic examination revealed extensive liver damage apparently from migrating larvae. The statement by Jacobson *et al.*¹⁵ that rabbits in this study had a "host allergic reaction" to *T. pisiformis* is erroneous.

In a study of cottontails in New York, Berg and Beck² speculated that the incidence of cysticerci infections was directly related to the number of infected dogs in an area. In the present study, the two areas with the highest mean cysticerci burdens were managed for cottontails and heavily hunted with dogs.

Raillietina salmone and *Cittotaenia variabilis* occurred frequently and with high intensity at several collection sites. Adult tapeworms in cottontail rabbits generally are considered to be non-pathogenic, although decreased serum globulin levels and increased bilirubin levels have been attributed to *Cittotaenia* infections.¹⁵

Nematoda

Obeliscoides cuniculi was the helminth parasite most frequently encountered and was recovered from all 13 collection sites. Other investigators^{1,8,15,18} also have found *O. cuniculi* to be the predominant helminth parasite of cottontail rabbits. On individual study sites, differences in average burdens of *O.*

cuniculi between the collection periods were obvious, with rabbits collected between February and June having burdens 2 to 4 times greater than between August and December. These findings are in agreement with the cyclical population fluctuation in natural infections of *O. cuniculi* reported in snowshoe hares (*Lepus americanus*).¹⁰

Although high intensities of infection, between 500 and 1,736 nematodes, were encountered in some rabbits, neither gross nor histologic examinations revealed substantial lesions attributable to either larval or adult *O. cuniculi*. Reports of pathogenic effects of *O. cuniculi* have ranged from a "mild catarrhal gastritis"¹³ to "severe gastric erosion."¹⁵ The notation by Jacobson *et al.*¹⁵ that rabbits in this study had hemorrhagic gastritis due to *O. cuniculi* is erroneous.

Prevalence and intensity of infections by *Trichostrongylus affinis* and *T. calcaratus* were greater than most previous reports.^{1,7,11,18,21} As with *O. cuniculi*, average intensities of infection with *T. affinis* and *T. calcaratus* were 2 to 5 times greater between February and June than between August and December. Neither gross nor microscopic lesions were associated with infections of either species of *Trichostrongylus*; however, other reports^{15,19,22} describe varying lesions or clinical signs, including death, in rabbits infected with *T. calcaratus*.

Longistriata noviberiae was recovered frequently from the small intestine, and data from this study suggest that this parasite may be more common than previously thought, especially in the southern portions of the Southeast.^{18,21}

Trichuris leporis occurred in the cecum and large intestine, and consistent with the findings of other investigators,^{7,18} there is little evidence to suggest that this nematode is pathogenic.

The prevalence and intensity of infection with the rabbit pinworms,

Dermatoxys veligera and *Passalurus ambiguus*, are comparable with previous reports.^{3,7,8,17,21} Apparently, cottontail rabbits are capable of harboring large numbers of these nematodes without ill effects.

Dirofilaria scapiceps occurred sporadically but was distributed over a large geographic region. Adult parasites were recovered from the subcutaneous tissues of the dorsal or lateral surfaces of the body rather than the subcutaneous and intramuscular areas of the hindlegs and feet as previously reported.^{4,16,20}

Two species of nematodes, *Nematodirus leporis* and *Gongylonema pulchrum*, were found rarely. *Nematodirus leporis* was found only on the upland Maryland collection sites. Based on the low prevalence of infection, the cottontail rabbit probably represents an incidental host for *Gongylonema pulchrum*. The occurrence of *G. pulchrum* in the cottontail rabbit constitutes a new host record.

Pentastomida

Nymphs of *Linguatula serrata* were collected infrequently from the intestinal mesenteries and visceral washings. All infections were considered light in intensity and lesions were not noted.

This survey revealed that cottontail rabbits in the Southeast have a variety of endoparasites and demonstrated a higher prevalence and intensity of infection when compared to previous studies conducted in the midwestern and eastern United States. Apparently, high parasite burdens in the Southeast are a manifestation of climatic parameters that enhance survival of parasite eggs, larvae, and intermediate hosts. High parasite burdens were not necessarily associated with pathologic processes but rather reflected a level of subclinical parasitism that can be considered usual for this host. In the present study only one species of endoparasite, cysticerci of *T. pisiformis*, was observed to produce substantial pathologic lesions.

LITERATURE CITED

1. BELL, J.F. and W.S. CHALGREN. 1943. Some wildlife diseases in the eastern United States. *J. Wildl. Manage.* 7: 270-278.
2. BERG, E. and R.D. BECK. 1968. Possible role of a sex factor in rabbit hosts naturally infected with *Taenia pisiformis* cysticerci. *J. Parasit.* 54: 1252-1253.
3. CLANCY, C.F., E. JUNGHERR and P.R. SIME. 1940. Internal parasites of cottontail rabbits in Connecticut. *J. Wildl. Manage.* 4: 162-168.
4. CRITES, J.L. and G.J. PHINNEY. 1958. *Dirofilaria scapiceps* from the rabbit (*Sylvilagus floridanus mearnsi*) in Ohio. *Ohio J. Sci.* 58: 128-130.
5. CRUM, J.M. and A.K. PRESTWOOD. 1977. Transmission of *Sarcocystis leporum* from a cottontail rabbit to domestic cats. *J. Wildl. Dis.* 13: 174-175.
6. ECKE, D.H. and R.E. YEATTER. 1956. Notes on the parasites of cottontail rabbits in Illinois. *Trans. Illinois Acad. Sci.* 48: 208-214.
7. ERICKSON, A.B. 1947. Helminth parasites of rabbits of the genus *Sylvilagus*. *J. Wildl. Manage.* 11: 255-263.
8. FRANKLIN, J., M.L. SIMMONS and G.E. COSGROVE. 1966. A pathogen survey in the Kansas cottontail. *Bull. Wildl. Dis. Ass.* 2: 52-53.
9. FAYER, R. and D. KRADEL. 1977. *Sarcocystis leporum* in cottontail rabbits and its transmission to carnivores. *J. Wildl. Dis.* 13: 170-173.
10. GIBBS, H.C., W.J. CRENSHAW and M. MOWATT. 1977. Seasonal changes in stomach worms (*Obeliscoides cuniculi*) in snowshoe hares in Maine. *J. Wildl. Dis.* 13: 327-332.
11. HARKEMA, R. 1936. The parasites of some North Carolina rodents. *Ecol. Monogr.* 6: 151-232.
12. HEARD, L.P. 1963. Notes on cottontail rabbit studies in Mississippi. *Proc. Ann. Conf. SE Ass. Game and Fish Comm.* Pp. 85-92.
13. HERMAN, C.M. and H.A. JANKIEWICA. 1943. Parasites of cottontail rabbits on the San Joaquin Experimental Range, California. *J. Wildl. Manage.* 7: 395-400.
14. JACOBSON, H.A., R.L. KIRKPATRICK and R.B. HOLLIMAN. 1974. Emaciation and enteritis of cottontail rabbits infected with *Hasstilesia tricolor* and observations on a fluke to fluke attachment phenomenon. *J. Wildl. Dis.* 10: 111-114.
15. ———, ——— and B.S. MCGINNES. 1978. Disease and physiologic characteristics of two cottontail populations in Virginia. *Wildl. Monogr.* 60: 1-53.
16. LLEWELLYN, L.M. and C.O. HANDLEY. 1945. The cottontail rabbits of Virginia. *J. Mammal.* 26: 379-390.
17. MCGINNES, B.S. 1964. Parasites of cottontail rabbits in southwestern Virginia. *Wildl. Dis. (Microcard)* 35. 11 pp.
18. MOORE, E.R. and G.C. MOORE. 1947. The helminths of cottontail rabbits in Alabama, with notes on the arthropod *Linguatula serrata*. *J. Mammal.* 28: 279-284.
19. MORGAN, B. B. and E.F. WALLER. 1940. A survey of the parasites of the Iowa cottontail (*Sylvilagus floridanus mearnsi*). *J. Wildl. Manage.* 4: 21-26.
20. PENNER, L.R., D.W. DERY and J.L. KUNCKLES. 1953. *Dirofilaria scapiceps* from *Sylvilagus floridanus* in New England. *J. Parasit.* 39: 676-677.

21. ROZYCKI, A.T. 1941. Studies on the intestinal nematodes of the cottontail rabbit. M.S. Thesis, Univ. of Minnesota. 57 pp.
22. SARLES, M.P. 1932. Fatal infections of *Trichostrongylus calcaratus* in rabbits. J. Parasit. 19: 157.
23. STRINGER, R.P., R. HARKEMA and G.C. MILLER. 1969. Parasites of rabbits in North Carolina. J. Parasit. 55: 328.
24. WALLER, E.F. and B.B. MORGAN. 1941. Pathology of *E. leporis* (Coccidia) in the cottontail rabbit. Am. J. Hyg. 34: 83-85.

Received for publication 28 August 1979
