

## **OSTEOARTHRISIS IN A WOLF (*Canis lupus*) RADIO-TRACKED IN MINNESOTA**

Author: FRITTS, S. H.

Source: Journal of Wildlife Diseases, 16(3) : 413-417

Published By: Wildlife Disease Association

URL: <https://doi.org/10.7589/0090-3558-16.3.413>

---

BioOne Complete ([complete.BioOne.org](https://complete.BioOne.org)) is a full-text database of 200 subscribed and open-access titles in the biological, ecological, and environmental sciences published by nonprofit societies, associations, museums, institutions, and presses.

Your use of this PDF, the BioOne Complete website, and all posted and associated content indicates your acceptance of BioOne's Terms of Use, available at [www.bioone.org/terms-of-use](https://www.bioone.org/terms-of-use).

Usage of BioOne Complete content is strictly limited to personal, educational, and non - commercial use. Commercial inquiries or rights and permissions requests should be directed to the individual publisher as copyright holder.

---

BioOne sees sustainable scholarly publishing as an inherently collaborative enterprise connecting authors, nonprofit publishers, academic institutions, research libraries, and research funders in the common goal of maximizing access to critical research.

## OSTEOARTHRITIS IN A WOLF (*Canis lupus*) RADIO-TRACKED IN MINNESOTA

S. H. FRITTS, <sup>□</sup> Bell Museum of Natural History, Department of Ecology and Behavioral Biology, 10 Church St. S.E., University of Minnesota, Minneapolis, Minnesota 55455, USA.

D. D. CAYWOOD, Department of Small Animal Clinical Sciences, College of Veterinary Medicine, University of Minnesota, St. Paul, Minnesota 55108, USA.

**Abstract:** Osteoarthrotic changes are described in the skeleton of an old wolf (*Canis lupus*) from Minnesota. Osteophyte formation appeared sufficient to restrict severely the range of motion of the joints. Despite this impairment the wolf ranged over 100 km<sup>2</sup> and killed a minimum of one or two adult white-tailed deer (*Odocoileus virginianus*) during a 6-week period between capture and death.

### INTRODUCTION

Osteoarthritis appears to be rare in wild canids,<sup>4</sup> and few cases have been reported in wolves.<sup>2,7,13</sup> Unlike dogs (*Canis familiaris*), in which this condition is common in older individuals,<sup>1,12</sup> wolves rarely reach an age at which the condition becomes significant. Mahan and Gipson<sup>8</sup> described a severely arthrotic 14-year-old coyote × dog hybrid from Nebraska. With one possible exception,<sup>7</sup> the literature contains no information on how wolves affected by degenerative joint disease may fare in the wild. In this report we describe the condition and behavior of an arthrotic wolf that was captured and radio-tracked in Minnesota.

### CASE HISTORY

During a field study of wolf ecology in Minnesota,<sup>5</sup> an adult male wolf was steel-trapped in Beltrami County on 19 July 1975. The wolf (#5157) was anesthetized, examined, weighed, measured, ear-tagged, blood-sampled, fitted with a radio-collar and released. No injury to the foot from the trap was detected. The animal was thin, weighing 33.5 kg ( $\bar{x}$  wt of six other adult males captured in the

study area was 38.3 kg); body measurements suggested he once weighed considerably more. Tooth wear and graying of the pelage suggested advanced age. Although subjectively judged to be in poor condition at capture, the wolf struggled a great deal in attempting to pull free of the trap.

After release, #5157 was located via a tracking aircraft on eight occasions: 23 and 29 July and 1, 4, 11, 15, 20, and 26 August. He was observed alone resting or sleeping on 4 of these dates. Unfortunately, he was not observed walking or running. The wolf was thought to be associated with a telemetered pack whose pups were located within 1 km of his capture site, although he was not located with them after being captured. The eight radio-fixes covered a minimum area<sup>11</sup> of 100 km<sup>2</sup>, which generally corresponded with the territory of that pack.

On 29 July, #5157 was located 2 km outside the known territory of his pack and was seen resting in a dry marsh within 3 m of a dead adult deer which he apparently had just killed but had not yet fed upon. No other wolves were observed at the location, and the other instrumented members of the pack were not in the area.

<sup>□</sup> Present address: North Central Experiment Station, University of Minnesota, Grand Rapids, Minnesota 55744, USA.

Therefore it appeared that #5157 had killed the deer alone. He was at the same location on 1 August, at which time the deer was virtually consumed. Examina-

tion of remains of this deer revealed it to be female, 12 years of age; age was based on cementum layers in roots of the incisors.<sup>6</sup>

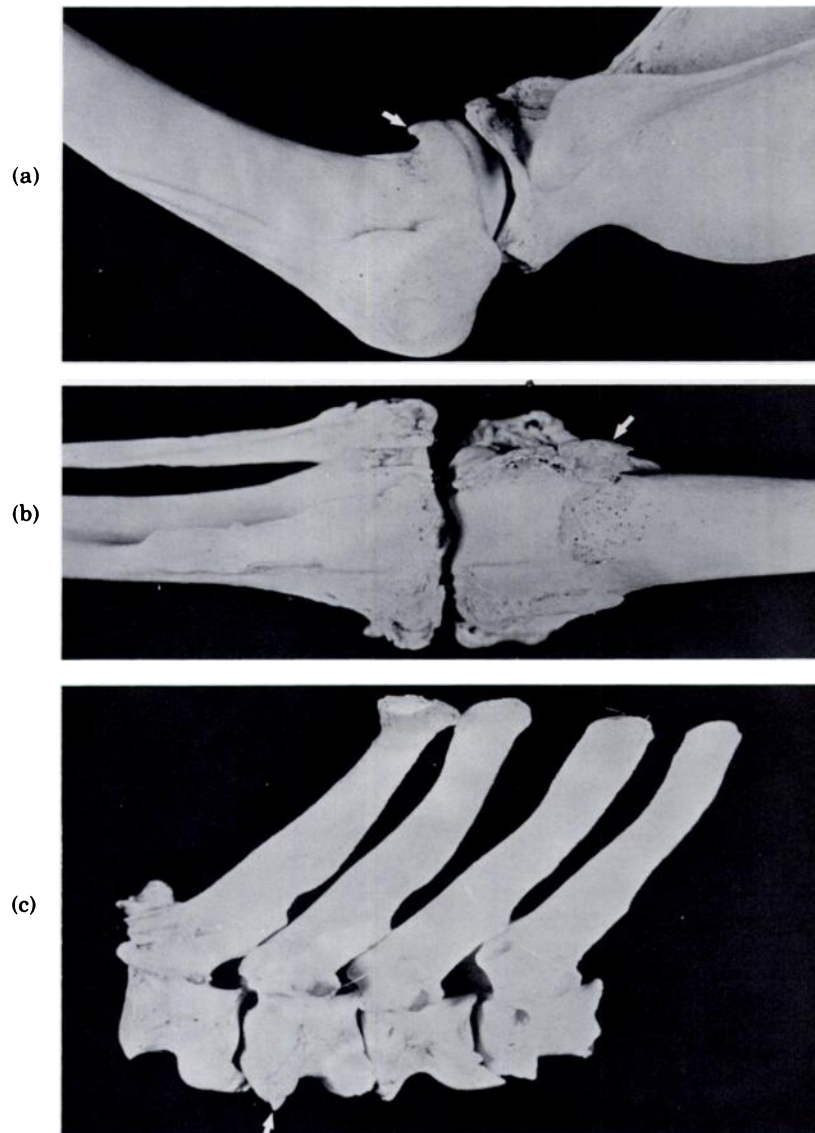


FIGURE 1 a-c. Osteophyte formation at various points on skeleton: (a) scapulohumoral joint, (b) stifle joint, (c) vertebrae.

After 26 August the radio signal became stationary at another location. On 4 September this site was checked from the ground, and the wolf was found dead. Also present were fresh remains of a 6-year-old male deer that appeared to have been eaten by a wolf (wolves?). The wolf's skeleton was not dismembered, but cause of death could not be determined because the carcass was decomposed.

Examination of #5157's skeleton revealed extensive periarticular osteophyte formation at the scapulo-humeral and stifle joints (Figs. 1a and 1b). Osteophytes were particularly prominent along the medial and lateral trochleae of the distal femora and the

margins of the medial and lateral condyles of the proximal tibiae. Osteophytes were evident on the ventral aspect of the 7th cervical, the 1st, and 5th-8th thoracic vertebrae (Fig. 1c). Although not complete, these lesions were progressing toward spondylosis. Osteophytes also were noted at the cranial and caudal articular processes of C7-T1. Unfortunately, it was impossible to determine the etiopathogenesis of the arthrotic changes from the skeleton.

Several traumatic bony lesions were present. Healed fractures were observed at the angle and midbody of 2 ribs and at the dorsal tip of the 4th thoracic vertebra (Fig. 2). A bony projection was evident at the medial angle of the right ischiatic

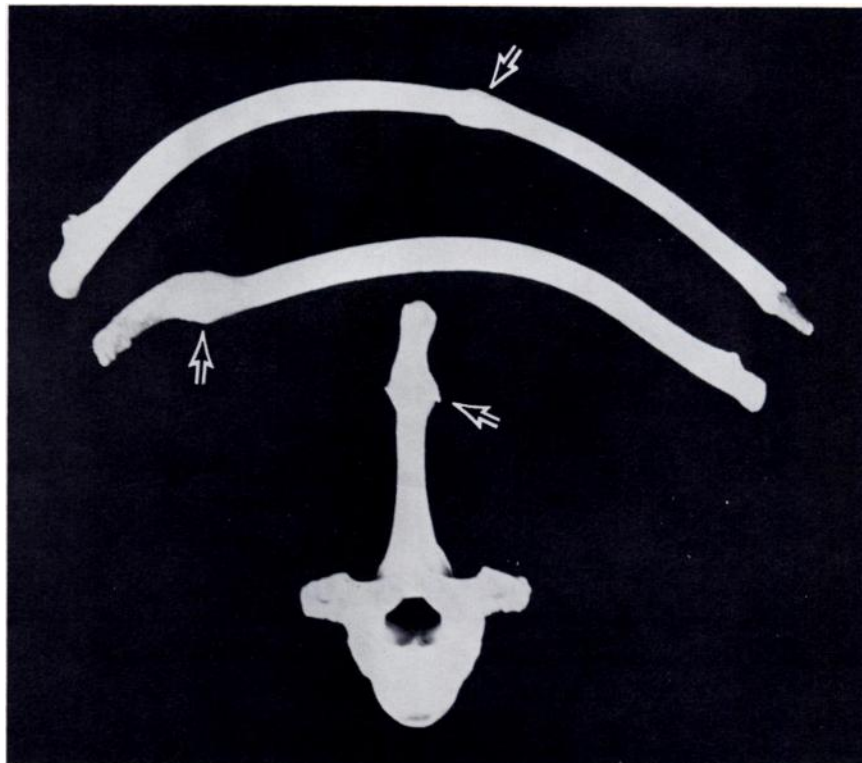


FIGURE 2. Healed fractures of 2 ribs and healed fracture at the dorsal tip of the 4th thoracic vertebra.

tuberosity near the origin of the semi-membranosus muscle (Fig. 3). This lesion appeared to be the result of a traumatic stretching or pulling of the periosteum at the muscle's origin.

The osteoarthrotic changes observed, particularly those involving the stifle, could have severely restricted the range of motion of the joints and reduced mobility and agility of the wolf. Considerable agility normally is necessary to capture prey and survive in the wild.<sup>9</sup> Therefore it is remarkable that the wolf was able to kill at least one and possibly two deer. Ages of the two deer involved are noteworthy. Deer over 6 years old are rare in northern Minnesota.<sup>3,10</sup>

The 12-year-old deer was the second oldest within a sample of 48 deer killed by

wolves in northwestern Minnesota.<sup>5</sup> Among 715 deer killed by hunters in that general part of the state in winter of 1974-75 and 1975-76, none were over 11.5 years. Therefore, it is likely that the extreme age of at least one of the two deer was a major factor in the wolf's being able to kill it.

The survival of #5157 to his age and condition at death is remarkable because wolves were heavily exploited by humans in that part of Minnesota until 1974. Longevity of this wolf implies considerable experience at hunting and killing deer and avoiding humans. That experience probably could partially compensate for the loss in mobility that must have accompanied his osteoarthrotic condition.

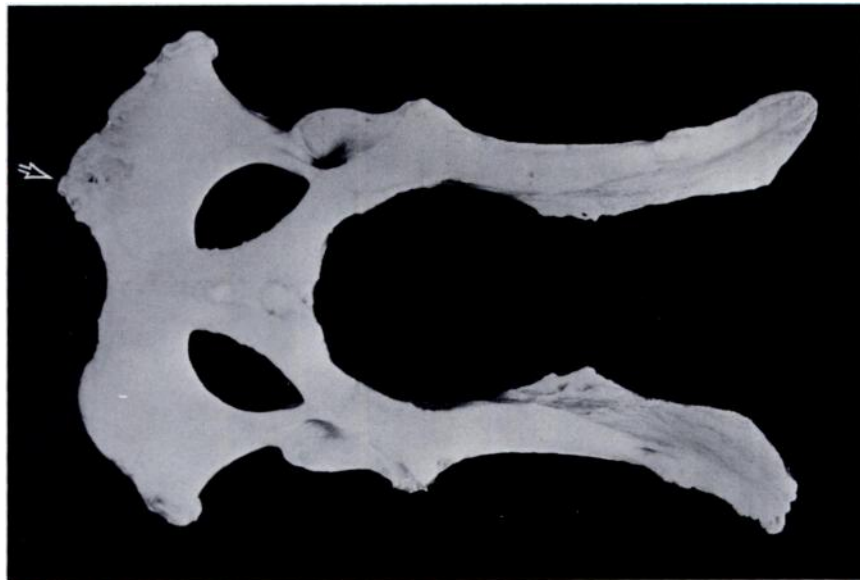

FIGURE 3. Bony projection at medial angle of the right ischiatic tuberosity.

#### Acknowledgements

We are grateful to P.D. Karns, Minnesota Department of Natural Resources, for aging the deer and to D.M. Barnes, E.C. Birney, and L.D. Mech for suggestions for improvement of the manuscript. Fieldwork was supported by the Special Projects Foundation of the Minneapolis Big Game Club.

**LITERATURE CITED**

1. BARRETT, R.E. 1977. Canine polyarthritis. *Current Vet. Ther.* 6: 890-897.
2. CROSS, E.C. 1940. Arthritis among wolves. *Can. Field-Nat.* 54: 2-4.
3. ERICKSON, A.B., V.E. GUNVALSON, M.H. STENLUND, D.W. BURCALOW and L.H. BLANKENSHIP. 1961. The white-tailed deer of Minnesota. Minnesota Dept. Conserv. Tech. Bull. 5. 64 pp.
4. FOX, H. 1939. Chronic arthritis in wild mammals. *Trans. Am. Phil. Soc.* 31: 73-124.
5. FRITTS, S.H. 1979. Dynamics, movements, and feeding ecology of a newly-protected wolf population in northwestern Minnesota. PhD thesis. Univ. of Minnesota, Minneapolis. 213 pp.
6. GILBERT, F.F. 1966. Aging white-tailed deer by annuli in the cementum of the first incisor. *J. Wildl. Manage.* 30: 200-202.
7. JORDAN, P.A., P.C. SHELTON and D.L. ALLEN. 1967. Numbers, turnover, and social structure of the Isle Royale wolf population. *Am. Zool.* 7: 233-252.
8. MAHAN, B.R. and P.S. GIPSON. 1978. Osteoarthritis in a coyote  $\times$  dog hybrid from Nebraska. *J. Wildl. Dis.* 9: 395-398.
9. MECH, L.D. 1970. *The Wolf: The Ecology and Behavior of an Endangered Species*. Doubleday. New York. 384 pp.
10. ——— and L.D. FRENZEL. 1971. Ecological studies of the timber wolf in north-eastern Minnesota. U.S. Dept. Agric. For. Serv. Res. Paper NC-52. 62 pp.
11. MOHR, C.O. 1947. Table of equivalent populations of North American small mammals. *Am. Midl. Nat.* 37: 223-249.
12. OLSSON, S. 1971. Degenerative joint disease (osteoarthritis): a review with special reference to the dog. *J. Sm. Anim. Pract.* 12: 333-342.
13. WOLFE, M.L. and D.L. ALLEN. 1973. Continued studies of the status, socialization, and relationships of Isle Royale wolves, 1967 to 1970. *J. Mammal.* 54: 611-635.

*Received for publication 27 August 1979*

---