



Trichophyton mentagrophytes DERMATOPHYTOSIS IN WILD FOX 1

Authors: KNUDTSON, WILLIAM U., GATES, CONNIE E., and RUTH, GEORGE K.

Source: Journal of Wildlife Diseases, 16(4) : 465-468

Published By: Wildlife Disease Association

URL: <https://doi.org/10.7589/0090-3558-16.4.465>

BioOne Complete (complete.BioOne.org) is a full-text database of 200 subscribed and open-access titles in the biological, ecological, and environmental sciences published by nonprofit societies, associations, museums, institutions, and presses.

Your use of this PDF, the BioOne Complete website, and all posted and associated content indicates your acceptance of BioOne's Terms of Use, available at www.bioone.org/terms-of-use.

Usage of BioOne Complete content is strictly limited to personal, educational, and non - commercial use. Commercial inquiries or rights and permissions requests should be directed to the individual publisher as copyright holder.

BioOne sees sustainable scholarly publishing as an inherently collaborative enterprise connecting authors, nonprofit publishers, academic institutions, research libraries, and research funders in the common goal of maximizing access to critical research.

Trichophyton mentagrophytes DERMATOPHYTOSIS IN WILD FOX [□]

WILLIAM U. KNUDTSON, [□] CONNIE E. GATES and GEORGE R. RUTH, [□] Animal Disease Research and Diagnostic Laboratory, South Dakota State University, Brookings, South Dakota 57007, USA.

LEANOR D. HALEY, Mycology Section, National Center for Disease Control, Atlanta, Georgia 30333, USA.

Abstract: Dermatitis caused by a zoophilic variant of *Trichophyton mentagrophytes* was diagnosed in a litter of eight captured wild red fox (*Vulpes fulva*). The animals had widespread partial alopecia and scattered crusty foci 2 to 3 cm in diameter on the skin.

Treatment with 7 mg/kg/body weight/day of griseofulvin in the feed effectively controlled the infection.

INTRODUCTION

Dermatophytoses are those infections of keratin tissues of man and animals caused by dermatophytes, a group of keratinophilic fungi. One species in the genus *Epidermophyton*, 15 in *Microsporum* and 21 in *Trichophyton* are recognized as dermatophytes.¹

The polymorphic dermatophyte *Trichophyton mentagrophytes* occurs world wide and has both anthropophilic and zoophilic forms. It has been cultured from humans and animals, with and without clinical signs of ringworm.⁹

Dermatophytes associated with ringworm in rearing foxes are *M. canis*,⁶ *T. mentagrophytes*,^{3,10} and *T. verrucosum*.¹⁰ Topical fungistats and griseofulvin have been used separately and in combination for treatment of dermatophytoses of rearing fox.^{3,6,10}

This report is an account of the diagnosis and treatment of a dermatophytosis in captured wild red fox (*Vulpes fulva*).

CASE HISTORY

Eight red fox were forced from their den, captured, and sold to a commercial

fur rearing ranch. At the time of capture each fox had alopecia of varying degrees and crusty accumulations on the paws. The animals were placed in separate cages and fed poultry scraps and commercial mink feed. Alopecia continued to develop over their entire bodies and extremities during the following 10 days at which time one of the animals was submitted to the South Dakota Animal Disease Research and Diagnostic Laboratory for examination.

Examination revealed an alert male red fox approximately 10 weeks old with widespread partial alopecia and scattered crusty foci, 2 to 3 cm in diameter on the skin. A skin biopsy in 10% formalin and skin scrapings from several areas of the body were submitted for laboratory examination.

LABORATORY RESULTS

Skin scrapings were digested in 10% KOH and examined microscopically. Chains of ectothrix arthrospores 2 to 4 μ m in diameter were present on the surface of the hairs. Septate branching hyphae 2 to 7 μ m wide were present on the hair shafts and in the skin scrapings.

[□] South Dakota Agriculture Experiment Station Journal Series No. 1679.

[□] Present address: Veterinary Medical Research Institute, Iowa State University, Ames, Iowa 50011, USA.

[□] Present address: Department of Pathobiology, School of Veterinary Medicine, University of Minnesota, St. Paul, Minnesota 55101, USA.

Mites were not found on microscopic examination.

Culture of the scrapings on Sabouraud's dextrose agar at 37 C yielded pure culture of a fast growing light tan granular mold that produced a deep reddish-brown reverse pigment.

Microscopic examination of portions of the mold thallus stained with lactophenol cotton blue revealed numerous globose microaleuriospores (2 to 4 μ m in diameter) in grape-like clusters; macroaleuriospores were not observed. Some of the branching septate hyphae were racquet shaped and others had a spiral arrangement. The fungus was identified as a zoophilic variant of *T. mentagrophytes*.

Microscopic examination of skin stained with H & E revealed large

amounts of laminated, keratinaceous debris on the surface. This material contained occasional large, sharply delineated, encapsulated aggregates of nuclear debris and numerous hair shafts. The fungus appeared as a layer of small (2 to 4 μ m), round, basophilic granules, 4 to 10 organisms thick in the keratin debris around the hair shafts. Organisms also lined the inner aspects of hair follicles in the dermis.

The epidermis was slightly acanthotic and had a few scattered poorly demarcated areas of necrosis. The exudate was composed primarily of PMNs and macrophages, some of which contained a single portion of a hairshaft.

Skin sections stained by the PAS technique had many round red staining bodies (2 to 4 μ m in diameter) in the

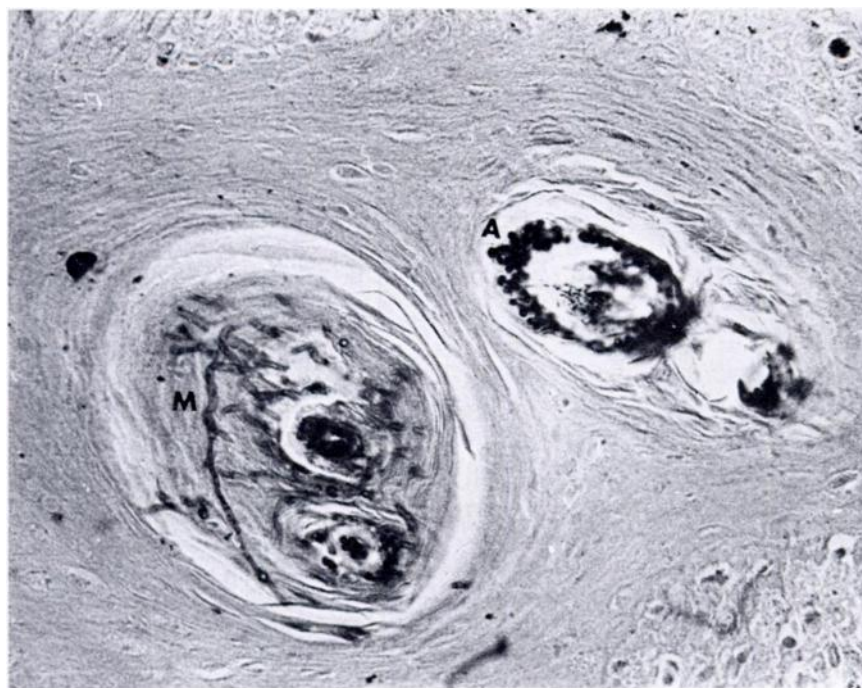


FIGURE 1. Portion of fox skin showing *Trichophyton mentagrophytes* ectothrix arthrospores (A) surrounding a hair shaft and branching septate mycelium (M) within a hair follicle. PAS \times 500.

superficial regions of the hair follicles and numerous branching septate hyphae (2 to 7 μ m wide) in the keratin and around and within the hair shafts. Hyphae also were present in the necrotic debris in the keratin layer (Fig. 1).

THERAPY

The foxes were placed in disinfected cages and treated with approximately 7 mg/kg body weight/day of griseofulvin[□] administered in the feed. Improvement was noted after 4 weeks of therapy. At 9 weeks of treatment some alopecia was still present but the owner elected to discontinue therapy. Clinical signs of dermatophytosis recurred within 2 weeks. Treatment was resumed and continued for an additional 12 weeks at which time the animals were killed and pelted. The market value of the pelts was reduced approximately 30% as a result of the infection.

DISCUSSION

The wild fox population in the United States does not appear to be a natural reservoir for dermatophytes. None were cultured from a total of 127 fox captured in Northwestern Florida,⁷ Southwestern Georgia^{7,8} and South Dakota.⁵ A survey of 16 wild fox from Rumania yielded 2 isolants of *T. mentagrophytes*; neither of the 2 foxes had clinical signs of

dermatophytosis.² The source of infection in these kits is unknown. The vixen is the most likely source either through direct contact or from contaminated material within the den. Small rodents are possible carriers, since they have been shown to harbor the fungus without showing clinical signs.⁸ It is doubtful that soil was a source of infection since *T. mentagrophytes* is not a geophilic fungus.¹

An interesting characteristic of the isolant of *T. mentagrophytes* described in this report was its very rapid growth at 37 C. Most strains and species of dermatophytes are inhibited at 37 C.⁹

Treatment of ringworm caused by *T. mentagrophytes* (2 cases and *T. verrucosum* (1 case) in rearing fox has been described.¹⁰ It was necessary to apply a topical fungistat along with griseofulvin to cause regression of lesions; griseofulvin alone was not effective. Formaldehyde (5%) and sodium iodide (1%) in combination were applied topically to successfully treat dermatophytosis caused by *M. canis* in fox kits.⁶

Dermatophytoses in fur animals appear to be chronic and in some instances recur when medication is stopped.⁴ In this case, clinical signs recurred approximately 2 weeks after griseofulvin was removed from the diet. When therapy was resumed the lesions again regressed.

Acknowledgements

The authors would like to acknowledge the assistance of Melva Mangan.

LITERATURE CITED

1. AJELLO, L. 1974. Natural history of the dermatophytes and related fungi. Mycopath. Mycol. Appl. 53: 93-110.
2. ALTERS, I., V. NESTEROV and I. CIOLOFAN. 1966. The occurrence of dermatophytes in wild animals from Rumania. Saboraudia. 4: 215-218.
3. FLATLA, J.L. 1939. Ringworm hos rev. Skand. Vet. Tidskry. 29: 753-780.

□ Fulvicin U/V (2.5 grams), Schering Corp., Kenilworth, New Jersey 07033, USA.

4. HAGEN, K.W. and J.R. GORHAM. 1972. Dermatomycoses in fur animals. *Vet. Med. Small Animal Clin.* 67: 43-48.
5. KNUDTSON, W.U. and G.W. ROBERTSTAD. 1970. The isolation of keratinophilic fungi from soil and wild animals in South Dakota. *Mycopath. Mycol. Appl.* 40: 309-323.
6. LEVENBERG, I.G. 1960. Microsporum infection in silver-gray foxes. *Trudy vesoyez Inst. Vet. Sanit.* 16: 379-382.
7. MCKEEVER, S., W. KAPLIN and L. AJELLO. 1958. Ringworm fungi of large wild mammals in Southwestern Georgia and Northwestern Florida. *Am. J. Vet. Res.* 19: 973-975.
8. MENGES, R.W., G.J. LOVE, W. W. Smith and L.K. GEORGE. 1957. Ringworm in wild animals in Southwestern Georgia. *Am. J. Vet. Res.* 18: 672-677.
9. RIPPON, J.W. 1974. *Medical Mycology: The Pathogenic Fungi and the Pathogenic Actinomycetes*. 1st ed. W.B. Saunders Co., Philadelphia, Pennsylvania.
10. WOLOSZYN, S., F. KAMYSZEK, J. ANDRYCHIEWICZ and W. KRUKOWSKI. 1973. Clinical manifestations and control of Trichophytosis in rearing fox. *Med. Weter.* 29: 73-77.

Received for publication 13 April 1977
