



## **BRAIN TUMORS IN TWO FREE-RANGING ELK IN COLORADO**

Authors: SNYDER, S.P., DAVIES, R.B., and STEVENS, D.

Source: Journal of Wildlife Diseases, 17(1) : 101-104

Published By: Wildlife Disease Association

URL: <https://doi.org/10.7589/0090-3558-17.1.101>

---

BioOne Complete ([complete.BioOne.org](https://complete.BioOne.org)) is a full-text database of 200 subscribed and open-access titles in the biological, ecological, and environmental sciences published by nonprofit societies, associations, museums, institutions, and presses.

Your use of this PDF, the BioOne Complete website, and all posted and associated content indicates your acceptance of BioOne's Terms of Use, available at [www.bioone.org/terms-of-use](https://www.bioone.org/terms-of-use).

Usage of BioOne Complete content is strictly limited to personal, educational, and non - commercial use. Commercial inquiries or rights and permissions requests should be directed to the individual publisher as copyright holder.

---

BioOne sees sustainable scholarly publishing as an inherently collaborative enterprise connecting authors, nonprofit publishers, academic institutions, research libraries, and research funders in the common goal of maximizing access to critical research.

## BRAIN TUMORS IN TWO FREE-RANGING ELK IN COLORADO

S.P. SNYDER,<sup>□</sup> R.B. DAVIES<sup>□</sup> and D. STEVENS<sup>□</sup>

**Abstract:** Primary brain tumors were diagnosed in two aged, free-ranging cow elk (*Cervus canadensis*) in Colorado. Both animals had been observed prior to their deaths in an incoordinate, emaciated state and were apparently blind. At necropsy, a large astrocytoma involving primarily the left pyriform lobe was found in one animal and a meningeal sarcoma involving the optic chiasma and adjacent ventral meningeal surface of the brain was noted in the other elk.

### INTRODUCTION

Spontaneous neoplasms in free-ranging American elk, (*Cervus canadensis*), have been recognized infrequently since 1951 when Drake described an osteosarcoma that had been mistakenly diagnosed as actinomycosis.<sup>4</sup> Since then, individual animals with osteosarcoma,<sup>2</sup> thyroid adenoma,<sup>1</sup> nephroblastoma<sup>10</sup> and myxosarcoma<sup>11</sup> have been reported. This report describes two spontaneous neoplasms discovered at necropsy of elk from Colorado.

### CASE REPORTS

**Case 1.** An adult cow elk, estimated by dentition to be more than 12 years old, was observed for several days wandering blindly in a hay field along the White River in northwestern Colorado. She was extremely weak, incoordinated and apparently blind. She became entangled in a fence, was captured and transported alive to Colorado State University for observation where she died 2 days later.

At necropsy, multiple cutaneous abrasions and hemorrhages were around the head and along the sides of the animal. Serous atrophy of fat replaced preeisting adipose tissue depots. Scattered infarcts were found in the left

ventricular myocardium and the lungs had verminous pneumonia. A poorly-delineated, plaque-like mass, approximately 4 cm in diameter and 2 cm thick, occupied an area around the optic chiasma and adjacent meningeal and nervous tissue, sparing the infundibular stalk and pituitary gland. The mass was irregular in outline, pink to red-brown and infiltrated the neuropil in the region of the hypothalamus. On microscopic examination the mass consisted chiefly of fusiform cells with indistinct margins arranged in broad sheets and whorls interrupted by foci of necrosis which contained calcified debris (Fig. 1). The calcific deposits were rarely in typical psammoma body arrangement; more often they were simply foci of dystrophic calcification in areas of ischemic necrosis. Nuclei of tumor cells were oval to elongate and contained one to several small dark nucleoli. Mitotic activity was moderate. Invasion had occurred laterally in the subarachnoid space and dorsally into the neuropil, causing displacement and necrosis of neural elements. The tumor was diagnosed as a meningeal sarcoma based on location and microscopic features.<sup>3,8</sup>

**Case 2.** A visitor to the Rocky Mountain National Park in north-central Colorado was able to approach a cow elk

<sup>□</sup> Wild Animal Disease Center, Department of Pathology, College of Veterinary Medicine and Biomedical Sciences, Colorado State University, Fort Collins, Colorado 80523, USA.

<sup>□</sup> National Park Service, Rocky Mountain National Park, Estes Park, Colorado 80517 USA.

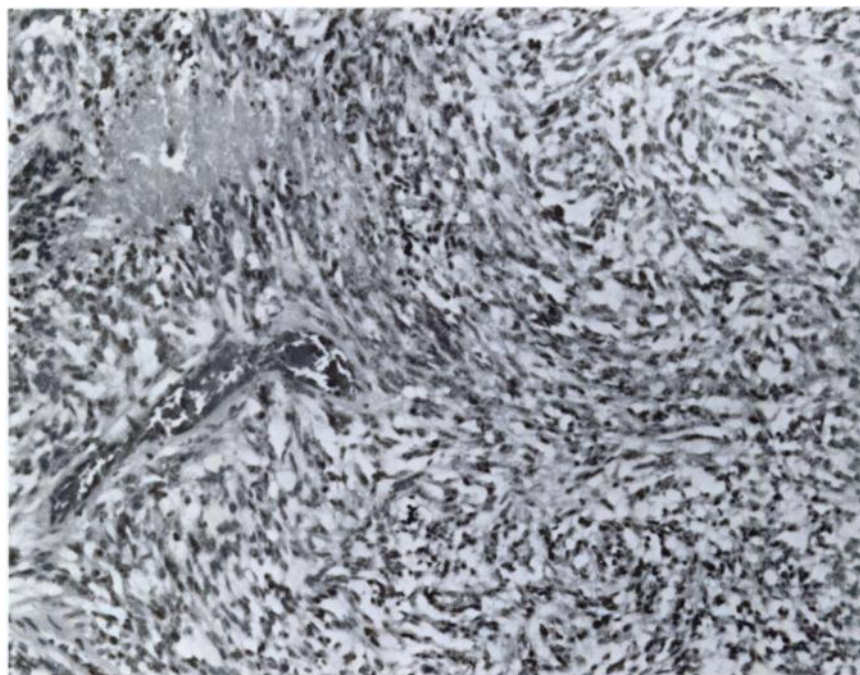


FIGURE 1. Photomicrograph of elk meningeal sarcoma composed of fusiform cells and containing a focus of necrosis. H&E, x320.

without disturbing her. The animal responded to loud noise, however, and began to circle in a counterclockwise fashion, running into several trees. The visitor notified park personnel (D.S.) who observed the animal to be emaciated, incoordinated and apparently blind. The animal was killed and the head was submitted to the Wild Animal Disease Center for examination.

Lacerations and abrasions in various stages of healing were around the eyes and on the tongue, dental pad and gums. Dentition and tooth wear were typical of an elk 12-14 years of age. The left side of the brain was swollen and the right side compressed. A soft gray to brown mass measuring 7×5×5 cm occupied the area of the left pyriform lobe and bulged ventrally onto the meningeal surface just posterior to the optic chiasma. Compression altered the shape and size of all

structures of the left cerebrum and displaced the brainstem and cerebellum to the right. On cut surface soft brown to red foci were scattered through the mass (Fig. 2).

Microscopically the tumor was composed largely of loosely-arranged fusiform and stellate cells with small round to oval nuclei (Fig. 3). Few mitotic figures were noted. Scattered, variable-sized foci of hemorrhage were found throughout the mass. Contiguous nervous tissue was obviously compressed and distorted by the expanding mass, but there was no evidence of invasion by the tumor. Isolated areas of necrosis and edema, usually along the tumor-neuropil interface, were noted. A differentiated protoplasmic astrocytoma was diagnosed on the basis of location and histologic features.<sup>3,8</sup>

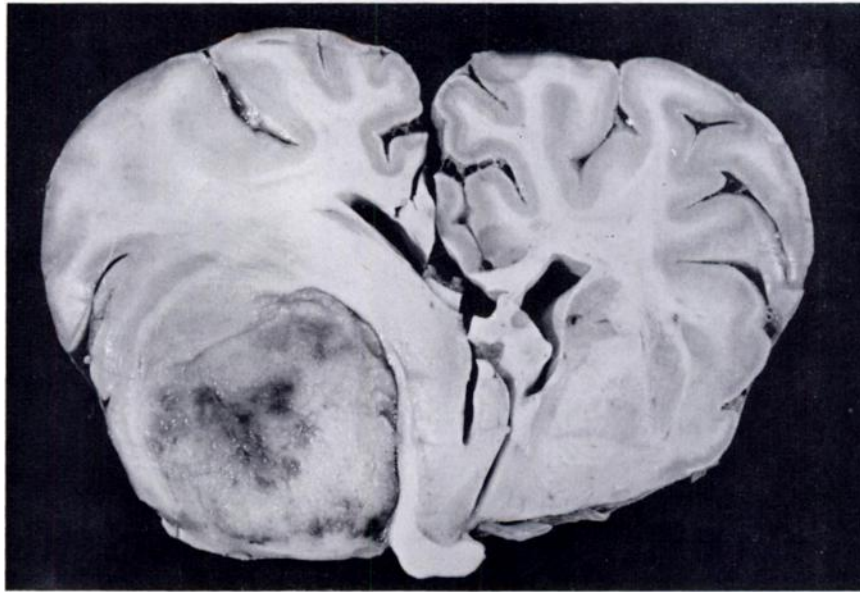


FIGURE 2. Large astrocytoma of left pyriform lobe of elk's brain.

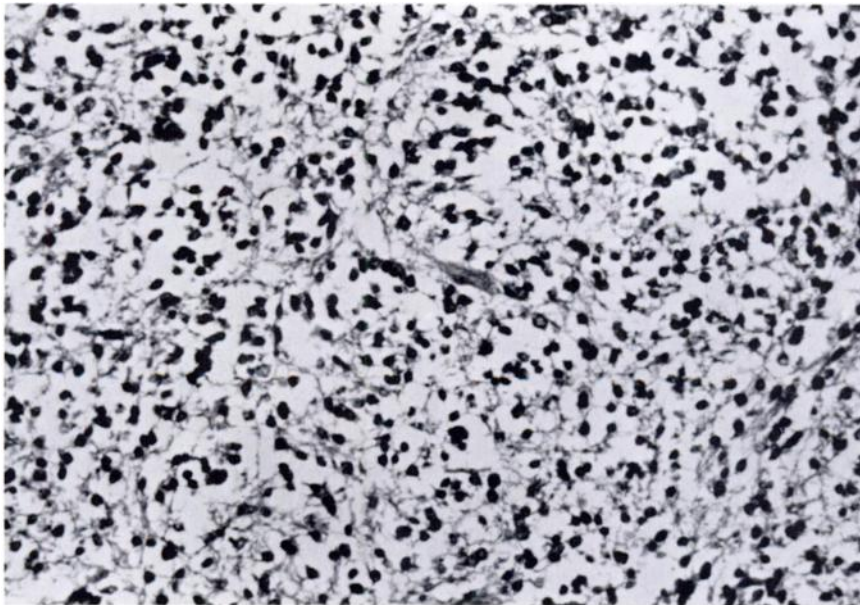


FIGURE 3. Photomicrograph of elk astrocytoma composed of loosely-arranged spindled and stellate cells. H&E, x360.

## DISCUSSION

Both animals had been observed prior to their deaths in an incoordinate, emaciated state and were apparently blind. The blindness in Case 1 was attributable to extensive local destruction of the optic nerves, chiasma and tracts. In Case 2, the blindness was more difficult to explain but is assumed to be due

to compression of the left optic tract, as indicated in figure 2.

Both elk were aged, as is the case of primary brain tumors in other species.<sup>3</sup> A variety of neurectodermal tumors have been described in deer,<sup>5-7,9</sup> but to our knowledge this is the first report of similar neoplasms in elk.

## LITERATURE CITED

1. BOYD, R.J. 1970. Elk of the White River Plateau, Colorado. Tech. Publ. No. 25, Col. Div. Game, Fish and Parks, pp. 14-15.
2. CLARK, K.A. 1973. Neoplasms of wild animals. *Southwest Vet.* 26: 185-188.
3. CORDY, D.R. 1978. Tumors of the nervous system and eye. In: *Tumors of Domestic Animals*, 2nd ed., rev. J.E. Moulton, ed., Berkeley, Univ. Calif. Press, pp. 430-455.
4. DRAKE, C.H. 1951. Mistaken diagnosis of actinomycosis for osteogenic sarcoma in an American elk (*Cervus canadensis*). *J. Wildl. Manage.* 15: 284-287.
5. HOLSCHER, M.A., D.L. PAGE, H.S. POWELL and C.E. KORD. 1974. Mixed primitive neurectodermal and rhabdomyoblastic tumor in the brain of a wild deer. *J. Wildl. Dis.* 10: 301.
6. ———, ———, M.G. NETSKY and H.S. POWELL. 1977. Mixed glioma and rhabdomyosarcoma in the brain of a wild deer. *Vet. Path.* 14: 643-647.
7. KRADEL, D.C. and H.W. DUNNE. 1965. Brain tumors (ependymomas) in deer. *J. Am. vet. med. Ass.* 147: 1096-1098.
8. LUGINBUHL, H., R. FANKHAUSER and J.T. MCGRATH. 1968. Spontaneous neoplasms of the nervous system in animals. *Prog. Neurol. Surg.* 2: 85-164.
9. NETTLES, V.F. and M. VANDEVELDE. 1978. Thalamic ependymoma in a white-tailed deer. *Vet. Path.* 15: 133-135.
10. SNYDER, S.P., R.B. DAVIES, T.R. SPRAKER and H. BROWNING. 1979. Embryonal nephroma in a wapiti. *J. Wildl. Dis.* 15: 303-306.
11. ———, ——— and R.E. Keiss. 1979. Myxosarcoma in a wapiti. *J. Wildl. Dis.* 15: 307-308.

*Received for publication 20 August 1979*