

Mycobacterium marinum INFECTION IN BUFONIDAE 1

Authors: SHIVELY, JAMES N., SONGER, J. GLENN, PRCHAL, STEVE, KEASEY, MERRIT S., and THOEN, CHARLES O.

Source: Journal of Wildlife Diseases, 17(1) : 3-7

Published By: Wildlife Disease Association

URL: <https://doi.org/10.7589/0090-3558-17.1.3>

BioOne Complete (complete.BioOne.org) is a full-text database of 200 subscribed and open-access titles in the biological, ecological, and environmental sciences published by nonprofit societies, associations, museums, institutions, and presses.

Your use of this PDF, the BioOne Complete website, and all posted and associated content indicates your acceptance of BioOne's Terms of Use, available at www.bioone.org/terms-of-use.

Usage of BioOne Complete content is strictly limited to personal, educational, and non - commercial use. Commercial inquiries or rights and permissions requests should be directed to the individual publisher as copyright holder.

BioOne sees sustainable scholarly publishing as an inherently collaborative enterprise connecting authors, nonprofit publishers, academic institutions, research libraries, and research funders in the common goal of maximizing access to critical research.

Mycobacterium marinum INFECTION IN BUFONIDAE¹

JAMES N. SHIVELY,² J. GLENN SONGER,² STEVE PRCHAL,² MERRIT S. KEASEY III² and CHARLES O. THOEN³

Abstract: *Mycobacterium marinum* was isolated from lesions of two Bufonidae. Microscopic examination of tissues collected at necropsy of six Bufonidae revealed lesions containing acid-fast bacteria in the liver, lung, kidney, intestine and skin. Acid-fast bacteria occurred in alveoli and airways of lung and in lumen of intestine. Isolates obtained on mycobacteriologic examination were identified by tests for photochromogenicity, nitrate reduction and by seroagglutination tests.

INTRODUCTION

Mycobacterium marinum was first isolated from various tissues of diseased tropical coral fish and from aquaria in 1926.¹ Since then it has been reported as a cause of disease in several cold-blooded species^{7,14,15} and in humans.^{3,6,8}

Mycobacterium marinum is a long, beaded, acid-fast rod. Small rough colonies appear on solid media in about seven days at 30 C. Growth usually does not occur at 37 C.¹² The size of the organism *in vivo* has been noted to vary with the size of the host cells. *M. marinum* is frequently characterized by resistance to antibiotics commonly used for treatment of other mycobacterial infections.¹³

Mycobacterial infections are common in fish, amphibians and snakes, but infection of turtles is less frequent.⁹ Pulmonary disease occurs most frequently in turtles while visceral and cutaneous involvement is most common in snakes, lizards, crocodilians and amphibians.¹⁶ Mycobacteriosis among commercially important fishes is a significant problem and probably results in considerable mortality at sea.^{2,10}

Apparently the only report of mycobacterial infection in Bufonidae resulted from finding acid-fast bacilli in visceral and cutaneous lesions of 3 of 600 *Bufo spinulosum* examined in Bolivia.⁴ The organism was not isolated from these toads.

This describes an occurrence of *Mycobacterium marinum* infection in Bufonidae.

MATERIALS AND METHODS

Over a period of about 3 weeks, three *Bufo cognatus* and one *Bufo woodhousei* were received for diagnostic necropsy. The original complaint was that several toads had died during the few months preceding the submissions. Later, two toads having visible localized subcutaneous swelling were obtained. Samples of feed and water from the enclosure were collected for culture.

Tissue samples from visceral organs, brain, skin and muscle were fixed in buffered 10% formaldehyde or in a mixture of 4% commercial formaldehyde and 1% glutaraldehyde in phosphate buffer.⁵ For light microscopy, tissues were

¹ Arizona Journal Article No. 3017 from the Arizona Agricultural Station, University of Arizona, Tucson, Arizona 85721, USA.

² Department of Veterinary Science, University of Arizona, Tucson, Arizona 85721, USA.

³ Arizona Sonora Desert Museum, Tucson, Arizona.

⁴ Department of Veterinary Microbiology and Preventive Medicine, Iowa State University, Ames, Iowa 50010, USA.

embedded in paraffin and sections 5 μ m thick were cut and stained with hematoxylin and eosin, McCallam-Goodpasture Gram, and Kinyoun's acid-fast stains. For transmission electron microscopy, tissues were post-fixed in 2% osmium tetroxide in phosphate buffer and embedded in an epon-araldite mixture; silver to light gold sections were cut and stained with uranyl acetate and lead citrate.

Pooled tissues from the first toads were cultured on blood agar and MacConkey's agar.^[5] After morphologic changes in tissue were known, cultures to isolate mycobacteria were made. Tissues were mixed with 50 ml phenol red broth base^[5] and ground in a blender for 2 min. Five ml of the resulting suspension was added to 5 ml of 0.5N NaOH. The mixture was acidified with 6N HCl, neutralized with 1N NaOH, and centrifuged at 1650 RCF for 30 min. The supernatant fluid was discarded and cotton-tipped swabs were used to inoculate the sediment onto plates of Middlebrook's 7H10 agar with OADC enrichment.^[5] Plates were incubated aerobically at 30 C. Colonies typical of *M. marinum* were identified by routine methods.¹¹ Food and water samples were processed in a similar manner.

RESULTS

Mycobacterium marinum was isolated from tissues of 2 of 3 toads. Samples of feed and water did not yield isolates of *M. marinum*.

At necropsy, firm, raised, whitish areas, approximately 1 cm in diameter and involving skin and underlying tissue were seen in 4 (all *B. cognatus*) of 6 toads. Only one such lesion occurred in each toad and of these lesions one was about 1 cm dorsal and posterior to the right eye, one was in the left metatarsal area, one was in the right flank, and one was in the

region of the right gastrocnemius muscle. Two toads had a few slightly reddish 2 to 5 mm areas in skin. Four toads had 1 to 6 whitish-yellow, 1 to 4 mm foci in various loci in the liver. A dark red lesion occupied the anterior quarter of the right lung and the liver was yellowish in one toad.

In addition to the white nodules in liver seen at necropsy, microscopic examination revealed morphologic changes in many organs. These varied from collections of a few macrophages, in or around which acid-fast bacilli were sometimes found, to well-developed granulomas (Fig. 1). The center of some of these granulomas contained pink-staining homogeneous material, necrotic cells, and cell debris. In others, the pink-staining material did not occur, but there were cells in various stages of degeneration. A zone of epithelioid cells, sometimes including multinucleated giant cells, surrounded the central area. Around this was a fibrous capsule containing various numbers of macrophages. A few to many extracellular acid-fast staining bacteria were in the central part of granulomas and occasionally were near the periphery. Sometimes masses of these bacteria were in macrophages.

The sites of occurrence of granulomas are in Table 1. Granulomas in intestine were in epithelium, in lamina propria, and in muscle coats. Mural thrombi were in veins at the intestinal serosa of one toad. Acid-fast bacilli were in debris in the intestinal lumen, in granulomas, and in the thrombi. Necrotic cells and fibrinocellular exudate containing extracellular acid-fast bacteria were in lung airways. Also, there were masses of apparently viable macrophages in which many acid-fast bacteria occurred. Occasionally, acid-fast bacteria without apparent relation to granulomas or macrophages were in interalveolar septae.

^[5] Difco Laboratories, Detroit, Michigan 48232, USA.

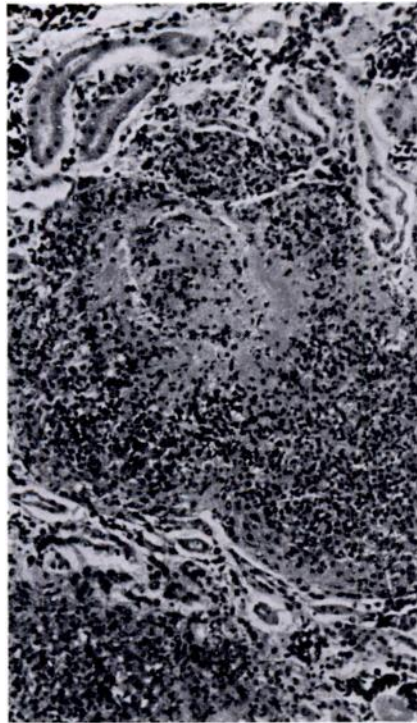


FIGURE 1. Granuloma in kidney. H&E.

Subcellularly, mycobacteria occurred in degenerate masses of cytoplasm, in vacuoles resembling phagosomes which sometimes also contained organelles in various stages of degeneration, and occasionally in unaltered cytoplasm. Sometimes bacteria were in the cytoplasm of necrotic cells. Many bacteria contained lipid droplets.

DISCUSSION

This apparently is the first report of isolation and identification of *M. marinum* from Bufonidae. These cases supplement the earlier report⁴ of probable *M. marinum* infection in Bufonidae and should emphasize the potential of this microorganism for producing disease in confined populations of these and other amphibians.

Unfortunately, the prevalence of infection in this group of toads is not known.

Mycobacterium marinum was isolated from organs of these infected toads. Availability of newer media may account for the difference from the earlier study⁴ in which isolation was not successful. However, utilization of these media did not result in isolation of the organism from feed and water.

Gross and microscopic characteristics of lesions in these toads were essentially like those described in frogs.⁴ Apparent skin lesions were "tumor-like," but were not ulcerated as in frogs. Liver granulomas were visible at necropsy in 4 of the 6 toads, and granulomas were detected microscopically in another toad. Granulomas were not found in the liver of one toad in which there were no visible changes in visceral organs at necropsy. However, in this toad, microscopic study revealed tiny granulomas in heart and fat body and confirmed that swelling in the metatarsal area included granulomatous response to mycobacterial infection. Lung lesions, in the single toad in which they occurred, were somewhat more extensive than those described in frogs.

Occurrence of mycobacteria in alveoli and airways likely provides a means for dissemination. Origin of the acid-fast bacteria in intestinal lumen is uncertain: they could have been moved up the respiratory tree and been swallowed, or

TABLE 1. Site of occurrence of granulomas.

| | |
|-------------------|------|
| Skin and muscle** | 4/4* |
| Heart | 2/6 |
| Lung | 1/6 |
| Liver | 5/6 |
| Kidney | 1/6 |
| Spleen | 1/6 |
| Intestine | 2/4 |
| Fat body | 2/4 |
| Brain | 1/2 |
| Eye | 1/2 |

*No. having granulomas/no. examined

**Toads having visible nodules

the bacteria may have come from the granulomas in intestinal epithelium. Whatever origin, their presence may provide a means for dissemination even though mycobacteria were not cultured from water and sediment from the enclosure. Because the organism has been shown to produce disease in humans^{3,6,8} these potential routes of elimination could provide for contamination of the environment and a potential hazard to those involved in their care.

Acknowledgement

The technical assistance of Helen Thompson is gratefully acknowledged.

LITERATURE CITED

1. ARONSON, J.D. 1926. Spontaneous tuberculosis in salt water fish. *J. Infect. Dis.* 39: 315-320.
2. CONROY, D.A. 1970. Piscine tuberculosis in the sea water environment. Pages 273-278. In: *A Symposium on the Diseases of Fishes and Shellfishes*. S.F. Snieszko, ed. Spec. Publ. No. 5. Washington D.C. Am. Fish. Soc. 526 pp.
3. LINELL, F. and A. NORDEN. 1954. *Mycobacterium balnei*, a new acid-fast bacillus occurring in swimming pools and capable of producing skin lesions in humans. *Acta Tuberc. Scand. Suppl.* 1: 1-84.
4. MICHICAO, N. and E. LAPLACA. 1954. Lepralike granulomas in frogs. *Lab. Invest.* 3: 219-227.
5. MCDOWELL, E.M. and B.F. TRUMP. 1976. Histologic fixatives suitable for diagnostic light and electron microscopy. *Arch. Pathol. Lab. Med.* 100: 405-414.
6. MOLLOHAN, C.S. and M.S. ROMER. 1961. Public health significance of swimming pool granuloma. *Am. J. Public Health.* 51: 883-891.
7. NIGRELLI, R.F. and H. VOGEL. 1963. Spontaneous tuberculosis in fishes and in other cold-blooded vertebrates with special reference to *Mycobacterium fortuitum* Cruz from fish and human lesions. *Zoologica.* 48: 131-144.
8. REES, R.B. and J.H. BENNETT. 1953. Granuloma following swimming pool abrasion. *J. Am. Med. Ass.* 152: 1606-1610.
9. RHODIN, A.G.J. and M.R. ANVER. 1972. Mycobacteriosis in turtles: cutaneous and hepatosplenic involvement in a *Rhrynops hilari*. *J. Wildl. Dis.* 13: 180-183.
10. ROSS, A.J. 1970. Mycobacteriosis among Pacific salmonid fishes. Pages 279-283. In: *A Symposium on the Diseases of Fishes and Shellfishes*. S.F. Snieszko, ed. Spec. Publ. No. 5. Washington, D.C.: Am. Fish. Soc. 526 pp.
11. RUNYON, E.H., A.G. KARLSON, G.P. KUBICA and L.G. WAYNE. 1974. *Mycobacterium*. Pages 148-174. In: *Manual of Clinical Microbiology*, 2nd ed. E.H. Lennette, E.H. Spaulding, and J.P. Truant, eds. Washington, D.C. Am. Soc. Microbiol. 970 pp.
12. ———, L.G. WAYNE and G.P. KUBICA. 1974. *Mycobacteriaceae*. Pages 681-701. In: *Bergey's Manual of Determinative Bacteriology*, 8th Ed. R.E. Buchanan and N.E. Gibbons, eds. Baltimore, Williams and Wilkins. 1268 p.
13. VAN DUIJN, C. 1973. *Diseases of Fishes*. London: Iliffe Books. Pp. 190-191.
14. VOGEL, H. 1956. Metabolic and serologic study of acid-fast bacteria from fishes and other cold-blooded vertebrates. Doctoral Dissertation, Dept. of Biology, N.Y. Univ. Graduate Sch. of Arts and Sci.

15. ———. 1958. Mycobacteria from cold-blood animals. *Am. Rev. Tuberculosis*. 77: 823-838.
16. WALLACH, J.D. 1968. Diseases of reptiles and their clinical management. Pages 433-439. In: *Current Veterinary Therapy IV*. R.W. Kirk, ed. Philadelphia, W.B. Saunders. 830 p.

Received for publication 13 July 1979
