

THE NORWAY RAT AS A SELECTIVE CHRONIC CARRIER OF *Leptospira icterohaemorrhagiae* 1

Author: THIERMANN, ALEJANDRO B.

Source: Journal of Wildlife Diseases, 17(1) : 39-43

Published By: Wildlife Disease Association

URL: <https://doi.org/10.7589/0090-3558-17.1.39>

BioOne Complete (complete.BioOne.org) is a full-text database of 200 subscribed and open-access titles in the biological, ecological, and environmental sciences published by nonprofit societies, associations, museums, institutions, and presses.

Your use of this PDF, the BioOne Complete website, and all posted and associated content indicates your acceptance of BioOne's Terms of Use, available at www.bioone.org/terms-of-use.

Usage of BioOne Complete content is strictly limited to personal, educational, and non - commercial use. Commercial inquiries or rights and permissions requests should be directed to the individual publisher as copyright holder.

BioOne sees sustainable scholarly publishing as an inherently collaborative enterprise connecting authors, nonprofit publishers, academic institutions, research libraries, and research funders in the common goal of maximizing access to critical research.

THE NORWAY RAT AS A SELECTIVE CHRONIC CARRIER OF *Leptospira icterohaemorrhagiae*[□]

ALEJANDRO B. THIERMANN, National Animal Disease Center, Agricultural Research, Science and Education Administration, U.S. Department of Agriculture, Ames, Iowa 50010, USA.

Abstract: Laboratory raised wild Norway rat males (*Rattus norvegicus*) were injected with leptospires of two serovars: *icterohaemorrhagiae* and *grippityphosa*. The development of a carrier state was monitored serologically, culturally and histologically. Rats infected with *icterohaemorrhagiae* developed rapidly into a chronic carrier state and shed leptospires in the urine for the duration of the experiment (220 days). At the time of necropsy, histopathologic studies showed evidence of leptospiral infections in the lumen of proximal convoluted tubules of some kidneys.

Rats infected with *grippityphosa* shed organisms for 40 days after inoculation; thereafter, they apparently cleared the infection. No organisms were detected histologically nor by culture at the end of the experiment (220 days). There appears to be a specific host-parasite relationship in the Norway rat towards becoming chronic carriers when infected with serotype *icterohaemorrhagiae* but not with *grippityphosa*.

INTRODUCTION

A true leptospiral carrier is the host which, after suffering from an infection by leptospires with or without the manifestation of clinical signs, has developed renal infection and sheds organisms in urine. This condition remains for a long period of time, possibly for the remainder of the animal's life. Our knowledge of these chronic carriers is not yet complete, but it seems to represent a high degree of host-parasite adaptation. In their natural habitat, certain species of animals in a given locality are invariably found to carry the same leptospiral serotype.⁷ This concept of host election was already described by Uhlenhuth in 1943,¹³ and later by Alston and Broom¹ and Babudieri² in 1958. Studies by Faine⁸ show that the age or immunocompetence of the host constitutes an important factor in the development of a chronic

carrier state. He also found the size and virulence of the inoculum to be determinant factors. Tabel and Karstad¹² determined that the outcome of the carrier state of leptospiral infection in animals is determined by a qualitative suitability of the infected animal and the susceptibility and defense mechanism of the host. Soon after the infection is established, the epithelium of the renal convoluted tubules apparently becomes resistant to reinvasion by the leptospires present in the lumen.⁸

The Norway rat (*Rattus norvegicus*) is known worldwide as a successful chronic carrier of serovar *icterohaemorrhagiae*, although it has been found occasionally to carry other serovars such as *ballum* and *autumnalis*. It was the intent of this study to investigate and compare the role of the Norway rat as a chronic carrier of two leptospiral serovars: *icterohaemorrhagiae* and *grippityphosa*.

[□] Research conducted at the Department of Comparative Medicine, School of Medicine, Wayne State University, Detroit, Michigan.

MATERIALS AND METHODS

Animal host. Fourth generation laboratory raised wild Norway rats were used for this study. Three groups, each consisting of four healthy young adult males, and each weighing approximately 300 g, were selected. Prior to the initiation of this study, each animal was tested and proven negative to leptospiral infection using cultural and serological methodology.

Inoculum. Three wild leptospiral isolants were selected for experimental inoculations. All isolants were propagated in Ellinghausen-McCullough (E-M) semisolid medium.⁵ Prior to inoculation, the organisms were transferred and adapted to E-M liquid medium. Proper quantification was obtained using nephelometry⁶ and Petroff-Hauser cell counting chambers. Following appropriate dilutions, each animal received an intraperitoneal inoculation of one ml of E-M liquid medium containing 2×10^7 organisms.

Group A received *icterohaemorrhagiae* strain 549K initially obtained from wild rat kidney (*Rattus norvegicus*). Group B received *icterohaemorrhagiae* strain 538Br initially obtained from wild rat brain (*Rattus norvegicus*). Group C received *grippotyphosa* strain SQ34 initially obtained from fox squirrel kidney (*Sciurus niger*).

Serologic methods. Blood samples were routinely collected from each rat by using heparinized microhematocrit capillary tubes in the retroorbital plexus.¹¹ One ml of blood was placed into a 5 ml vacutainer tube. After clotting, the serum was separated by centrifugation. The serum samples were stored at -80 C until tested.

The microscopic agglutination test using live antigens was used as described by Galton *et al.*⁹ and modified by Cole *et al.*³ Serum samples were also mixed with equal volumes of a 0.2 M 2-mercaptoethanol solution and incubated at 37 C for 24 h prior to the microscopic agglutination test.⁴ The serologic

responses were then interpreted within each group as to their content of 2-mercaptoethanol resistant antibodies.

Processing of urine. Periodic urine samples were collected from each rat by placing them in a metabolic cage with especially designed metal funnels attached to the bottom of each cage. The fecal material was separated by a wire mesh, the urine fell through and was then filtered through a Whatman #1 filter paper prior to being stored in a glass jar. Immediately after collecting the urine samples, urine was examined under darkfield microscopy for the presence of motile leptospire. Samples were then diluted into a 1% BSA-phosphate buffered solution (10^{-1} through 10^{-4}). One ml aliquots were then transferred to 10 ml tubes of E-M semisolid medium containing 100 mg of 5-fluorouracil per ml and incubated at 29 C for 60 days.

Cultural isolation. At the termination of the experiment, 220 days after inoculation, the rats were euthanized in a CO₂ chamber and tissues were collected for culture isolation. Blood, urine, kidney, liver and brain were collected aseptically and suspended into 1% BSA transport medium. From here 1 ml aliquots were transferred into E-M semisolid medium and incubated at 29 C for 60 days. Leptospiral growth was monitored weekly using darkfield microscopy.

Histologic methods. At the time of necropsy, the left kidney of each rat was removed and sectioned in half. The kidneys were then fixed in 10% buffered formalin. Sections of each kidney were silver impregnated¹⁰ and observed with the aid of light microscopy for leptospire.

RESULTS

During the entire course of the experiment, no clinical signs of illness were observed in any of the rats.

Serologic response. The results of the specific agglutinating antibody

responses to the homologous leptospiral serovar and the 2-mercaptoethanol resistant titres for each group of rats are indicated in Figure 1. All animals rapidly developed a high titer antibody response

which persisted for the duration of the experiment in the rats infected with *icterohaemorrhagiae*. However, the animals in group C, infected with *grippytyphosa*, had a rapid decrease in

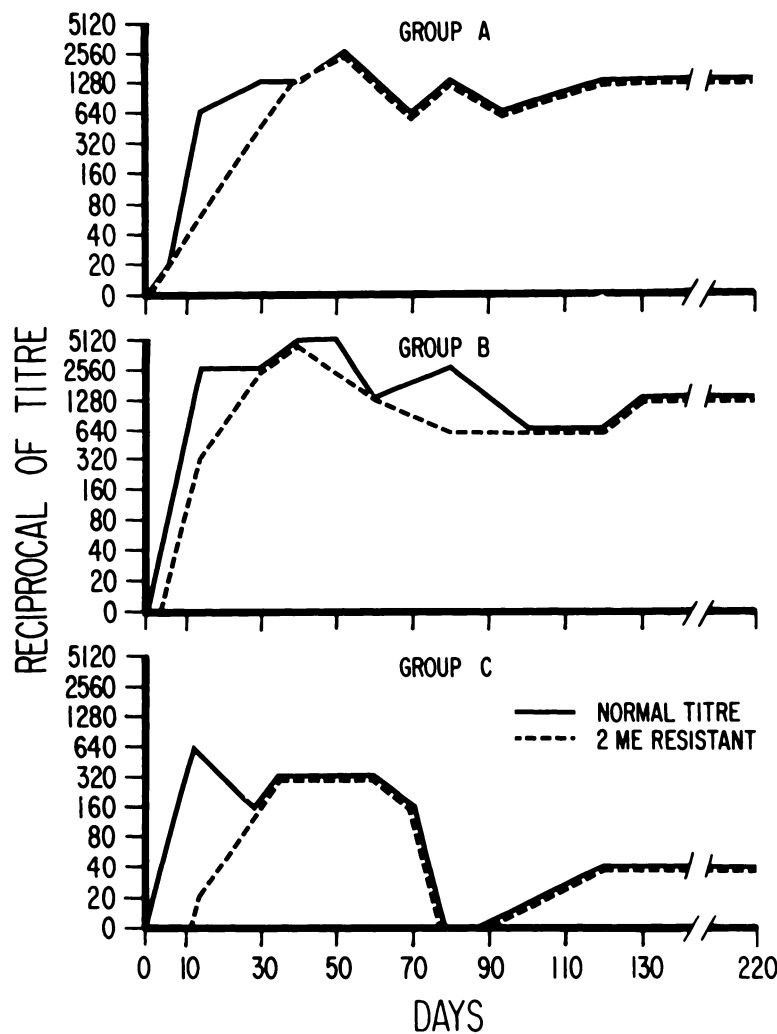


FIGURE 1. Antibody responses of wild Norway rats challenged with 2×10^7 pathogenic leptospirae. Group A received *icterohaemorrhagiae* strain 549K, group B received *icterohaemorrhagiae* strain 538 Br, and group C received *grippytyphosa* strain Sq 34. Solid line corresponds to standard M/A titres, dotted line indicates 2-mercaptoethanol resistant titres.

titre after 60 days. The titre disappeared at 75 days and then reappeared at a low level at 90 days. In all cases 2-mercaptoethanol resistant antibodies (IgG) were detected very early (14 days). Before 30 days, all agglutinating antibodies detected via the M/A test were 2-mercaptoethanol resistant.

Cultural isolation. Urine samples collected between the 10th and 40th day were positive by darkfield examination and culture isolation in all rats. After 40 days, the urine from rats infected with *grippytyphosa* were negative by both methods employed. The urine from rats infected with *icterohaemorrhagiae* were positive by culture and darkfield examination throughout the entire course of the experiment (220 days).

At the time of necropsy, the rats in groups A and B, infected with *icterohaemorrhagiae*, were culturally positive from all kidney and urine specimens. The animals in group C, infected with *grippytyphosa*, were culturally negative in all specimens tested.

Histologic results. As observed from culture isolation, kidney sections from all rats infected with *icterohaemorrhagiae* had leptospires. Histologically, organisms were seen strictly in the lumen of kidney tubules. No organisms were observed invading epithelial cells. In the rats infected with *grippytyphosa*, all kidney sections were negative for the presence of leptospires.

DISCUSSION

Significant differences were observed in infections between rats inoculated with *icterohaemorrhagiae* and those inoculated with *grippytyphosa*. The *ictero-*

haemorrhagiae infected rats developed rapidly a chronic carrier state and actively shed leptospires via the urine during the 220 days of the experiment. Histologically, the lumen of some convoluted tubules had a high concentration of organisms. No leptospires were observed invading epithelial cells or capillaries.

The *grippytyphosa* infected rats, on the other hand, went from the acute phase of infection to a short period of urinary shedding (40 days) and then apparently cleared the infection. The serological results indicate a rapid drop in antibody titres shortly after the urinary shedding ceased.

It appears there is a special host-parasite relationship between the Norway rat and *icterohaemorrhagiae*. This relationship was not observed with *grippytyphosa* in the rat. Although this organism proved infective for Norway rats, it did not develop a chronic carrier state. In this experiment, the size and virulence of the inoculum did not seem to be the determining factor, since all animals received the same number of organisms. The three strains had proven virulent and killed weanling hamsters when challenged with two thousand cells. Serovar *grippytyphosa* is commonly isolated from wild mammal carriers such as squirrels, opossums, foxes, raccoons, skunks, etc.; however, it has never been isolated from a wild Norway rat.

As first indicated by Uhlenhuth^{1,3} in 1943, it appears there are still some unknown factors determining this "host election" phenomenon. The Norway rat is probably the most successful chronic carrier of *icterohaemorrhagiae*, but may not act as a true carrier of other leptospiral serovars such as *grippytyphosa*.

LITERATURE CITED

1. ALSTON, J.M. and J.C. BROOM. 1958. *Leptospirosis in Man and Animals*. Edinburgh: E & S, Livingstone Ltd.
2. BABUDIERI, B. 1958. Animal reservoirs of leptospires. Ann. N.Y. Acad. Sci. 70: 393-413.

3. COLE, J.R., C.R. SULZER and A.R. PURSELL. 1973. Improved microtechnique for the leptospiral microscopic agglutination test. *Appl. Microbiol.* 25: 976-980.
4. CRAWFORD, R.P. 1972. Molecular characteristics of antibody detected by the microscopic agglutination test in serum of guinea pigs with leptospirosis. *Am. J. Vet. Res.* 33: 1507-1512.
5. ELLINGHAUSEN, H.C., Jr. and W.C. McCULLOUGH. 1965. Nutrition of *Leptospira pomona* and growth of 13 other serotypes: A serum-free medium employing oleic albumin complex. *Am. J. Vet. Res.* 26: 39-44.
6. ———. 1959. Nephelometry and a nephelo-culture flask used in measuring growth of leptospirae. *Am. J. Vet. Res.* 20: 1072-1076.
7. EMANUEL, M.L. 1959. The susceptibility of mice to North Queensland strains of leptospirae. *Aust. J. Exp. Biol.* 37: 17-39.
8. FAINE, S. 1962. Factors affecting the development of the carrier state of leptospirosis. *J. Hyg. Camb.* 60: 427-434.
9. GALTON, M.M., R.W. MENGES, E.B. SHOTTS, A.J. NAHMIAS and C.W. HEATH. 1962. Leptospirosis epidemiology, clinical manifestations in man and animals and methods in laboratory diagnosis. *Publ. Hlth. Serv. Publ. No. 951*: 1-70.
10. STEINER, G. and G. STEINER. 1944. New silver stain for demonstration of bacteria, spirochetes and fungi in sections from paraffin-embedded tissue blocks. *J. Lab. Clin. Med.* 29: 868-871.
11. STONE, S.H. 1954. Method for obtaining venous blood from the orbital sinus of the rat or mouse. *Science* 119: 110.
12. TABEL, H. and L. KARSTAD. 1967. The renal carrier state of experimental *Leptospira pomona* infections in skunks (*Mephitis mephitis*). *Am. J. Epidemiol.* 85: 9-16.
13. UHLENHUTH, P. 1943. Die Maus als Leptospirentraeger, zugleich ein Beitrag zur Frage der Blutdifferenzierung verschiedener Mausearten. *Z. Immun. Forsch.* 104: 338.

Received for publication 7 August 1979