

## **Adenovirus-like Agent in the Bursa of Fabricius of Herring Gulls (*Larus argentatus* Pontoppidan) from Newfoundland, Canada**

Author: Leighton, F. A.

Source: Journal of Wildlife Diseases, 20(3) : 226-230

Published By: Wildlife Disease Association

URL: <https://doi.org/10.7589/0090-3558-20.3.226>

---

BioOne Complete ([complete.BioOne.org](https://complete.BioOne.org)) is a full-text database of 200 subscribed and open-access titles in the biological, ecological, and environmental sciences published by nonprofit societies, associations, museums, institutions, and presses.

Your use of this PDF, the BioOne Complete website, and all posted and associated content indicates your acceptance of BioOne's Terms of Use, available at [www.bioone.org/terms-of-use](https://www.bioone.org/terms-of-use).

Usage of BioOne Complete content is strictly limited to personal, educational, and non - commercial use. Commercial inquiries or rights and permissions requests should be directed to the individual publisher as copyright holder.

---

BioOne sees sustainable scholarly publishing as an inherently collaborative enterprise connecting authors, nonprofit publishers, academic institutions, research libraries, and research funders in the common goal of maximizing access to critical research.

# RESEARCH NOTES/CASE REPORTS

*Journal of Wildlife Diseases*, 20(3), 1984, pp. 226–230  
© Wildlife Disease Association 1984

## Adenovirus-like Agent in the Bursa of Fabricius of Herring Gulls (*Larus argentatus* Pontoppidan) from Newfoundland, Canada

F. A. Leighton, Department of Pathology, New York State College of Veterinary Medicine, Cornell University, Ithaca, New York 14853, USA

Little is known about diseases of herring gulls. Threlfall (1967, *Bull. Wildl. Dis. Assoc.* 3: 62–67) described a variety of diseases in herring gulls and reviewed the available literature, and herring gulls were listed as non-specific hosts of several infectious disease agents in Davis et al. (eds., 1971, *Infectious and Parasitic Diseases of Wild Birds*, Iowa State Univ. Press, Ames, Iowa, 344 pp.). Infection of herring gulls in the western Atlantic with a Sakhalin group arbovirus has been reported (Main et al., 1976, *J. Wildl. Dis.* 12: 182–194) and a putative viral disease, puffinosis, has been observed in this species (Nuttall and Harrup, 1982, *Arch. Virol.* 73: 1–13; Nuttall et al., 1982, *Can. J. Zool.* 60: 3462–3465). Virus infection and associated lesions in the bursa of Fabricius in herring gulls is reported here for the first time.

Virus-associated bursal lesions were observed in gulls during experimental studies of crude oil toxicity. Experimental protocols and captive management of these gulls have been described (Leighton et al., 1983, *Science* 220: 871–873). Nestling herring gulls approximately 3 wk old were captured 12 July 1982 on Great Island and housed in an experimental animal facility at Memorial University, St. John's, Newfoundland, Canada. An oil ingestion experiment was begun on 17 July and the birds were killed on 23 or 24 July. Bursas and other tissues were fixed in 10% buff-

ered formalin (pH 7.4) and samples were subsequently embedded in paraffin, sectioned at 4–5  $\mu\text{m}$ , and stained with hematoxylin and eosin. For electron microscopy, formalin-fixed 1  $\text{mm}^3$  tissue blocks were rinsed in buffer, post-fixed in osmium tetroxide and uranyl acetate, dehydrated through graded ethanols and propylene oxide, and embedded in epon-araldite. One  $\mu\text{m}$  sections were stained with toluidine blue-basic fuchsin for light microscopy and thin sections were stained with uranyl acetate and lead citrate. Thin sections were examined in a Philips 301 electron microscope and magnifications were calibrated with a carbon grating replica.

Lesions typical of this virus infection were present in the bursa but were not seen in thymus, spleen, or other tissues. Bursal lesions were seen in 14 of 17 oil-dosed birds and 7 of 20 controls ( $P \leq 0.01$ ,  $\chi^2$  analysis). In oil-dosed birds the lesions were more extensive and were seen against the background of a generalized lymphocyte depletion. In controls the lesions occurred in a small number of follicles and bursas were otherwise of normal morphology (Fig. 1a, b). Lesions were only observed in medullary stromal cells and appeared to constitute a developmental sequence. Cells deep within the medulla became greatly enlarged with marked karyomegaly, and medullary lymphocytes disappeared. One or more large basophilic masses became visible within the enlarged

Received for publication 22 December 1983.

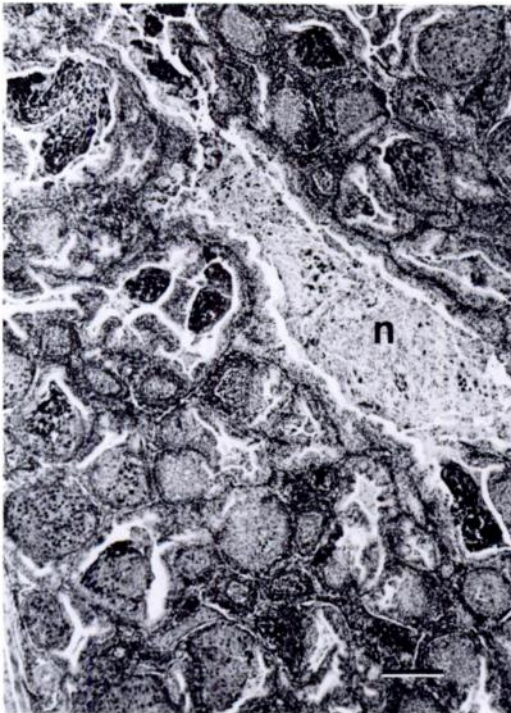
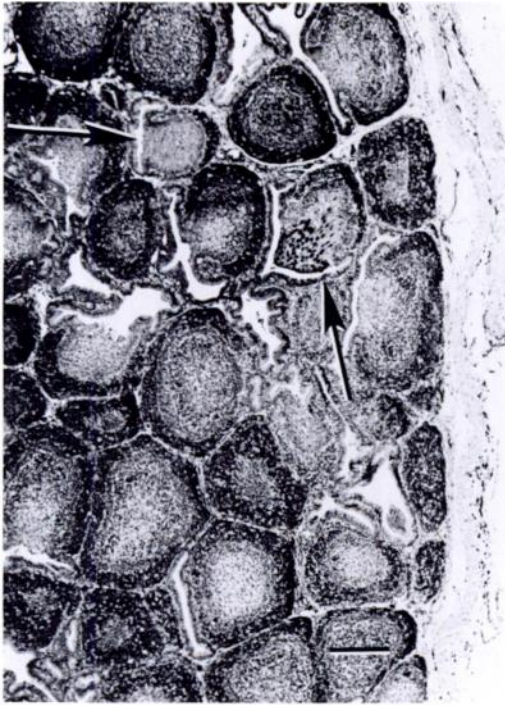


FIGURE 1a, b. Range of severity of virus-associated lesions of the bursa of Fabricius in nestling herring gulls. a. Mild case. Bursa is of generally normal morphology. Two follicles show lesions of virus in-

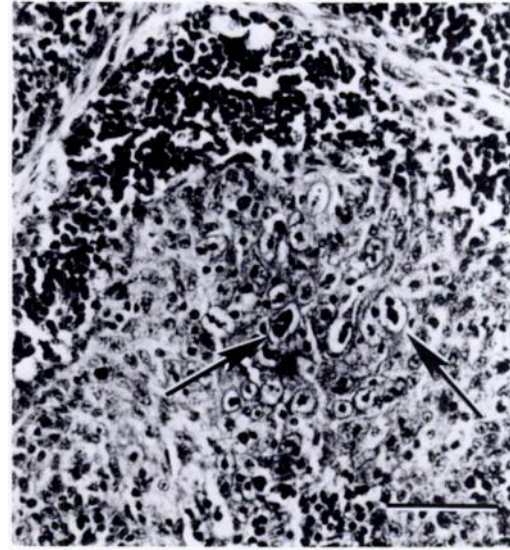


FIGURE 2. Early lesion of virus infection of medullary stromal cells of the bursa in a nestling herring gull. There is loss of medullary lymphoid cells and enlargement and karyomegaly of stromal cells. Inclusion body-like intranuclear masses are present in enlarged nuclei (arrows). Paraffin section stained with H&E. Bar = 50  $\mu$ m.

nuclei, and margination of chromatin was sometimes visible (Fig. 2). Nuclei ultimately enlarged to occupy nearly the entire cell volume and became diffusely basophilic while one or more deeply basophilic intranuclear masses remained visible (Fig. 3). These immense basophilic cells were ultimately extruded into the bursal lumen (Fig. 4) leaving the follicular medulla as a luminal diverticulum lined by a thin layer of stromal cells or bursal epithelium. Intact sloughed basophilic cells could be seen in luminal masses of necrotic cellular debris and heterophils (Fig. 1b). Infiltration with heterophils occurred

←

fection (arrows). b. Severe case. Nearly all follicles are affected. Necrotic cellular debris (n) containing large sloughed basophilic cells is present in the bursal lumen. Paraffin section stained with H&E. Bars = 200  $\mu$ m.



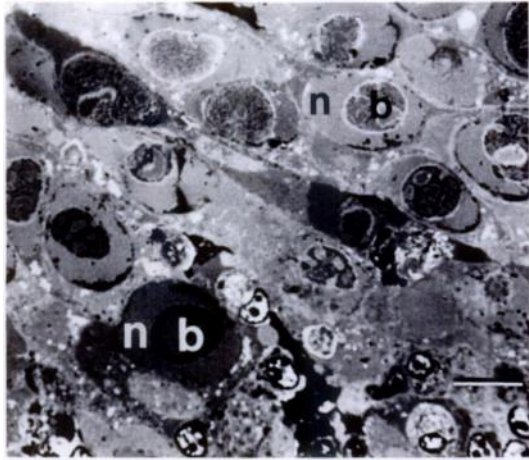


FIGURE 3. Large basophilic virus-infected cells in the medulla of an affected bursal follicle from a herring gull nestling. Expanded nuclei (n) with oval, more darkly stained intranuclear bodies (b) occupy most of the cell volume. Epon-araldite section stained with toluidine blue-basic fuchsin. Bar = 10  $\mu$ m.

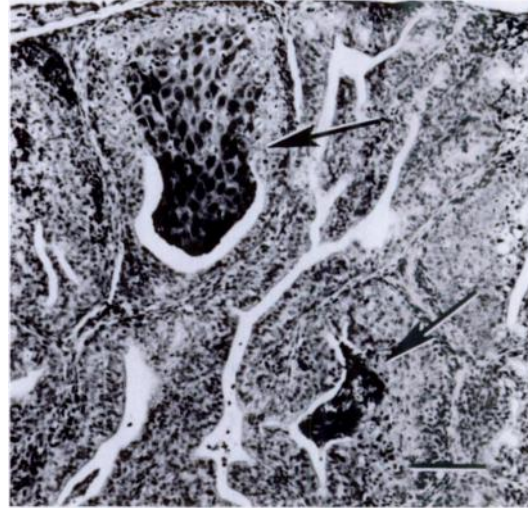


FIGURE 4. Masses of enlarged, basophilic, virus-infected cells (arrows) from the bursa of a herring gull nestling. Infected cells become increasingly basophilic and are extruded and sloughed into the bursal lumen. Paraffin section stained with H&E. Bar = 100  $\mu$ m.

along the cortico-medullary junction of many affected follicles.

Electron micrographs of the typical enlarged, basophilic cells in Figure 3 showed the nuclei to be filled with non-enveloped virions (Fig. 5). These ranged in diameter from 67 to 79 nm, had cubic symmetry, and were usually hexagonal in outline. Virions within the central chromatin area were occasionally tightly packed in paracrystalline arrays (Fig. 6). Virions were always intracellular and were largely restricted to nuclei. Cytoplasmic virions were naked and occurred adjacent to disrupted nuclear membranes in affected cells. Cellular debris containing naked virions was present in phagocytic vacuoles of macrophages. Nuclear chromatin was present in a central body as thick irregular cords interwoven among masses of virions and in dense marginated clumps along inner nuclear membranes. The cytoplasm of affected cells was reduced to a thin perinuclear rim. Plasmalemmas were generally poorly preserved in the formalin-fixed

material. Some adjacent affected cells were joined by desmosomes, which showed the cells to be epithelial rather than lymphoid.

The size, morphology, and predominantly intranuclear location of the virions suggest strongly that the virus observed here was an adenovirus (Fenner et al., 1974, *The Biology of Animal Viruses*, 2nd ed., Academic Press, New York, 834 pp.). The virus infection described here was an unexpected finding and appropriate samples for virus isolation were not taken. Adenoviruses were not isolated from blood samples of herring gulls or other birds collected on Great Island in 1972 (Main et al., 1976, *op. cit.*). Adenoviruses are generally quite host-specific. Infection is typically wide-spread and inapparent (Gillespie and Timoney, 1981, Hagan and Bruner's *Infectious Diseases of Domestic Animals*, Cornell Univ. Press, pp. 506-520). Thus, this bursal virus may be a spe-

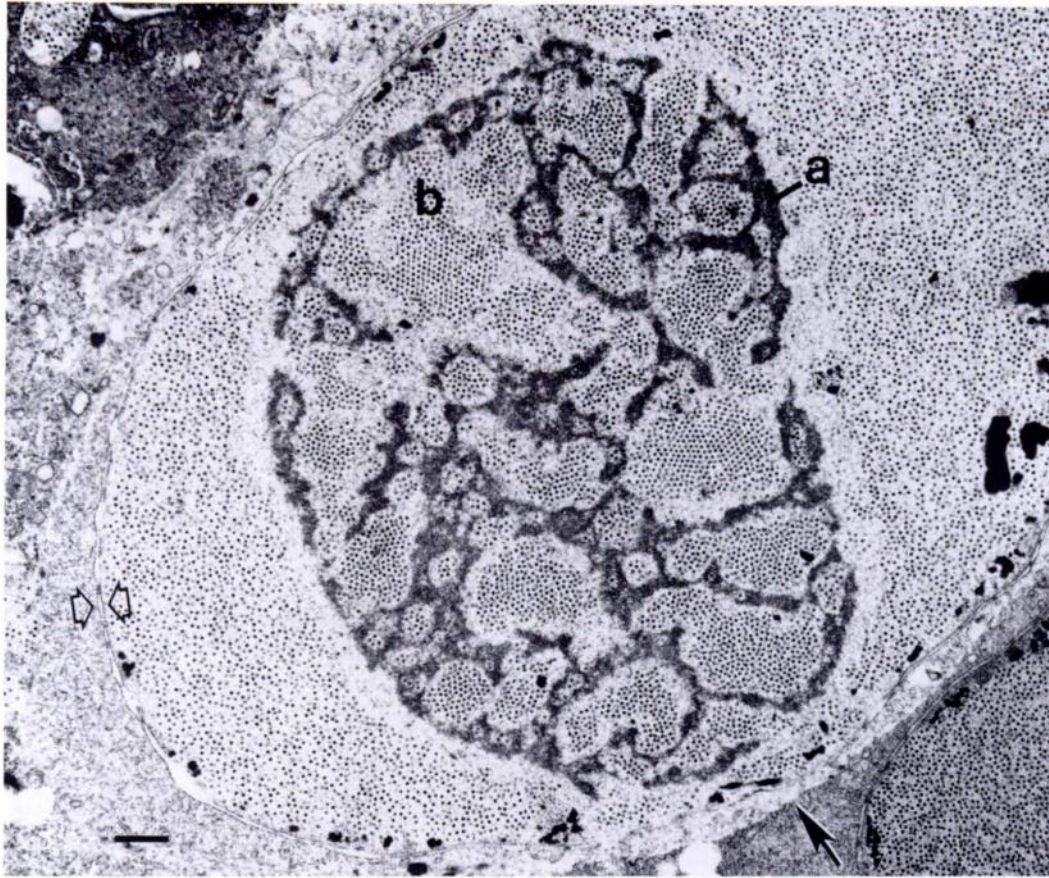


FIGURE 5. Electron micrograph of a large basophilic cell from Figure 3. Virions fill the expanded nucleus which is delimited by a double membrane (open arrows). Cords of chromatin-like material (a) form an intranuclear body and surround dense clusters of virions, some of which display a paracrystalline close-packing (b). Electron-opaque material at nuclear margin, suggestive of condensed chromatin, was more extensive in other cells (Fig. 3). Cytoplasm is reduced to a thin perinuclear rim. The plasmalemma is not well preserved. Its location is identified at its interface (closed arrow) with cytoplasm of higher density in an adjacent cell. Bar = 1  $\mu$ m.

cific virus of herring gulls. It is possible, however, that infection of gulls with a non-specific virus occurred during captivity. While direct contact with other animals was avoided, the experimental facility also housed domestic chickens, mallard ducks (*Anas platyrhynchos* L.), ringed turtle doves (*Streptopelia risoria* (L.)), and Japanese quail (*Coturnix* sp.), as well as do-

mestic pigs, sheep, goats, horses, dogs, and laboratory rodents and rabbits.

The significance of this virus to gulls is unknown. In mild cases, it seemed unlikely that bursal function would have been compromised. However, in the more severe cases, a large majority of follicles were affected and some degree of immunodeficiency might have occurred in surviving






FIGURE 6. Electron micrograph of virions in an intranuclear body of a cell from Figure 3. Cubic symmetry and paracrystalline formations are evident. Bar = 500 nm.

birds. Immunodeficiency has been reported in infectious bursal disease, a reovirus infection of the bursa in domestic chickens (Hitchner, 1978, *In Diseases of Poultry*, 7th Ed., Hofstad et al. (eds.), Iowa State Univ. Press, Ames, Iowa, pp. 647–653).

This report was supported by the Canadian Wildlife Service (CWS) and Medical Research Council of Canada, and undertaken jointly with D. B. Peakall and R. G. Butler. Assistance was rendered by V. Adams, D. Jeffrey, A. Harfenist, A. Pajor, and A. Pellegrino. Gulls were collected under CWS Permit A SK 15-82 and tissues were brought to Cornell under permit SC 0931 from the New York State Dept. of Environmental Conservation. David L. Graham encouraged pursuit of the lesions at the ultrastructural level and reviewed all electron micrographs. Manuscript reviews by M. J. Appel, D. L. Graham, R. M. Lewis, and K. A. Schat are gratefully acknowledged.

*Journal of Wildlife Diseases*, 20(3), 1984, pp. 230–232  
© Wildlife Disease Association 1984

## Malignant Catarrhal Fever in a Shira's Moose (*Alces alces shirasi* Nelson)

**Elizabeth S. Williams**, Wyoming State Veterinary Laboratory, Division of Microbiology and Veterinary Medicine, University of Wyoming, Laramie, Wyoming 82071, USA; **E. Tom Thorne**, Wyoming Game and Fish Department Research Laboratory, University Station, Box 3312, Laramie, Wyoming 82071, USA; and **Huey A. Dawson**, Wyoming Game and Fish Department, Sybille Wildlife Research Unit, Wheatland, Wyoming 82523, USA

Malignant catarrhal fever (MCF), a sporadic, generally fatal, viral disease has been reported in a variety of domestic and wild ruminants, including many cervid species (Plowright, 1981, *In Infectious Diseases of Wild Mammals*, 2nd Ed., Davis et al. (eds.), Iowa State Univ. Press, Ames, Iowa, pp. 126–138; Heuschele, 1982, *Proc. U.S. Anim. Health Assoc.* 86:

552–570). Two European reports (Andersson, 1953, *Nord. Veterinaarmed.* 5: 847–854; Altmann et al., 1973, *Proc. 15th Int. Symp. Dis. Zoo Anim.*, Berlin, pp. 41–49) describe MCF in captive “elk” but do not give the species of the affected animals; presumably these case reports refer to *Alces alces*. We believe this is the first report of MCF in a moose in North America.

Malignant catarrhal fever is being rec-

Received for publication 19 December 1983.