

TESTICULAR TUMORS IN CARP–FUNA HYBRID: ANNUAL CYCLE AND EFFECT ON A WILD POPULATION

Authors: Granado-Lorencio, Carlos, Garcia-Novo, Francisco, and Lopez-Campos, Jose

Source: Journal of Wildlife Diseases, 23(3) : 422-427

Published By: Wildlife Disease Association

URL: <https://doi.org/10.7589/0090-3558-23.3.422>

BioOne Complete (complete.BioOne.org) is a full-text database of 200 subscribed and open-access titles in the biological, ecological, and environmental sciences published by nonprofit societies, associations, museums, institutions, and presses.

Your use of this PDF, the BioOne Complete website, and all posted and associated content indicates your acceptance of BioOne's Terms of Use, available at www.bioone.org/terms-of-use.

Usage of BioOne Complete content is strictly limited to personal, educational, and non - commercial use. Commercial inquiries or rights and permissions requests should be directed to the individual publisher as copyright holder.

BioOne sees sustainable scholarly publishing as an inherently collaborative enterprise connecting authors, nonprofit publishers, academic institutions, research libraries, and research funders in the common goal of maximizing access to critical research.

TESTICULAR TUMORS IN CARP-FUNA HYBRID: ANNUAL CYCLE AND EFFECT ON A WILD POPULATION

Carlos Granado-Lorencio,¹ Francisco Garcia-Novo,¹ and Jose Lopez-Campos²

¹ Department of Ecology, Faculty of Biology, University of Sevilla, Sevilla, Spain

² Department of Cytology and Histology, Faculty of Biology, University of Sevilla, Sevilla, Spain

ABSTRACT: This study documents the occurrence of testicular tumors in a wild population of carp-funa hybrids. The most prevalent tumor was a dysgerminoma. There were lower prevalences of seminomas, leiomyomas, Sertoli cell tumors, and spermatocytic seminomas. Sex-ratio, gonadosomic index (G_i) and the prevalence of tumors in the monthly catch was analysed for five consecutive reproduction periods (1980 to 1984). Gonadal tumors were found only in males. This may be important to the population dynamics of the carp-funa hybrid, since a high percentage of the fish that die during spawning have these tumors. A schematic model for the reservoir's population is suggested.

Key words: Testicular tumors, carp-funa hybrid, wild population, reservoir, Spain, dysgerminoma, population dynamics.

INTRODUCTION

The study of hybrids produced by crossing the Crucian carp (*Carassius carassius*) with the common carp (*Cyprinus carpio*) has been previously described (Matsui and Makino, 1936; Makino et al., 1955; Ojima, 1957; Leatherland and Sonstegard, 1978; Shearer and Mulley, 1978). Although the presence of carp-funa hybrid in Iberian and French continental waters is regarded as unusual, recent studies by Granado-Lorencio and Garcia-Novo (1981, 1985) have confirmed the presence of carp-funa hybrid in Spain in relatively high numbers in various reservoirs and basins of the Tago River and Guadiana River. These studies have demonstrated the existence of tumors in the male gonads of >10% of the specimens captured, and these tumors always appear within a limited size range of fish. These findings stimulated further research of this phenomenon in the Arrocampo Reservoir.

MATERIALS AND METHODS

Arrocampo Reservoir has been previously described (Granado-Lorencio and Garcia-Novo, 1981, 1985) an impoundment of the Arrocampo River. The capacity of the reservoir is 35.5 million m³. The lake is eutrophic and has a low mineral content (Fig. 1). It is used for cooling by the Almaraz Nuclear Power Station.

Fish sampling took place during 1980-1984, using trammel and gill nets at seven sites at the reservoir. The number of specimens captured for the 5-yr period, 1980-1984, were 295, 390, 655, 309, and 231, respectively.

Standard measurements for each specimen were: standard length (mm); total weight (g); sex; gonadal weight (g); and, for those specimens with gonadal tumors, tumor weight (g). The gonadosomic index (G_i) was calculated for both males and females ($G_i = W_g \times 100/W_t$; where W_g is gonadal weight and W_t is total weight). The size and age class relationship is according with Granado-Lorencio (1983). The percentage of males with tumors was also calculated in relation to the total specimens examined and to the total males caught between consecutive reproduction periods.

Tumors for histological examination were fixed in buffered 10% formalin (pH 7.2), embedded in paraffin, and cut serially at 4-6 μ m in thickness. Paraffin sections were stained with haematoxylin and eosin, van Gieson's alcian blue (pH 2.5) and PAS (periodic acid reagent).

RESULTS

We examined a total of 40 fishes with gonadal tumors. Tumors were detected only in males, never in females. The most prevalent type was the dysgerminoma. Other tumors, of lower prevalences, included seminomas, leiomyomas, Sertoli cell tumors and spermatocytic seminomas. The tumors were not encapsulated, and the cut

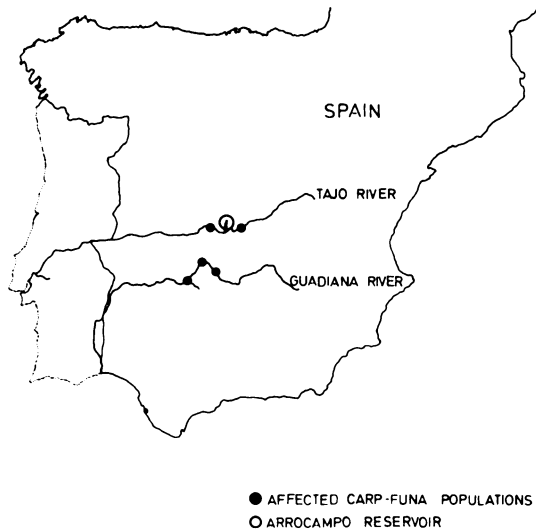

FIGURE 1. Collection sites of carp-funa hybrids with testicular tumors in Spain.

surface revealed abundant cystic cavities (Fig. 2). The dysgerminomas were composed of pleomorphic cells which appeared primordial, had little supporting

tissue and there was an infiltration of lymphocytes (Fig. 3).

The sex-ratio (males/females) was >1 throughout most of the study (Fig. 4), except in 1982 and 1983 when lower values were found in the months preceding and following spawning (predominantly among females). The gonadosomic index (G_i) was higher in females than in males, reaching maximum values in summer (Fig. 4). However, sexually mature specimens could be found in winter, indicating a second period of reproductive activity.

The size of fish specimens with tumors during the 5-yr period was 432.6 mm (SD = 22.5 mm) (Fig. 5a). This size corresponds to age class ≥ 4 . The average monthly weight of tumors (Fig. 5b) follows an annual cycle with maximum values before reproduction and minimum values in the months following reproduction. These cycles repeated themselves throughout the period of the study.

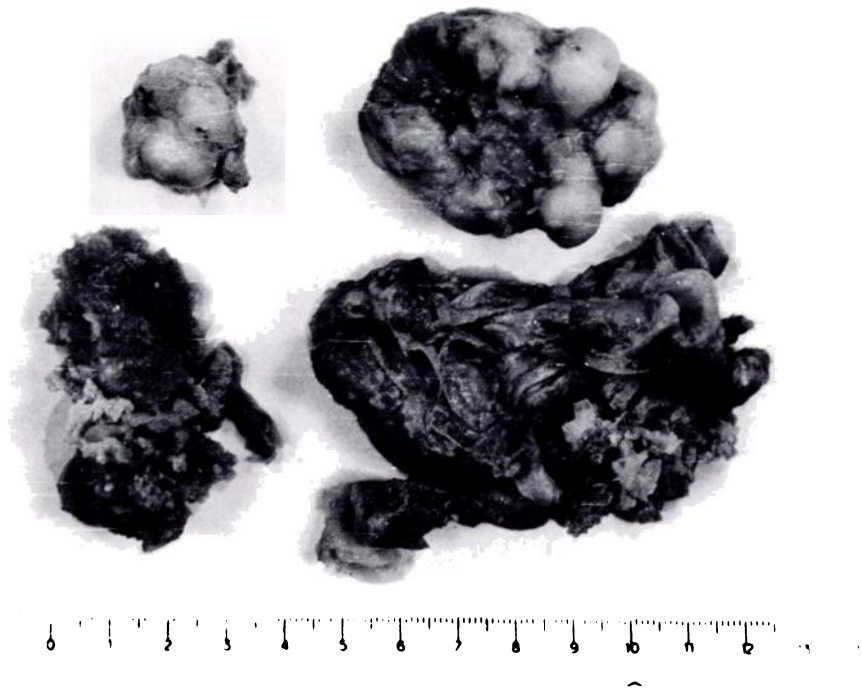


FIGURE 2. Lateral view of a tumor from a carp-funa hybrid (courtesy of Dr. Onorato).

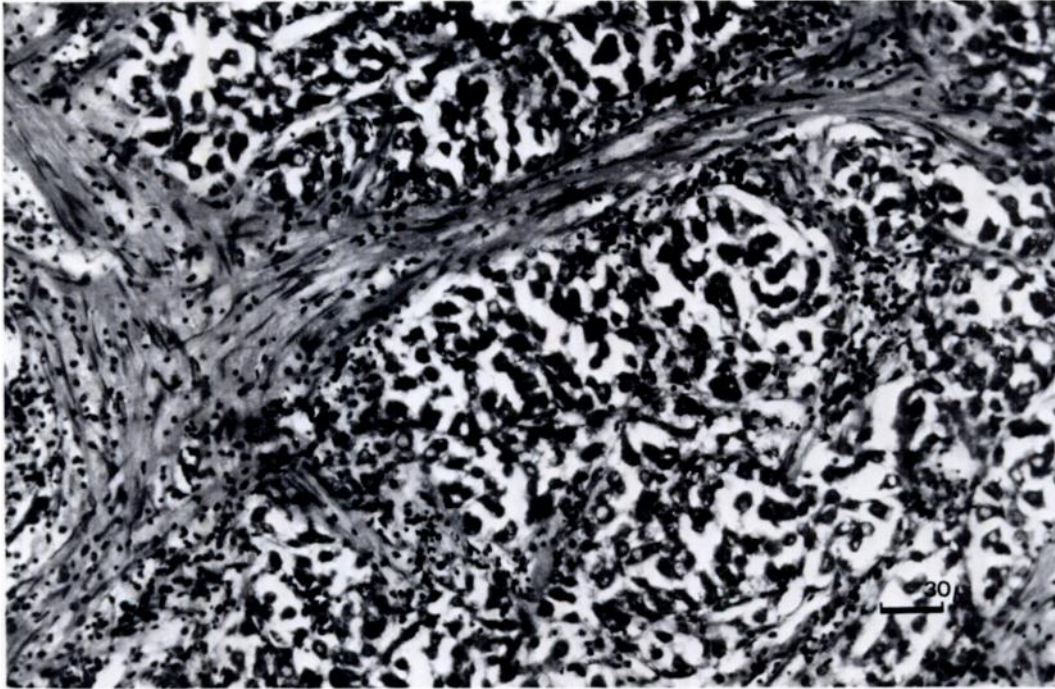


FIGURE 3. Histological section of a dysgerminoma. Tumor cells were mainly composed of primordial germ cells. Hematoxylin and eosin (courtesy of Dr. Onorato).

The percentage of affected fish caught in relation to the total catch and to the number of males (Fig. 5c, d) shows low and decreasing values during 1980 and 1982 (Table 1) with a strong increase in 1983 and 1984. The point of change from the initial trend (1982) coincides with sex-ratio values of <1 .

The percentages of monthly catches of common carp, Crucian carp and carp-funa hybrids and the remaining species of the

fish community in the reservoir can be seen in Figure 6. Figure 7 shows the structure of the population according to age throughout the period of the study based on the average size for each age class obtained by Granado-Lorencio (1983).

DISCUSSION

Arrocampo Reservoir was filled during winter 1976–1977. Previously it had been a lagoon of approximately 3 km \times 100 m.

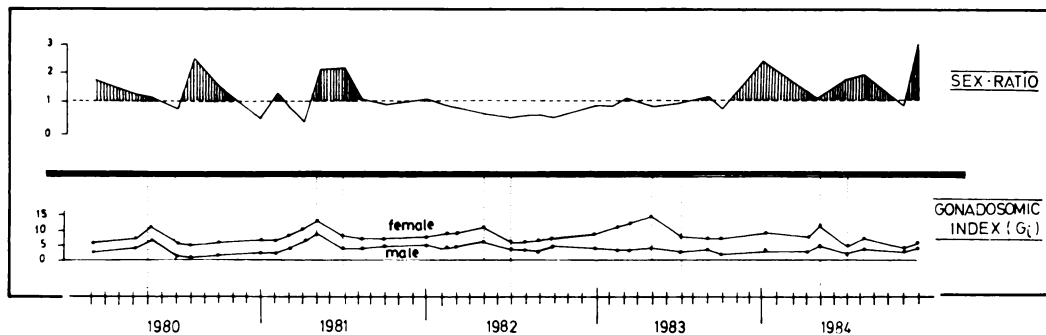


FIGURE 4. Sex-ratios and gonadosomic indexes (G_i) for carp-funa hybrids during the period 1980–1984.

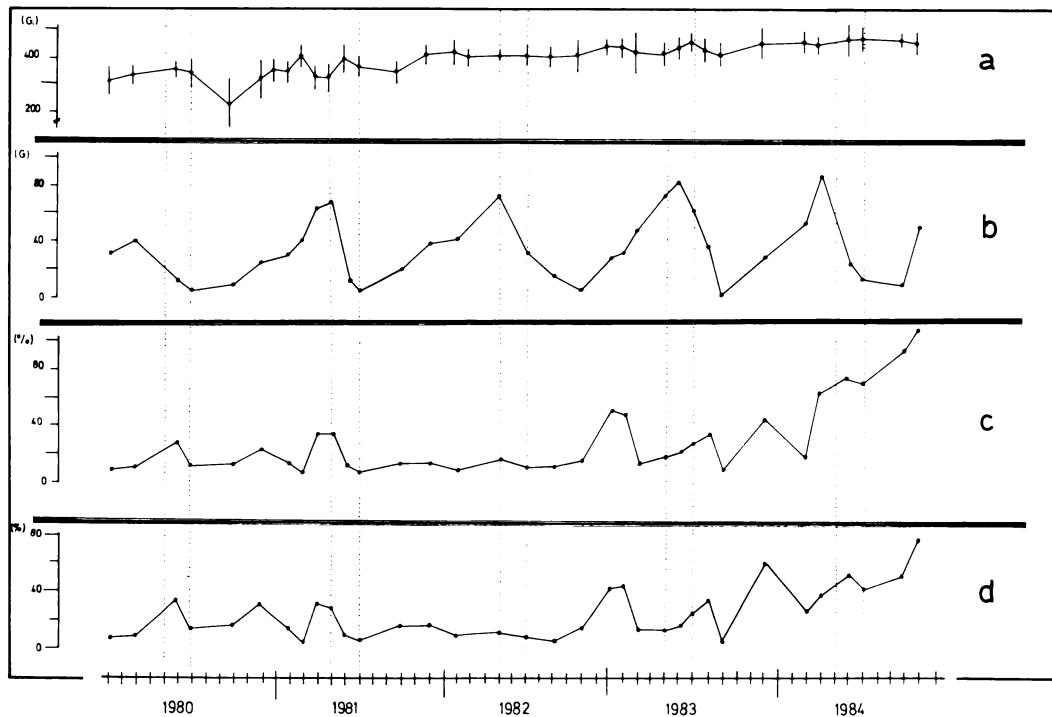


FIGURE 5. Monthly percentages of affected carp-funa hybrids compared according to average size (a), weight of tumors (b), affected fish/total catch (c), and affected fish/number of males (d).

The original fish community was formed by fish populations from the Arrocampo River and those from the Tagus River that had moved up river in order to reproduce. The latter included Iberian barbel (*Barbus* spp.) and Iberian nase (*Chondrostoma toxostoma*). When the reservoir was being filled, specimens of Crucian carp and carp-funa hybrid from fish farms were introduced (usually of age class ≥ 1).

By comparing the graphs showing average tumor weight and those showing the gonadosomic index it is evident that there is a correlation between the development

of neoplasia and the reproductive cycle. Apparently, during the reproductive cycle there are tissue changes that predispose to neoplasia. These neoplastic changes are associated with a size range in the fish that corresponds to age class ≥ 4 (class ≥ 5 specimens were not found in this fish population). Younger males were observed morphologically and histologically to undergo normal gonadal development leading to sperm production.

In males that reach age ≥ 4 , development of the tumors causes mortality. Although this phenomenon has not been

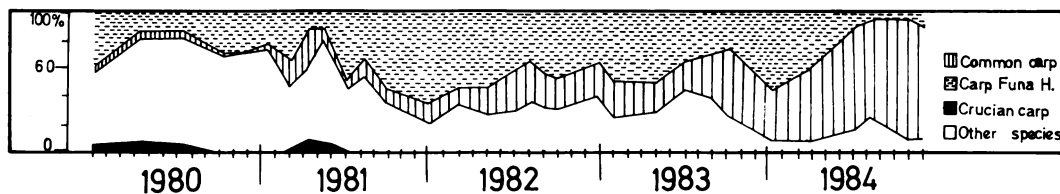


FIGURE 6. Monthly percentage of fish caught in the Arrocampo Reservoir during the period 1980–1984.

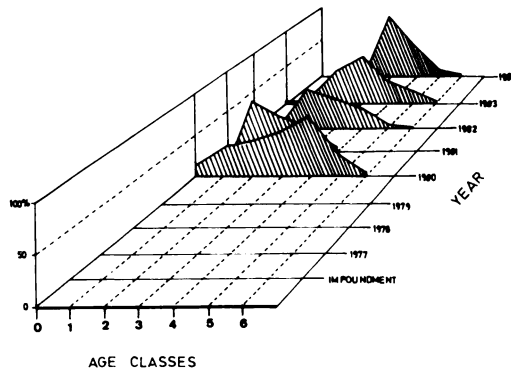


FIGURE 7. Percentage of fish catch (carp-funa hybrid) according to age class (1980–1984).

tested experimentally, through direct observations it is possible to deduce that during the spawning period (May–July) a high percentage of carp-funa hybrids that die have these tumors.

The joint analysis of the observed data and the history of the reservoir suggests a schematic model for the carp-funa hybrid population in the Arrocampo Reservoir (Fig. 8). During the winter of 1977 when the reservoir was filled, populations of

TABLE 1. Yearly data for percentage of the number of tumors/total catch and number of tumors/number of males in carp-funa hybrids from Arrocampo Reservoir, Spain.

Period	Sample size	Number tumors/total catch	Number tumors/no. of males
1980	295	17.0	19.4
1981	390	15.2	16.6
1982	655	8.7	12.0
1983	309	23.0	24.2
1984	231	43.5	50.0

common carp and carp-funa hybrid (age class ≥ 1) existed. In summer 1977 the natural crossing of common carp and Crucian carp that had common areas of reproduction (Granado-Lorencio, 1983) occurred and the population of carp-funa hybrid consisted of age classes ≤ 1 and ≥ 2 . In 1978 the same processes took place and the population consisted of age classes ≤ 1 , ≤ 2 and ≥ 3 . In 1979 the age classes were ≤ 1 , ≤ 2 , ≤ 3 and ≥ 4 . During 1980–1981 the age structure was established at ≤ 1 , ≤ 2 , ≤ 3 , ≤ 4 and females of ≥ 5 . In 1981–1982 the gonadal tumors were reduced owing to the

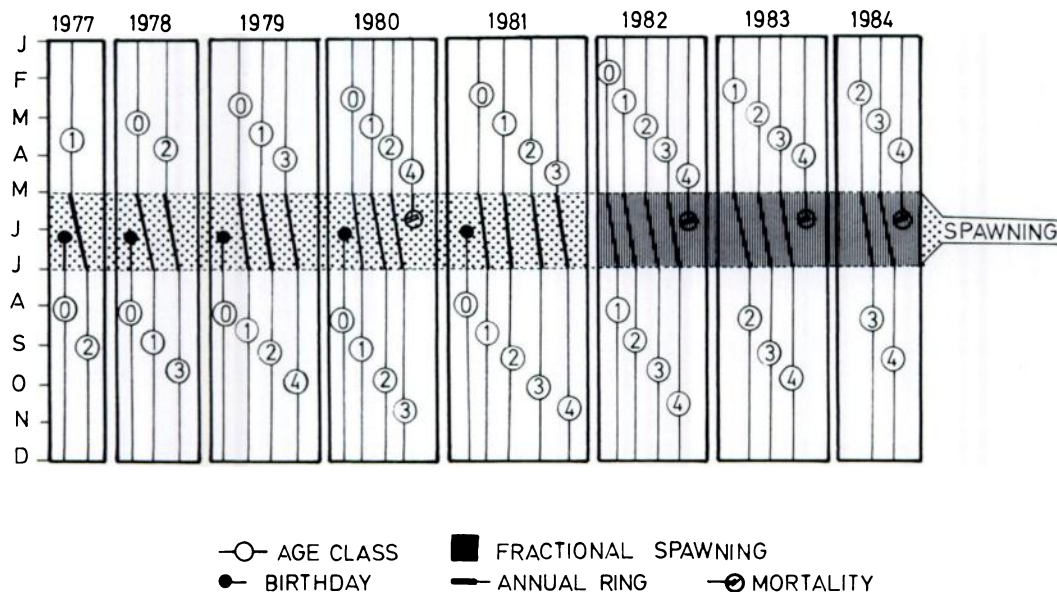


FIGURE 8. Model of the carp-funa hybrid population in the Arrocampo Reservoir from its filling date and the effect of tumors on the evolution of the population from 1977–1984.

nonexistence of males belonging to class ≥ 4 and the rare cases of affected fish (8.7% of the total catch) that were part of the stock that had been introduced in 1977 (the age class that was > 1). In 1982–1982 males of age class ≥ 4 died and reproduction was low, possibly due to the decrease in the Crucian carp population. After 1982 this species was no longer caught in the reservoir (Granado-Lorencio and Garcia-Novo, 1985). Subsequent to 1983, the absence of reproduction in, and the mortality rate associated with, age class ≥ 4 has slowly reduced the carp–funa hybrid population in the reservoir.

A final question concerning this population is related to the effects of crossing hybrid females and their parents. Undoubtedly, the answer to this question would contribute to a better understanding of the annual tumor cycle and to the dynamics of the carp–funa hybrid population in natural ecosystems.

ACKNOWLEDGMENTS

We are grateful for the valuable discussions and suggestions of Dr. James C. Chubb, University of Liverpool, England; Dr. Ryo Suzuki, National Research Institute of Aquaculture, Japan; Dr. H. I. H. Prince Masahito, Cancer Institute, Japan; and Dr. P. Baumann, Columbia National Fisheries Research Laboratory, USA. The photographs of tumors by Dr. J. Moreno Onorato are gratefully acknowledged.

LITERATURE CITED

- GRANADO-LORENCIO, C. 1983. Ecología de la comunidad íctica del embalse de Arrocampo (Cuenca del Río Tajo, Cáceres). Ph.D. Dissertation. University of Sevilla, Sevilla, Spain, 364 pp.
- GRANADO-LORENCIO, C., AND F. GARCIA-NOVO. 1981. Cambios ictiológicos durante las primeras etapas de la sucesión en el embalse de Arrocampo (Cuenca del Tajo, Cáceres). Boletín Instituto Español de Oceanografía 4: 224–243.
- GRANADO-LORENCIO, C., AND F. GARCIA-NOVO. 1985. Fish community evolution in a new reservoir (southern Spain). Proceedings of Symposium on Small Hydropower and Fisheries, Denver, Colorado, pp. 80–83.
- LEATHERLAND, J. F., AND R. A. SONSTEGARD. 1978. Structure of normal testis and testicular tumours in cyprinids from Lake Ontario. Cancer Research 38: 3164–3173.
- MATSUI, Y., AND S. MAKINO. 1936. Note on the intersex of hybrids between carp and Crucian carp (*Carassius carassius*). Zoological Magazine 47: 545–551.
- MAKINO, S., Y. OJIMA, AND Y. MATSUI. 1955. Some cytological features of sterility in the carp–funa hybrids. Zoological Annals of Japan 28: 12–17.
- OJIMA, Y. 1957. The desoxyribose nucleic acid (DNA) content in liver cells of the carp–funa hybrids. Journal of Faculty of Sciences, University of Hokkaido, VI. Zoology 13: 293–296.
- SHEARER, K. D., AND J. C. MULLEY. 1978. The introduction and distribution of the carp *Cyprinus carpio* Linnaeus in Australia. Australia Journal of Marine and Freshwater Research 29: 551–563.

Received for publication 10 July 1986.