



Skull Deformity in a Herring Gull Chick (*Larus argentatus*)

Authors: Threlfall, William, and Roy, Nicole A.

Source: Journal of Wildlife Diseases, 24(1) : 133-136

Published By: Wildlife Disease Association

URL: <https://doi.org/10.7589/0090-3558-24.1.133>

BioOne Complete (complete.BioOne.org) is a full-text database of 200 subscribed and open-access titles in the biological, ecological, and environmental sciences published by nonprofit societies, associations, museums, institutions, and presses.

Your use of this PDF, the BioOne Complete website, and all posted and associated content indicates your acceptance of BioOne's Terms of Use, available at www.bioone.org/terms-of-use.

Usage of BioOne Complete content is strictly limited to personal, educational, and non - commercial use. Commercial inquiries or rights and permissions requests should be directed to the individual publisher as copyright holder.

BioOne sees sustainable scholarly publishing as an inherently collaborative enterprise connecting authors, nonprofit publishers, academic institutions, research libraries, and research funders in the common goal of maximizing access to critical research.

SHORT COMMUNICATIONS

Journal of Wildlife Diseases, 24(1), 1988, pp. 133–136
© Wildlife Disease Association 1988

Skull Deformity in a Herring Gull Chick (*Larus argentatus*)

William Threlfall¹ and **Nicole A. Roy,²** ¹ Department of Biology, Memorial University of Newfoundland, St. John's, Newfoundland, Canada A1B 3X9; ² Département de Génie Civil (Section Environnement), École Polytechnique de Montréal, C.P. 6079, Succ. A., Montréal, Québec, Canada H3C 3A7

ABSTRACT: A skull deformity resulting in death of a herring gull chick (*Larus argentatus*) is described in detail. The bones of the skull and upper jaw were twisted, asymmetrical and of unusual size or absent. The lower jaw had an almost "spoon-like" external appearance and lacked normal articular surfaces.

Key words: *Larus argentatus*, herring gull chick, skull deformity, case report.

The ornithological literature is replete with papers reporting deformed bills in birds (Pomeroy, 1962; Gilbertson et al., 1976; Tweit et al., 1983). The value of such articles, excepting detailed anatomical studies, was queried by Parkes (1969), with Gochfeld (1972) suggesting that changes in incidence and distribution of such defects may be important. Indeed an increase in numbers of such defects in a given species of bird in an area might be caused by, and be an indicator of, man-made environmental pollution (Hays and

Risebrough, 1972). Threlfall (1968) described in detail an abnormal skull of a herring gull (*Larus argentatus*) chick taken on Gull Island, Newfoundland (47°16'N, 52°46'W).

On 21 July 1983, on the same island, another deformed herring gull, about 25 days of age, was found (Fig. 1). Only the head and bill of the chick were deformed, with the deformities being described herein. Chiasson (1983) was used as the source reference for bone terminology. The bird was banded with a U.S. Fish and Wildlife Service band and appeared to thrive while under parental care. On 9 August 1983, by which date all but a few gull chicks had fledged, the chick was found dead. The chick was extremely emaciated and we suggest that the deformity prevented proper feeding and proved fatal. The chick was photographed




FIGURE 1. Lateral and frontal view of a herring gull chick with a deformed skull.

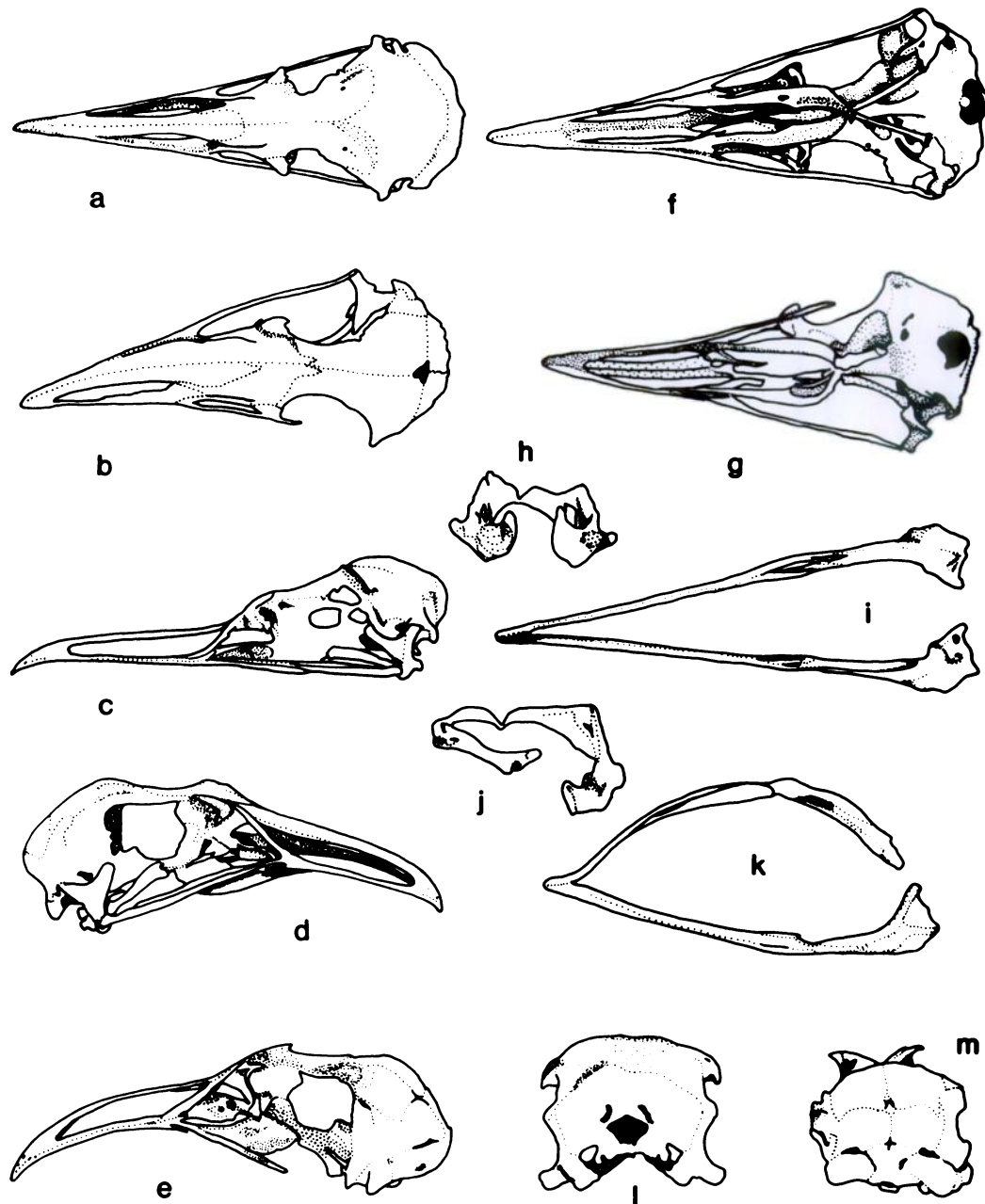


FIGURE 2. Various views of a normal and a deformed herring gull skull. Dorsal views: a, normal; b, deformed. Lateral views: c, normal; d, e, deformed. Ventral view: f, normal; g, deformed. Posterior and ventral views of mandible: h, i, normal; j, k, deformed. Posterior view of skull: l, normal; m, deformed.

while alive (Fig. 1), and when found dead the head was removed, stripped of skin and muscles and then cleaned by bacterial action in a sealed jar of water. The skull was degreased with white gas. Two other

"normal" skulls were prepared in the same manner for comparative purposes. The drawings were prepared by tracing photographs onto drawing film. Internal organs were not examined for anomalies.

The most obvious visible deformation involved the lower left mandible that was curved laterally and had the surangular and other bones rotated outwards and downwards. This gave the bill an almost "spoon-like" appearance. The upper part of the rhamphotheca curved slightly to the left. The overall appearance of the head was unusual also in that it was broad and lacked a sharp angle between bill and skull (Figs. 1, 2c, d). The underlying bony structure was, therefore, examined in detail (Fig. 2) and found to be grossly deformed and incomplete.

Dorsally, it was seen that the premaxillae and nasals were twisted to the left with the frontals being asymmetrical (Fig. 2b). The right orbit was much enlarged and misshapen. The jugal was absent on the left, while that on the right was elongate due to the twisting and shape of the orbit. The quadrate and pterygoid bones, normally hidden when a skull is examined from the dorsal aspect (Fig. 2a), were plainly visible on the right side of the skull (Fig. 2b). The skull was much broader in the orbital region than a normal skull.

A lateral view revealed the curvature of the deformed skull as compared to a normal skull (Fig. 2c-e). On the right side of the skull the nasal was elongate, as was the pterygoid. The depth of the bill was greater than usual and the premaxillae were more robust. The left quadrate was absent as well as the quadratojugal (Fig. 2e).

From the ventral aspect it was noted that the left pterygoid was short and stout while that on the right was longer and more slender. The latter was still, however, stouter than that in a normal bird (Fig. 2f, g). The presphenoid was asymmetrical, as were the palatines. The foramen magnum was displaced ventrally.

Asymmetry and deformation were obvious when the skull was examined from the posterior aspect (Fig. 2l, m). The total volume of the cranium appeared smaller than in a normal bird.

The lower jaw was much deformed, as were the articular surfaces (Fig. 2h-k). The

left articular was absent. While the bird was able to open its bill it is likely that its movement was restricted, causing problems with feeding once the chick became independent of its parents.

Deformities may be genetic in origin, or may result from chemical or physical injury to the developing embryo. Some of the former may be induced by environmental pollutants acting as mutagens or teratogens (Gochfeld, 1975). In 1983, only one of the two eggs laid by the parents of the deformed chick hatched, while in 1984 two eggs laid by the same pair failed to hatch. All eggs contained a well-developed, apparently normal, embryo. Environmental pollution has been associated with hatching failure and embryonic death in many bird species (Ramade, 1982). Among some 15,000 gull chicks banded and observed on Gull Island since 1967, the only other defects noted (total of three; skull, wing, foot) were reported by Threlfall (1968, 1969). The rarity of such events suggests random mutation, or chromosomal anomalies, rather than changes induced by mutagens or teratogens as the cause of the defect.

We thank the Natural Sciences and Engineering Research Council of Canada for the grant (NRCC-A3500) to W. Threlfall that made this work possible.

LITERATURE CITED

- CHASSON, R. B. 1983. Laboratory anatomy of the pigeon. William C. Brown Company Publishers, Dubuque, Iowa, 159 pp.
- GILBERTSON, M., R. D. MORRIS, AND R. A. HUNTER. 1976. Abnormal chicks and PCB residue levels in eggs of colonial birds on the lower Great Lakes (1971-73). *Auk* 93: 434-442.
- GOCHFELD, M. 1972. Avian abnormalities and the scientific literature. *American Birds* 26: 705.
- . 1975. Developmental defects in common terns of western Long Island, New York. *Auk* 92: 58-65.
- HAYS, H., AND R. W. RISEBROUGH. 1972. Pollutant concentrations in abnormal young terns from Long Island Sound. *Auk* 89: 19-35.
- PARKES, K. C. 1969. On abnormally crossed mandibles in birds. *Wilson Bulletin* 81: 342.
- POMEROY, D. E. 1962. Birds with abnormal bills. *British Birds* 55: 49-72.

- RAMADE, F. 1982. *Éléments d'écologie: Écologie appliquée*. McGraw-Hill Book Co., Auckland, New Zealand, 600 pp.
- THRELFALL, W. 1968. A herring gull chick (*Larus argentatus*) with an abnormal bill. *Auk* 85: 506–508.
- . 1969. Anomalous conditions in three species of birds. *Canadian Field-Naturalist* 83: 384–388.
- TWEIT, R. C., K. B. BURK, S. M. RUSSELL, J. B. TRUAN II, AND P. M. WALTERS. 1983. Incidence of crossed bills in Inca doves. *North American Bird Bander* 8: 12.

Received for publication 18 March 1987.