



DEVELOPMENTAL OCULAR DISEASE OF RAPTORS

Authors: Buyukmihci, Nedim C., Murphy, Christopher J., and Schulz, Terry

Source: Journal of Wildlife Diseases, 24(2) : 207-213

Published By: Wildlife Disease Association

URL: <https://doi.org/10.7589/0090-3558-24.2.207>

BioOne Complete (complete.BioOne.org) is a full-text database of 200 subscribed and open-access titles in the biological, ecological, and environmental sciences published by nonprofit societies, associations, museums, institutions, and presses.

Your use of this PDF, the BioOne Complete website, and all posted and associated content indicates your acceptance of BioOne's Terms of Use, available at www.bioone.org/terms-of-use.

Usage of BioOne Complete content is strictly limited to personal, educational, and non - commercial use. Commercial inquiries or rights and permissions requests should be directed to the individual publisher as copyright holder.

BioOne sees sustainable scholarly publishing as an inherently collaborative enterprise connecting authors, nonprofit publishers, academic institutions, research libraries, and research funders in the common goal of maximizing access to critical research.

DEVELOPMENTAL OCULAR DISEASE OF RAPTORS

Nedim C. Buyukmihci,¹ Christopher J. Murphy,² and Terry Schulz³

¹ Department of Surgery, School of Veterinary Medicine,
University of California, Davis, California 95616, USA

² Veterinary Medical Teaching Hospital, School of Veterinary Medicine,
University of California, Davis, California 95616, USA

³ Department of Medicine and Raptor Center, School of Veterinary Medicine,
University of California, Davis, California 95616, USA

ABSTRACT: Sixteen raptors, including one eagle, two falcons, five hawks and eight owls, were found to have developmental ocular lesions. The most common lesion was microphthalmia. Other findings included cataract, microphakia, retinal dysplasia, malformation of the ciliary body, choroid and pecten, and lentoid formation. Specific causes for these lesions could not be determined. It is hypothesized that developmental ocular disease probably is more common than available reports indicate.

Key words: Raptors, falcons, hawks, owls, eagles, developmental ocular disease, microphthalmia, cataract, case studies.

INTRODUCTION

Although ocular lesions are frequently encountered during examination of birds of prey (Murphy et al., 1982; Buyukmihci, 1985), there are few reports describing developmental ocular disease. In one report (Lord, 1956), anterior and posterior colobomas in hawks were mentioned briefly. Retinal dysplasia (Dukes and Fox, 1983; Murphy et al., 1985) and partial eyelid agenesis (Kern et al., 1985) were reported in falcons. Bilateral keratopathy, possibly of developmental origin, was reported in a barred owl (*Strix varia*) (Murphy et al., 1981).

This paper describes ocular lesions presumed to be of developmental origin in 16 raptors, representing several species.

MATERIALS AND METHODS

The 16 birds in this report (see Table 1) were examined as part of a continuing project to determine the prevalence and types of ocular disease in raptors. The period of this study was from 1977 through 1986. Many of the birds initially were brought to a raptor rehabilitation center or zoologic garden, or were part of captive propagation projects. The states involved included California, Missouri, New York, Tennessee and Texas. There was no preponderance of birds from any one region of a particular state. Live birds were examined by direct and indirect ophthalmoscopy, and by biomicroscopy. A mydriatic was not used. Vision was assessed by whether or not the bird reacted to

moving objects. One bird was found dead, and one had been euthanatized and its entire body preserved in 10% buffered formalin prior to presentation for ophthalmologic examination. An additional four birds were euthanatized because they were judged to be incapable of surviving in a wild (free-living) situation. The eyes of these six birds, as well as an eye from a kestrel (*Falco sparverius*) enucleated prior to the bird's release, were examined grossly and microscopically. Except for the bird whose body had been preserved in formalin, the eyes were fixed either in Zenker's acetic acid solution or Bouin's fixative. The eyes were opened in a parasagittal plane. After paraffin embedding, histologic sections were made in a plane that would include pupil, optic disk and pecten if these structures existed. The sections were stained using hematoxylin and eosin or the periodic acid-Schiff reaction.

Lesions were determined to be developmental if they could only have occurred as a developmental defect, or if there was a reasonable degree of confidence that they resulted from maldevelopment. In the latter case, a young age and lack of other findings indicative of trauma strengthened the conviction that the primary lesion occurred prior to hatching. Many of the birds had additional ocular problems of an acquired nature.

RESULTS

Microphthalmia was the most commonly encountered developmental lesion in this series of birds (Table 1). The highlights and unique features of some of the birds are discussed in the following case reports (refer to Table 1).

TABLE 1. Congenital ocular disease in raptors.

Case no.	Species	Age at capture	Sex	Ocular diagnoses	Nonocular diagnoses	Disposition
1	Golden eagle <i>Aquila chrysaetos</i>	Subadult	Unknown	OD: ^a microphthalmia; cataract; iridocyclitis OS: ^a normal	Fracture of right humerus with malunion	In captivity
2	Cooper's hawk <i>Accipiter cooperii</i>	Subadult	Unknown	OD: microphthalmia; cataract; microphakia; posterior synechia OS: corneal melanosis; keratitis; microphakia; uveitis; retinal and optic nerve degeneration; focal retinal separation	None	Euthanatized
3	Red-shouldered hawk <i>Buteo lineatus</i>	Juvenile	Unknown	OU: ^a maldevelopment of ciliary body, choroid and pecten; retinal dysplasia, degeneration, separation and detachment; choroiditis; optic nerve degeneration; inflammation and degeneration of pecten; lentoid formation	None	Euthanatized
4	Red-shouldered hawk	Juvenile	Unknown	OU: maldevelopment of ciliary body, choroid and pecten; retinal dysplasia, degeneration, separation and detachment; choroiditis; optic nerve degeneration; inflammation and degeneration of pecten; lentoid formation	None	Euthanatized
5	Red-tailed hawk <i>Buteo jamaicensis</i>	Juvenile	Unknown	OD: normal OS: microphthalmia; retinal separation	Fracture of left radius	Fracture healed, released to wild
6	Kestrel <i>Falco sparverius</i>	Juvenile	Female	OD: ankyloblepharon; megalophthalmos; keratitis; anterior synechia; iritis; cataract; retinal separation, degeneration and dysplasia OS: normal	None	Enucleated, released to wild
7	Peregrine falcon <i>Falco peregrinus</i>	Nestling	Male	OU: cataract; microphakia	None	In captivity
8	Peregrine falcon	Nestling	Female	OU: retinopathy (almost extinct electroretinogram)	None	In captivity

TABLE 1. Continued.

Case no.	Species	Age at capture	Sex	Ocular diagnoses	Nonocular diagnoses	Disposition
9	Barn owl <i>Tyto alba</i>	Juvenile	Male	OU: microphthalmia OS: maldevelopment of pecten	None	Released to wild
10	Barn owl	Juvenile	Unknown	OU: severe microphthalmia or anophthalmia	None	In captivity
11	Great horned owl <i>Bubo virginianus</i>	Juvenile	Unknown	OD: microphthalmia; uveal dysplasia; retinal dysplasia and degeneration; lentoid formation OS: normal	None	Euthanatized
12	Great horned owl	Juvenile	Unknown	OU: cataract (resorbing); microphakia; low amplitude electroretinogram	None	In captivity
13	Screech owl <i>Otus asio</i>	Adult	Unknown	OD: normal OS: congenital cystic eye	None	Found dead
14	Screech owl	Juvenile	Unknown	OU: cataract (resorbing)	None	In captivity
15	Screech owl	Juvenile	Unknown	OU: cataract (resorbing)	None	In captivity
16	Screech owl	Nestling	Unknown	OU: microphthalmia; uveal and retinal dysplasia	None	Euthanatized

* OD = right eye, OS = left eye, OU = both eyes.

Cases 3 and 4

These two red-shouldered hawks (*Buteo lineatus*) were nest mates with two others who had fledged normally. These birds were found at the base of the nest tree. Both birds were blind and had bilateral extensive retinal separation with tears. The pupils were dilated and did not respond to light.

Because the birds were not considered capable of fending for themselves if released to the wild, they were euthanatized. Histologically, the sensory retina was separated from the retinal epithelium. There were various degrees of malformation of primarily the outer layers of the sensory retina. In some regions photoreceptor cells were absent. Where they were present, the photoreceptor outer segments were not recognized and inner segments were vesiculated or diminutive. There were regions of general disorganization of the sensory retina characterized by folds or

admixtures of photoreceptor cell bodies with those of the inner nuclear layer. Material which appeared to be the result of aborted attempts at producing lens material (lentoids) was situated on the outer edge of the sensory retina, or was within the outer layers (Fig. 1). Lentoids and cells similar to retinal epithelial cells were situated on the pecten surface further suggesting a defect in the development of the retina. There was duplication of the retinal epithelium in some regions.

Case 13

This adult screech owl (*Otus asio*) was found dead. Although the left eye was not visible, the left orbit was about the same size as the right orbit. The eyelids were malformed and there was a tiny palpebral fissure. There was a shallow conjunctival cul-de-sac. Deep within the orbit was a pigmented, cystic structure about 3 mm in diameter. It was attached to the eyelid

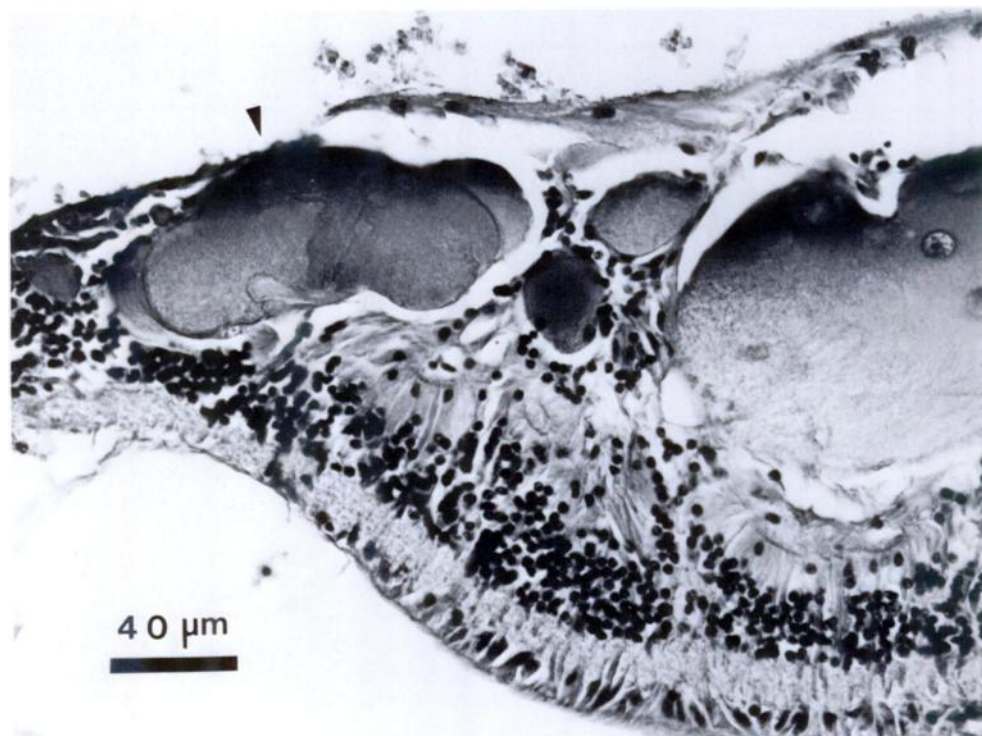


FIGURE 1. Photomicrograph of retina from a red-shouldered hawk oriented with scleral or outer aspect at top. Notice the lentoid situated on the edge of the outer retinal layers (arrowhead) and absence of normal photoreceptors. H&E.

and conjunctival tissues by strands of fibrous tissue. Histologically, it was composed of a single layer of epithelium in which the quantity of melanin varied, surrounded by vascular tissue which contained melanin and which in turn was incompletely surrounded by hyaline cartilage. Completely encircling this was dense connective tissue. Although most of the melanin in the epithelial layer was composed of pleomorphic granules, scattered ovoid rods similar to retinal epithelial melanin also were present. Within the cystic space were a few strands of vascular tissue containing abundant melanin, some of which were attached to the inner lining of the cyst. Surrounding the cyst were bundles of striated muscle fibers.

Cases 14 and 15

These unrelated juvenile screech owls were found blind, 2 yr apart. Each ap-

parently had recently fledged but could not fly or feed due to visual impairment caused by bilateral cataracts. The opacification of the lenses was diffuse and moderately dense preventing visualization of deeper structures in either bird.

The older bird had been examined repeatedly over a period of 3 yr and the younger bird for 12 mo. In the older bird, much of the opaque lens cortex apparently became liquefied and underwent considerable resorption within 3 mo resulting in a gradual return of transparency in this region. Only a large, central, opaque zone was evident in each lens. There was a corresponding reduction in the anteroposterior dimension of each lens, and the irises bowed posteriorly. A view of the ocular fundi was prevented by pupillary constriction to light. By 1 yr, there was further resorption of the cortex of the lenses. The anterior chambers were deeper, and a small

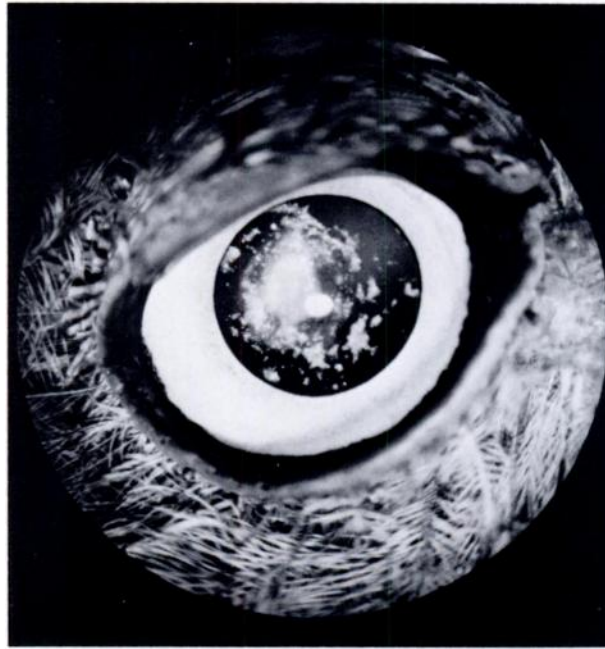


FIGURE 2. Resorbing cataractous lens in screech owl. This photograph was taken 1 yr after complete opacification of the lens was noticed.

central opacity, representing the lens nucleus, was evident in each eye (Fig. 2). Peripherally, the anterior and posterior portions of the lens capsules were transparent and nearly apposed. Within this region were a few crystalline flakes of cortical material. The ocular fundi were visible and seemed normal. Although the owl had some vision, it still would not navigate a flight cage nor catch prey.

The lenses of the younger owl had undergone similar changes during 12 mo of observation. This bird also had some vision, but did not navigate a flight cage nor catch prey.

Case 16

This screech owl and two nest mates were found under a tree and were delivered to a local zoo. The age of this owl was estimated to be 3 wk at that time. There were no discernible eyes and the palpebral fissures were small. This bird was housed with four other fledgling owls. It competed successfully with its cage mates and grew at a comparable rate. Because it could not

be released and be expected to survive in the wild, it was euthanatized at about 3 mo of age.

Dissection of the head revealed an abnormal cranial outline due to the lack of discernible globes (Fig. 3). The interorbital septum was normally formed. Each orbit contained an oval, pigmented mass about 7 mm along the longer axis, firmly adherent to the orbital wall, adjacent to the optic foramen. Each mass consisted of severely disorganized uveal and neural elements within a fibrous coat which, though lacking scleral ossicles, contained a scleral cartilage lamina.

DISCUSSION

The prevalence of developmental ocular disorders in raptors is probably grossly underestimated. Although bilaterally blind birds can apparently successfully compete for food when in the nest (cases 3, 4, 10 and 16; Table 1), ocular malformation of a severe nature is expected to severely diminish the chance of a bird surviving beyond fledging. Therefore, birds affected in

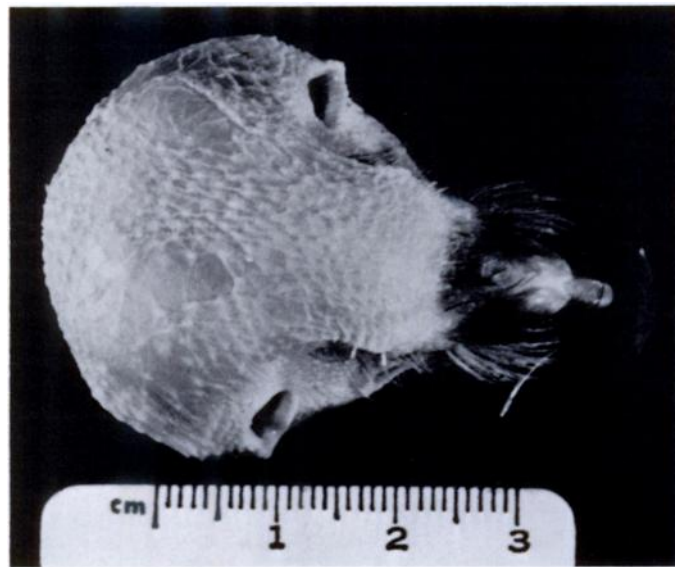


FIGURE 3. Head of screech owl with bilateral microphthalmia; the feathers have been removed. Note the small palpebral fissures and the caudal displacement of the eyelids due to absence of normal sized globes.

this manner probably would die and never be seen by human beings. Minor lesions might not result in significant loss of ocular function allowing the birds to live a normal life. If these birds were captured for reasons other than ocular dysfunction, these minor lesions might be overlooked. Moreover, some owls have been shown to be capable of locating prey items in absolute darkness using only auditory cues (Payne, 1971). This uncanny capability may lessen the impact of minor visual disturbances in this group of predatory birds. Even major lesions might not come to our attention if they were unilateral since it is clear that some raptors having the use of only one eye still can procure food and survive (Lord, 1956; Murphy et al., 1982; Buyukmihci, 1985; Murphy, 1987).

Microphthalmia was the most prevalent developmental lesion seen in this series of raptors. There can be several types of microphthalmia, the least severe of which simply is a small, otherwise normal eye referred to as nanophthalmos. None of the birds in this series were of this category. In other forms of microphthalmia, there usually is some degree of disorganization

of the various tissues that compose the eye. Cataract, retinal and uveal dysplasia, optic nerve hypoplasia, and various colobomas (focal absence of ocular tissue) may impede or prevent vision in the affected eye. Some of these conditions were present in the microphthalmic birds reported here.

Although the underlying cause of microphthalmia in these birds is open to speculation, it is known that disturbances of optic vesicle involution or embryonic fissure closure from a variety of causes can prevent the eye from enlarging to its normal size (Duke-Elder, 1964). The presence of a lens and a retina which had differentiated into sensory and epithelial components suggests that there was normal involution of the optic vesicle in these microphthalmic globes. In addition, we did not see colobomas which would have indicated failure of closure of the embryonic fissure.

Cataracts occurred frequently, either alone or in conjunction with other lesions in this series of birds. Some of them (cases 7, 12, 14 and 15) could have been developmental in origin whereas the remainder had associated intraocular inflammation

that may have been the cause. Cataracts occur frequently in free-living raptors secondary to trauma (Murphy et al., 1982; Brooks et al., 1983). Bilateral cataracts have been reported in juvenile screech owls (Kern et al., 1984; Murphy, 1987). In one of these birds (Murphy, 1987), the cataracts began as punctate posterior subcapsular opacities, progressed to involve a small portion of the posterior cortex, and then remained static. Their visual significance diminished as the bird continued to grow with concomitant enlargement of the eyes. Bilateral cataracts also have been reported in a barred owl (*Strix varia*) (Greenwood and Barnett, 1980).

The resorbing cataracts found in one great horned owl (*Bubo virginianus*) and two screech owls (cases 12, 14 and 15; Table 1) are noteworthy because we are not aware of other reports documenting this process in any species of bird. Although resorption of cataractous lens cortex would not restore accommodation in the affected eye, it may restore vision. The presence of a resorptive process suggests that a satisfactory visual outcome, albeit not sufficient for release of the bird, may be obtained by "tincture of time" as well as by surgical intervention. If time is not a critical factor in a particular case, we recommend that a period of observation of at least 6 mo be allowed before corrective surgery is attempted in young raptors with cataracts.

Most of the findings in this series of raptors may constitute isolated anomalies. There were insufficient numbers to suggest a common cause for any of the malformations.

ACKNOWLEDGMENTS

We thank the following individuals for referral of some of the cases reported herein: Dave Black, University of Tennessee; Dennis V. Hacker, University of California; Mike Murray, Monterey, California; Brian Walton, Santa Cruz Predatory Bird Research Center; Tom Buchanan, Abilene Zoo; and Ginny Crossett, St. Louis Zoo.

LITERATURE CITED

- BROOKS, D. E., C. J. MURPHY, K. E. QUESENBERRY, AND M. T. WALSH. 1983. Surgical correction of a luxated cataractous lens in a barred owl. *Journal of the American Veterinary Medical Association* 183: 1298–1299.
- BUYUKMIHCI, N. C. 1985. Lesions in the ocular posterior segment of raptors. *Journal of the American Veterinary Medical Association* 187: 1121–1124.
- DUKE-ELDER, S. 1964. System of ophthalmology. Vol. 3. Normal and abnormal development. Part 2: Congenital deformities. C. V. Mosby Company, St. Louis, Missouri, 1190 pp.
- DUKES, T. W., AND G. A. FOX. 1983. Blindness associated with retinal dysplasia in a prairie falcon, *Falco mexicanus*. *Journal of Wildlife Diseases* 19: 66–69.
- GREENWOOD, A. G., AND K. C. BARNETT. 1980. The investigation of visual defects in raptors. In *Recent advances in the study of raptor diseases*, J. Cooper and A. G. Greenwood (eds.). Chiron Publications, West Yorkshire, England, pp. 131–135.
- KERN, T. J., C. J. MURPHY, AND W. R. HECK. 1985. Partial upper eyelid agenesis in a peregrine falcon. *Journal of the American Veterinary Medical Association* 187: 1207.
- , ———, AND R. C. RIIS. 1984. Lens extraction by phacoemulsification in two raptors. *Journal of the American Veterinary Medical Association* 185: 1403–1406.
- LORD, R. D. 1956. An anomalous condition in the eye of some hawks. *The Auk* 73: 457.
- MURPHY, C. J. 1987. Raptor ophthalmology. *Compendium on Continuing Education for the Practicing Veterinarian* 9: 241–260.
- , T. J. KERN, E. LOEW, N. C. BUYUKMIHCI, R. W. BELLHORN, A. DELAHUNTA, W. HECK, AND D. L. GRAHAM. 1985. Retinal dysplasia in a hybrid falcon. *Journal of the American Veterinary Medical Association* 187: 1208–1209.
- , ———, AND D. M. MACCOY. 1981. Bilateral keratopathy in a barred owl. *Journal of the American Veterinary Medical Association* 179: 1271–1273.
- , ———, K. MCKEEVER, L. MCKEEVER, AND D. MACCOY. 1982. Ocular lesions in free-living raptors. *Journal of the American Veterinary Medical Association* 181: 1302–1304.
- PAYNE, R. S. 1971. Acoustic location of prey by barn owls (*Tyto alba*). *Journal of Experimental Biology* (London) 54: 535–573.

Received for publication 27 April 1987.