



Schistosomiasis and Nutritional Myopathy in a Brazilian Tapir (*Tapirus terrestris*)

Authors: Yamini, Behzad, and Veen, T. W. Schillhorn van

Source: Journal of Wildlife Diseases, 24(4) : 703-707

Published By: Wildlife Disease Association

URL: <https://doi.org/10.7589/0090-3558-24.4.703>

BioOne Complete (complete.BioOne.org) is a full-text database of 200 subscribed and open-access titles in the biological, ecological, and environmental sciences published by nonprofit societies, associations, museums, institutions, and presses.

Your use of this PDF, the BioOne Complete website, and all posted and associated content indicates your acceptance of BioOne's Terms of Use, available at www.bioone.org/terms-of-use.

Usage of BioOne Complete content is strictly limited to personal, educational, and non - commercial use. Commercial inquiries or rights and permissions requests should be directed to the individual publisher as copyright holder.

BioOne sees sustainable scholarly publishing as an inherently collaborative enterprise connecting authors, nonprofit publishers, academic institutions, research libraries, and research funders in the common goal of maximizing access to critical research.

Schistosomiasis and Nutritional Myopathy in a Brazilian Tapir (*Tapirus terrestris*)

Behzad Yamini and T. W. Schillhorn van Veen, Animal Health Diagnostic Laboratory, Department of Pathology, Michigan State University, East Lansing, Michigan 48824, USA

ABSTRACT: Gross lesions suggestive of severe hepatointeropathy and myopathy were noted in a 4.5-yr-old Brazilian tapir (*Tapirus terrestris*) from a zoo in Michigan (USA). The major microscopic lesions were granulomatous hepatitis and hemorrhagic enteritis associated with non-operculated eggs compatible with those of the Schistosomatidae (Digenea). Skeletal muscle and tongue contained foci of severe acute myodegeneration and necrosis. The hepatic vitamin E value of 1.3 ppm dry weight was considered critically low.

Key words: Tapir, schistosomiasis, myodegeneration, vitamin E, *Tapirus terrestris*, *Heterobilharzia americana*, case history, zoo.

A male Brazilian tapir (*Tapirus terrestris*) was born in captivity in Jackson, Mississippi (USA) and lived for some time in Jacksonville, Florida (USA) and at an Ohio zoo. The tapir arrived at the John Ball Park Zoo (Grand Rapids, Michigan 49504, USA) in June 1985 when it was approximately 3.5 yr old; it was housed indoors in a holding area. The tapir's previous medical history was unremarkable, except for occasional episodes of bloody diarrhea.

On 9 February 1986, the animal appeared to be lethargic and anorectic and had dark red urine and bloody diarrhea. The animal was treated with 4 ml polyflex (Ampicillin, Bristol-Myers Animal Health, Evansville, Indiana 47721, USA) intramuscularly, but it died on 11 February 1986.

At necropsy, the lungs were diffusely congested and had scattered areas of emphysema and atelectasis. The liver was firm and contained scattered yellow pale foci, approximately 2 to 4 mm in diameter. The stomach and small and large intestine were diffusely hyperemic and edematous, with petechial hemorrhages on the serosal sur-

faces. The contents of the small intestine were hemorrhagic and mucoid. The kidneys were swollen and dark brown, and contained scattered petechial hemorrhages. Skeletal muscle and myocardium were pale.

Microbiologic and parasitologic examinations were not remarkable. Using multielemental analysis inductively coupled organ plasma spectrometer (ICP) (Jerrrel-Ash Model 955 Atom Comp spectrometer; Boston, Massachusetts 02402, USA) (Fassel, 1978), concentrations of elements in the kidney and liver were found to be within expected ranges for equine and porcine values (Braserton et al., 1981; Stowe et al., 1986). Vitamin E and selenium levels in the liver were 1.3 ppm (normal >10 ppm) and 1.20 ppm (normal >1.20 ppm), respectively (the normal equine and porcine values established at the Animal Health Diagnostic Laboratory, Michigan State University, East Lansing, Michigan 48224, USA).

Tissues from all major organ systems, including the brain, were fixed in neutral-buffered 10% formalin, embedded in paraffin, sectioned at 6 μ m and stained with hematoxylin and eosin. Histologically, the liver contained multifocal granulomas, predominantly in portal triads and, to a lesser extent, randomly scattered throughout the parenchyma. The granulomas consisted of numerous eosinophils, macrophages, epithelioid cells, lymphocytes and plasma cells associated with multinucleated giant cells and fibroblasts. Some of the granulomas contained non-operculated eggs (Fig. 1), approximately 75 μ m in length, which appeared to be non-oper-

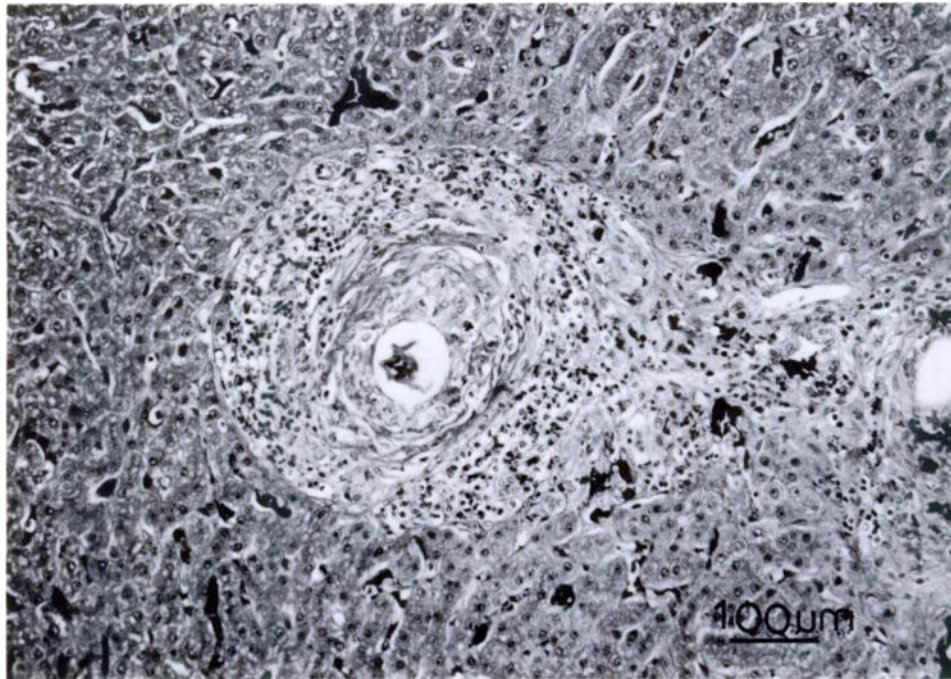


FIGURE 1. Granulomatous hepatitis in a tapir with schistosomiasis. Note typical advanced circumoval granuloma with centrally located schistosome egg, zone of epithelioid cells, and outer zone of fibrous connective tissue infiltrated by lymphocytes, eosinophils and plasma cells. H&E.

culated. The eggs had yellow-brown hyaline shells. Most of the eggs contained an embryo, which appeared to have been viable at the time of fixation. Most of the portal triads and periportal areas were distorted due to the inflammatory cell infiltration and fibrosis. The stomach and intestines contained multifocal areas of hemorrhage in the mucosa. There were diffuse submucosal edema and hemorrhage associated with vasculitis, fibrinoid necrosis and an inflammatory cell infiltration consisting predominantly of eosinophils, macrophages, lymphocytes and plasma cells. Some of the villi of the small intestine had numerous parasite eggs (Fig. 2) in the lamina propria, similar to those seen in the liver. The kidney had an extensive tubular degeneration and many renal tubules contained granular eosinophilic casts. The skeletal and tongue muscles contained foci of severe acute myodegeneration and necrosis (Fig. 3) characterized by myofibrillar swelling, vacuolation, dis-

integration, loss of cross-striation and hyalinization. Schistosomal hepatoenteritis and nutritional myopathy were diagnosed, based on histologic examination.

Schistosomiasis is a debilitating disease caused by adult digeneans (family Schistosomatidae) in the blood vessels (Soulsby, 1982) and eggs deposited in the tissue. Although common in the tropics, schistosomiasis as a clinical disease is rare in mammals in North America (Jones and Hunt, 1983). The most common species of schistosomes that infect mammals in the United States are *Schistosomium douthitti* which occurs mainly in rodents and lagomorphs and *Heterobilharzia americana*. The latter has been recovered from naturally occurring infections in the bobcat (*Lynx rufus*) (Miller and Harkema, 1960), raccoon (*Procyon lotor*) (Lee, 1962a), coyote (*Canis latrans*) (Malek et al., 1961; Custer and Pence, 1981), red wolf (*Canis rufus*) (Custer and Pence, 1981), nutria (*Myocastor coypus*) (Lee, 1962b), opos-

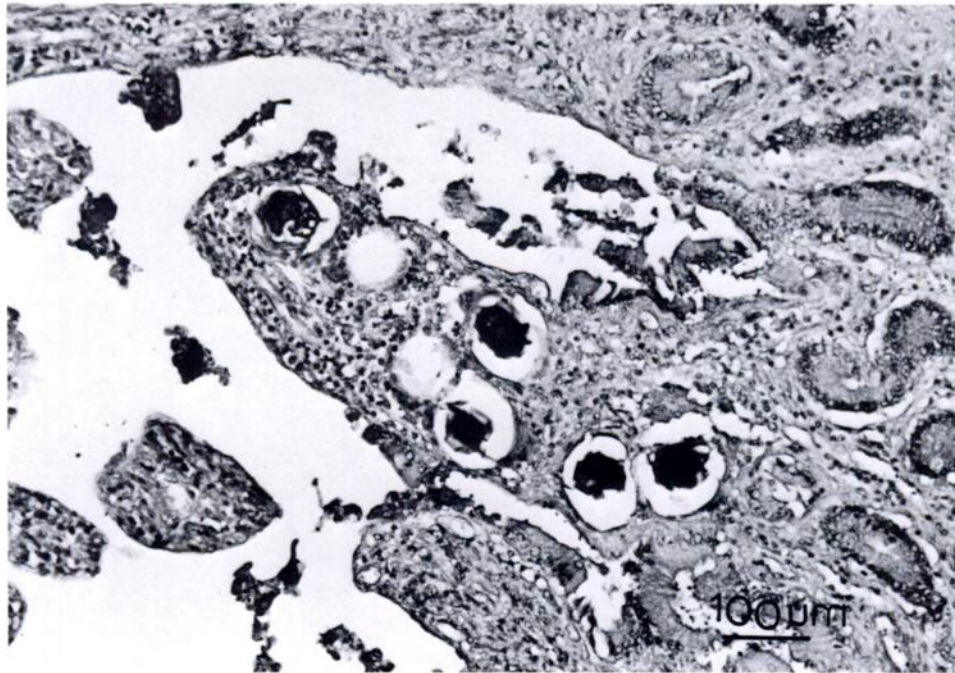


FIGURE 2. Schistosome eggs and mixture of inflammatory cells in the lamina propria of small intestinal villus of a tapir. H&E.

sum (*Didelphis virginiana*) (Kaplan, 1964), white-tailed deer (*Odocoileus virginianus*) (Davis and Liebke, 1971), and domestic dog (Malek et al., 1961; Pierce, 1963; Trasher, 1964; Feldman and Chester, 1968). *Heterobilharzia americana*, which utilizes snails such as *Lymnaea cubensis* or *Pseudosuccinea columella* as intermediate hosts, is found mainly in the Gulf Coastal region of the United States. The clinical signs and pathologic changes associated with a *H. americana* infection are similar to those described for *Schistosoma mansoni* infection in humans (Goff and Ronald, 1981). Schistosomal lesions are associated with the host's reaction to the eggs, which pass from the adult female in the mesenteric venous plexuses to the lumen of the intestines. During this process, the eggs infiltrate the intestinal wall, or are backwashed through the portal vein and lodged in the periportal tissues of the liver and other organs. Granulomas are formed around the eggs and subsequently progress

to fibrous nodules. In the liver this may result in portal fibrosis.

The history of several episodes of bloody diarrhea, the observed gastroenteritis with hemorrhage and edema and the chronic hepatic syndrome in the tapir we examined are consistent with a diagnosis of intestinal schistosomiasis. The eggs were observed in the liver and intestinal wall. Adult worms were not observed, but they were not specifically examined for at necropsy. They also were not detected in additional sections from the intestinal wall.

Determination of the genus and species of the schistosome in this tapir is speculative; however, because the animal was born and raised in the United States it was probably infected with *H. americana*. This species is not very host specific and has been reported from numerous hosts (Lee, 1962a, b; Custer and Pence, 1981). It is enzootic in the southern United States (Goff and Ronald, 1981).

The very low vitamin E levels in the

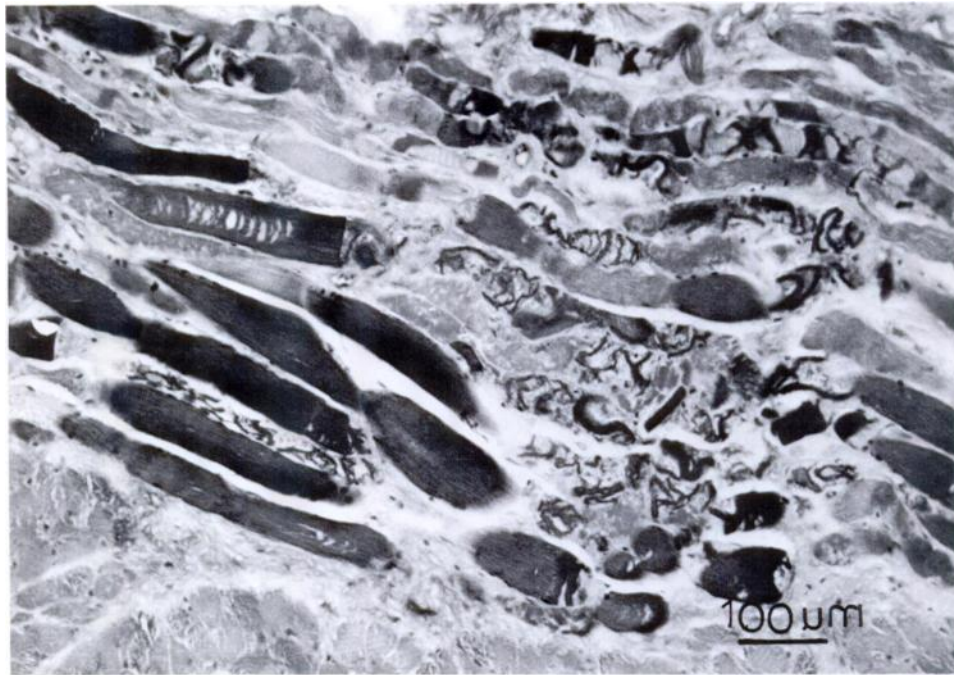

FIGURE 3. Skeletal muscle of a tapir with nutritional myopathy. Note myofibers with vacuolation, disintegration, loss of cross-striation, contraction bands and hyalinization. H&E.

liver of this tapir, in conjunction with the degenerative myopathy of skeletal and tongue muscle and possible myoglobinuric nephrosis, were consistent with nutritional myopathy due to vitamin E deficiency. Schistosomiasis and myopathy due to hypovitaminosis E are recognized as significant problems in both domestic and wild animals. Our findings suggest that the tapir should be considered among these species.

LITERATURE CITED

- BRASELTON, W. E., Q. MEERDINK, H. D. STOWE, AND S. D. TONSAGER. 1981. Experience with multielement analysis in diagnostic clinical toxicology and nutrition. *Proceedings of the American Association of Veterinary Laboratory Diagnosticians* 24: 111-126.
- CUSTER, J. W., AND D. B. PENCE. 1981. Ecological analysis of helminth populations of wild canids from the Gulf coastal prairies of Texas and Louisiana. *The Journal of Parasitology* 67: 289-307.
- DAVIS, J. W., AND K. G. LIEBKE. 1971. *Trematodes: Schistosomiasis, a parasitic disease of wild mammals*. Iowa State University Press, Ames, Iowa, 644 pp.
- FASSEL, V. A. 1978. Quantitative elemental analysis by plasma emission spectroscopy. *Science* 202: 183-191.
- FELDMAN, R. G., AND D. K. CHESTER. 1968. *Heterobilharziasis* in a dog. *Southwestern Veterinarian* 21: 115-118.
- GOFF, W. L., AND N. C. RONALD. 1981. Certain aspects of the biology and life cycle of *Heterobilharzia americana* in east central Texas. *American Journal of Veterinary Research* 42: 1775-1777.
- JONES, T. C., AND R. D. HUNT. 1983. *Veterinary pathology*, 5th ed. Lea and Febiger, Philadelphia, Pennsylvania, 1792 pp.
- KAPLAN, E. H. 1964. *Heterobilharzia americana* in the opossum from Louisiana. *The Journal of Parasitology* 50: 797.
- LEE, H. F. 1962a. Life history of *Heterobilharzia americana*, a schistosome of the raccoon and other animals in the southeastern United States. *The Journal of Parasitology* 48: 728-739.
- . 1962b. Susceptibility of mammalian hosts to experimental infection with *Heterobilharzia americana*. *The Journal of Parasitology* 48: 740-745.
- MALEK, E. A., L. R. ASH, AND H. R. LEE. 1961. *Heterobilharzia* infection in the dog and other mammals in Louisiana. *The Journal of Parasitology* 47: 619-623.
- MILLER, G. C., AND R. HARKEMA. 1960. A new

- locality for *Heterobilharzia americana*. The Journal of Parasitology 46: 206.
- PIERCE, K. R. 1963. *Heterobilharzia americana* infection in a dog. Journal of the American Veterinary Medical Association 143: 496-499.
- SOULSBY, E. J. L. 1982. Helminth, arthropods and protozoa of domestic animals, 7th ed. Lea and Febiger, Philadelphia, Pennsylvania, 809 pp.
- STOWE, H. D., W. E. BRASELTON, AND M. R. SLANKER. 1986. Comparison of equine and porcine multielement profiles of serum, liver, and kidney samples obtained at postmortem. Proceedings of the American Association of Veterinary Laboratory Diagnosticians 29: 441-456.
- TRASHER, J. P. 1964. Canine schistosomiasis. Journal of the American Veterinary Medical Association 144: 1119-1126.

Received for publication 3 August 1987.