



PERIODONTAL DISEASE IN SOUTHERN AFRICAN BUSHPIGS (POTAMOCHOERUS PORCUS) AND WARTHOGS (PHACOCHOERUS AETHIOPICUS)

Author: Woodall, Peter F.

Source: Journal of Wildlife Diseases, 25(1) : 66-69

Published By: Wildlife Disease Association

URL: <https://doi.org/10.7589/0090-3558-25.1.66>

BioOne Complete (complete.BioOne.org) is a full-text database of 200 subscribed and open-access titles in the biological, ecological, and environmental sciences published by nonprofit societies, associations, museums, institutions, and presses.

Your use of this PDF, the BioOne Complete website, and all posted and associated content indicates your acceptance of BioOne's Terms of Use, available at www.bioone.org/terms-of-use.

Usage of BioOne Complete content is strictly limited to personal, educational, and non - commercial use. Commercial inquiries or rights and permissions requests should be directed to the individual publisher as copyright holder.

BioOne sees sustainable scholarly publishing as an inherently collaborative enterprise connecting authors, nonprofit publishers, academic institutions, research libraries, and research funders in the common goal of maximizing access to critical research.

PERIODONTAL DISEASE IN SOUTHERN AFRICAN BUSHPIGS (*POTAMOCHOERUS PORCUS*) AND WARTHOGS (*PHACOCHOERUS AETHIOPICUS*)

Peter F. Woodall

Department of Anatomy, University of Queensland, St. Lucia, Queensland 4067, Australia

ABSTRACT: Periodontal lesions were found in 14 of 100 bushpig (*Potamochoerus porcus*) skulls and nine of 103 warthog (*Phacochoerus aethiopicus*) skulls from southern Africa. The prevalence of periodontal disease showed a significant increase with age in the bushpig but not in the warthog skulls. All the lesions affected the cheek teeth, particularly the molars. The lower prevalence of lesions in older warthogs may be associated with their specialised molars and abrasive diet.

Key words: Bushpig, *Potamochoerus porcus*, warthog, *Phacochoerus aethiopicus*, periodontal disease, dental abnormalities.

INTRODUCTION

Periodontal disease is common in many wild, domestic and feral mammals but it is seldom reported from suids (Colyer, 1936; Anthony, 1950) although Samuel and Woodall (1988) recently found it in over 20% of feral and domestic pigs (*Sus scrofa*) examined in Australia. To extend this latter study, the skulls of wild bushpigs (*Potamochoerus porcus*) and warthogs (*Phacochoerus aethiopicus*) were examined for evidence of periodontal disease.

Bushpigs and warthogs are both widely distributed in Africa but bushpigs prefer moister habitats with dense cover (Smithers, 1983). Bushpigs are omnivorous, rooting for underground rhizomes, bulbs and tubers, earthworms and insect pupae and also feeding on fruit, agricultural crops and carrion (Smithers, 1983). Their dental formula is the same as that of the domestic pig (Nowak and Paradiso, 1983) but their skull differs from that of the pig in several respects (Ewer, 1958).

Warthogs are predominantly selective grazers (Ewer, 1958; Smithers, 1983) although, particularly in winter, they root for the underground rhizomes of grasses (Cumming, 1975). The skull is very modified (Ewer, 1958), as is the dentition with very large canines and unique third molars. These consist of long columns of dentine, encased with a thick enamel layer covered with cementum which packs the columns together (Mason, 1984). The third

molars have semi-persistent pulps and continue to grow for 3 to 4 yr. They are the last teeth to erupt and move progressively forward in the jaw, replacing the rostral premolars and molars (Mason, 1984).

MATERIALS AND METHODS

One hundred bushpig and 103 warthog skulls from various localities in Botswana, Zimbabwe and Zambia in the collection of the Natural History Museum of Zimbabwe (P.O. Box 240, Bulawayo, Zimbabwe) were examined for stage of dentition, irregularities in wear or position of teeth, and the state of the alveolar bone.

The skulls were classified into four groups according to the eruption of the molars and the approximate ages of these groups were estimated using the methods of Sowls and Phelps (1968) for the bushpig and Mason (1984) for the warthog. The times of eruption of bushpig teeth were similar to those recorded for feral pigs by Matschke (1967) and this source was used for estimates of eruption times for the third molar, not given by Sowls and Phelps (1968).

Lesions were scored following the methods of Samuel and Woodall (1988): (1) recession of alveolar crests (Figs. 1, 3), with or without mild localized exostosis, classed as grade 2; and (2) more severe changes with distortion or destruction of alveoli and exposure of tooth roots (Figs. 2, 4) or loss of teeth classed as grade 3. Grade 1, relating to soft tissue lesions, could not be allocated in this study. The presence of supragingival plaque or tartar, the presence of fibre between teeth (Fig. 4), and bony changes associated with the eruption of teeth, were not recorded as pathological changes. All lesions were photographed to allow later confirmation of the grades allocated. For comparisons between species or age-groups, each skull was assigned a grade equal to that of its most severe lesion.

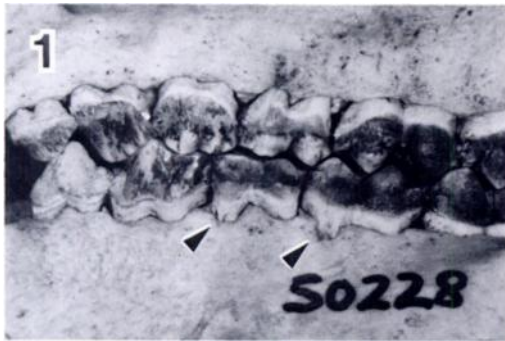

FIGURE 1. Grade 2 lesions of periodontal disease affecting the first and second lower molars of a 22- to 26-mo-old bushpig from the Vumba, Zimbabwe.

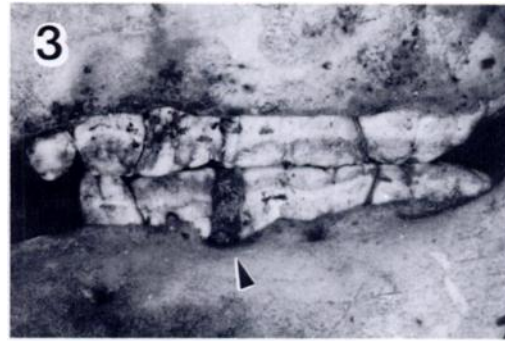


FIGURE 3. Accumulation of fibre between the first and second lower molars and grade 2 lesions at the second lower molar of a 10- to 18-mo-old warthog from Nagupande, Zimbabwe.

Chi-square and Fisher Exact tests (Siegel, 1956) were used to test the significance of differences between species and age classes.

RESULTS

Pathological changes to the periodontal bone were observed in 14% of bushpig skulls and 9% of warthog skulls; this difference was not statistically significant ($P > 0.1$). For both species, the sample of skulls represented a similar distribution of ages (Table 1). The prevalence of periodontal disease showed a significant increase with age for the bushpig ($P < 0.01$) but a much smaller, non-significant increase with age in the warthog. The warthog skulls showed more grade 2 and fewer grade 3 lesions than the bushpig skulls but this was not statistically significant (Fisher Exact Test, $P > 0.05$).

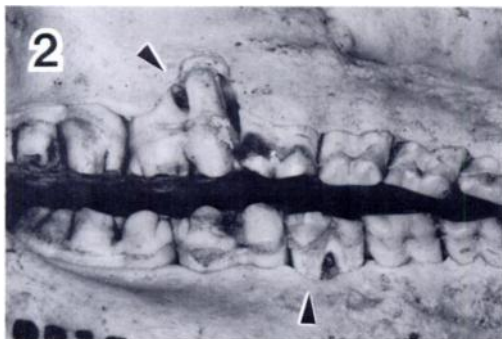


FIGURE 2. Grade 3 lesions at the second upper molar and, less marked, at the first lower molar of a >26-mo-old bushpig from the Victoria Falls rain forest, Zimbabwe.



FIGURE 4. Grade 3 lesions and the accumulation of fibre at the second lower molar of an 18- to 25-mo-old warthog from Nagupande, Zimbabwe. The upper first molar has been lost and part of the crown of the lower first molar is missing without apparent periodontal disease.

All the lesions involved cheek teeth and lesions were not observed around the incisors or canines. The molars were affected significantly more frequently than the premolars in the bushpig ($P < 0.01$) but the fourth premolar was often affected in warthogs (Table 2). Plant fibres and debris were often packed into the cavities formed by erosion around the roots of teeth (Figs. 3, 4).

DISCUSSION

This study has identified periodontal disease in two species of wild African suids, indicating that it is more widespread in suids than previously reported. The prevalence of the disease (grades 2 + 3) was

TABLE 1. Age distribution of periodontal disease in bushpigs and warthogs.

Age class (molar eruption)	Estimated age (mo) ^a	Total sample	% Prevalence of each disease grade ^b	
			2	3

Bushpig				
M1	<13	22	0	0
M2	13–22	18	0	0
M3 erupting	22–26	23	2	0
M3+	>26	37	3	9
Total		100	5	9
Warthog				
M1	<10	13	0	0
M2	10–18	23	2	0
M3 <30 mm	18–25	25	2	1
M3 >30 mm	>25	42	3	1
Total		103	7	2

^a Ages estimated using Sowls and Phelps (1968) for bushpigs and Mason (1984) for warthogs.

^b See text for descriptions of grades of severity.

lower in the bushpigs (14%) and warthogs (9%) than in Australian feral pigs (21%) (Samuel and Woodall, 1988), although the difference was only significant in the case of the warthogs/feral pigs (Chi-square analysis, $P < 0.02$). Warthogs showed a lower overall prevalence of periodontal disease and a lower prevalence of grade 3 lesions than did bushpigs but these differences were not statistically significant.

Bushpigs showed increasing prevalence and severity of periodontal disease with

age (Table 1). Feral pigs show a similar pattern (Samuel and Woodall, 1988) but have evidence of the disease at an earlier age: 16% had grade 2 or 3 lesions at 12 to 22 mo, compared with 0% of bushpigs in this age group.

The molars of feral pigs and bushpigs experience considerable stress and abrasion during mastication, as evidenced by their rapid wear, particularly in the case of the first and second molars which erupt before the third molars and thus are subject to wear for a longer period. In both these species, periodontal disease is most associated with the molars, and its prevalence increases considerably with age.

Warthogs do not show a marked increase in the prevalence or severity of the disease with age. Their highly specialised, high crowned, third molars grow forward from the back of the jaw to replace the first and second molars as these become worn and lost (Mason, 1984). They seem to be adapted for grinding the grass and particularly the tough rhizomes which, with associated soil particles, are very abrasive (Cumming, 1975; Mason, 1984). Their specialised structure may be an important factor in reducing the incidence of periodontal disease in this species compared to feral pigs and bushpigs which have less specialised, bunodont molars. All the lesions affecting the third molar in

TABLE 2. Location of periodontal lesions in bushpigs and warthogs.

Most severe lesion	% Animals with lesions at each site ^a						
	Premolars				Molars		
	1	2	3	4	1	2	3
Bushpig							
2	0	0	2	2	3	3	5
3	0	0	2	2	5	15	8
Sample size ^b	78	60	60	60	78	60	37
Warthog							
2	—	—	0	5	3	6	7
3	—	—	0	2	0	3	0
Sample size ^b			67	42	90	67	42

^a See text for descriptions of grades of severity.

^b Younger animals did not have all teeth erupted, hence the smaller sample sizes for these categories.

warthogs were associated with the rostral end of the tooth where the more rostral molars were being replaced (Fig. 4) so that the process of molar progression and replacement may predispose these locations to periodontal disease.

Periodontal disease is associated with the accumulation of bacterial plaque on the teeth causing a destructive response in the adjacent tissue (Page and Schroeder, 1982). Coarse food may provide some protection against the disease by its abrasive action and by stimulating vigorous chewing (Amand and Tinkelman, 1985). Thus the warthogs' diet may be another factor in reducing the prevalence of periodontal disease in this species.

It is probable that only grade 3 lesions would have interfered with mastication, so this condition would contribute little to the mortality of the population in either species.

ACKNOWLEDGMENTS

I am grateful to H. D. Jackson and A. Kumirai for giving me access to the collections in the Natural History Museum of Zimbabwe, R. Williams for photographic assistance and J. L. Samuel for critical comments on the manuscript. This study was undertaken while I was on a Special Studies Program from the University of Queensland.

LITERATURE CITED

- AMAND, W. B., AND C. L. TINKELMAN. 1985. Oral disease in captive wild animals. In *Veterinary dentistry*, C. E. Harvey (ed.), W. B. Saunders Company, Philadelphia, Pennsylvania, pp. 289–311.
- ANTHONY, D. J. 1950. *Diseases of the pig and its husbandry*, 3rd ed. Balliere, Tindall and Cox, London, England, 309 pp.
- COLYER, F. 1936. *Variations and diseases of the teeth of animals*. John Bale, Sons and Danielsson Ltd., London, England, 750 pp.
- CUMMING, D. H. M. 1975. A field study of the ecology and behaviour of the warthog. Museum memoir No. 7. National Museums Administration, Harare, Zimbabwe, 179 pp.
- EWER, R. F. 1958. Adaptive features in the skulls of African Suidae. *Proceedings of the Zoological Society of London* 131: 135–155.
- MASON, D. R. 1984. Dentition and age determination of the warthog *Phacochoerus aethiopicus* in Zululand, South Africa. *Koedoe* 27: 79–119.
- MATSCHKE, G. H. 1967. Aging European wild hogs by dentition. *The Journal of Wildlife Management* 31: 109–113.
- NOWAK, R. M., AND J. L. PARADISO. 1983. *Walker's mammals of the world*, 4th ed., Vol. 2. Johns Hopkins University Press, Baltimore, Maryland, 1362 pp.
- PAGE, R. C., AND H. E. SCHROEDER. 1982. Periodontitis in man and other animals: A comparative review. Karger, Basel, Switzerland, 330 pp.
- SAMUEL, J. L., AND P. F. WOODALL. 1988. Periodontal disease in feral pigs (*Sus scrofa*) from Queensland, Australia. *Journal of Wildlife Diseases* 24: 201–206.
- SIEGEL, S. 1956. *Nonparametric statistics for the behavioral sciences*. McGraw-Hill, New York, New York, 312 pp.
- SMITHERS, R. H. N. 1983. *The mammals of the Southern African Subregion*. University of Pretoria, Pretoria, Republic of South Africa, 736 pp.
- SOWLS, L. K., AND R. J. PHELPS. 1968. Observations on the African bushpig *Potamochoerus porcus* Linn. in Rhodesia. *Zoologica* 53: 75–84.

Received for publication 8 March 1988.