

OBSERVATIONS ON THE LUNGWORM, PNEUMOSTRONGYLUS CALCARATUS, IN IMP ALA (AEPYCEROS MELAMPUS) FROM SWAZILAND

Authors: Gallivan, G. J., Barker, I. K., Alves, R. M. R., Culverwell, J.,
and Girdwood, R.

Source: Journal of Wildlife Diseases, 25(1) : 76-82

Published By: Wildlife Disease Association

URL: <https://doi.org/10.7589/0090-3558-25.1.76>

BioOne Complete (complete.BioOne.org) is a full-text database of 200 subscribed and open-access titles in the biological, ecological, and environmental sciences published by nonprofit societies, associations, museums, institutions, and presses.

Your use of this PDF, the BioOne Complete website, and all posted and associated content indicates your acceptance of BioOne's Terms of Use, available at www.bioone.org/terms-of-use.

Usage of BioOne Complete content is strictly limited to personal, educational, and non - commercial use. Commercial inquiries or rights and permissions requests should be directed to the individual publisher as copyright holder.

BioOne sees sustainable scholarly publishing as an inherently collaborative enterprise connecting authors, nonprofit publishers, academic institutions, research libraries, and research funders in the common goal of maximizing access to critical research.

OBSERVATIONS ON THE LUNGWORM, *PNEUMOSTRONGYLUS CALCARATUS*, IN IMPALA (*AEPYCEROS MELAMPUS*) FROM SWAZILAND

G. J. Gallivan,¹ I. K. Barker,^{2,6} R. M. R. Alves,³ J. Culverwell,⁴ and R. Girdwood⁵

¹ Department of Biology, University of Swaziland, Private Bag Kwaluseni, Swaziland

² Department of Pathology, Ontario Veterinary College, University of Guelph, Guelph, Ontario, Canada N1G 2W1

³ Veterinary Research Institute, Onderstepoort 0110, Republic of South Africa

⁴ Mbuluzi Nature Reserve, Tambankulu Estates, Private Bag Mhlume, Swaziland

⁵ Mlawula Nature Reserve, Private Bag Simunye, Swaziland

⁶ Author to whom reprint requests should be addressed

ABSTRACT: The lungworm, *Pneumoststrongylus calcaratus*, was found in 85% (164 of 193) of impala (*Aepyceros melampus*) collected in Mlawula Nature Reserve in Swaziland. Infection was confirmed at 4.5 mo of age, and the prevalence increased to 100% at 11 mo, with a prevalence of 98% in animals >1 yr of age. *Pneumoststrongylus calcaratus* was usually found in firm, tan-grey nodules along the lobar borders of the lungs, although an extensive granulomatous pneumonia with miliary caseous abscesses and calcified nodules was observed in some older animals. In the primary infection in lambs, adult parasites, larvae and eggs were observed in the alveoli and bronchioles within the nodule. There was peribronchial and perivascular mononuclear cuffing, with infiltration of mononuclear cells in the alveolar septum in the vicinity of worms. In lesions in older animals, there was local consolidation with macrophages and giant cells, and foci of parenchymal necrosis associated with degenerating eosinophils, which appeared to lead to the formation of eosinophilic granulomas. Resolving lesions caused interstitial fibrosis, with mineralized nodules. Pneumoststrongylosis does not appear to pose a significant threat to the health of impala in Swaziland.

Key words: *Pneumoststrongylus calcaratus*, impala, *Aepyceros melampus*, Swaziland, prevalence, pathology, field study.

INTRODUCTION

Pneumoststrongylus calcaratus is a lungworm of impala (*Aepyceros melampus*) and other antelope in eastern and southern Africa. This fine black parasite is found in yellowish-grey to bluish-grey raised emphysematous or firm areas on the dorsal caudal lobes and along the lobar borders of the lungs (Dinnik and Sachs, 1968; Young and Wagener, 1968; Heinichen-Anderson, 1982). Microscopic description of the lesions is limited to a general description of the lesions associated with *P. calcaratus* and other small protostrongylid lungworms in six species of antelope (Moulton and Sachs, 1970). In the Serengeti, Eastern Transvaal including Kruger National Park, and Natal the prevalence of *P. calcaratus* in impala ranges from 75 to 100% (Ortlepp, 1962; Dinnik and Sachs, 1968; Young and Wagener, 1968; Heinichen, 1973; Anderson, 1983). Ortlepp

(1962) did not find *P. calcaratus* in impala in Swaziland, yet Meeser (1952) stated that it had been reported. In the present study the prevalence of *P. calcaratus* in impala in Swaziland is reported, and the gross and microscopic lesions associated with infection are described.

MATERIALS AND METHODS

The impala were collected during the culling program at Mlawula Nature Reserve (26°12'S, 32°00'E) in northeastern Swaziland. The reserve covers an area of approximately 23,000 ha, and is predominately *Acacia nigrescens*-*Sclerocarya caffra*-*Themeda triandra* savanna (low veld vegetation type 10 of Acocks, 1975). The mean annual rainfall is 610 to 750 mm, with hot, wet summers and cool, dry winters.

One hundred ninety-three impala were collected by shooting from early October 1985 to the end of August 1986, with monthly sample sizes ranging from six to 24 animals. Necropsies were performed at a central abattoir or in the field. The lungs were removed from the carcass, and the presence of *P. calcaratus* was deter-

mined by the observation of gross lesions with parasites. Samples of the lesions were collected in 70% alcohol and 5% glycerin for parasite identification, and in 10% neutral buffered formalin for microscopic examination. Parasites were extracted from the lesions, cleared, and identified using the description of Mönning (1933). Representative examples of the parasites are deposited in the Onderstepoort Helminthological Collection (Veterinary Research Institute, Onderstepoort 0110, Republic of South Africa; Accession numbers S.2444 and S.2445). Tissues for microscopic examination were processed routinely to paraffin wax, sectioned at 6 μ m, and stained with hematoxylin–eosin.

RESULTS

Pneumoststrongylus calcaratus was found in 85% (164 of 193) of the impala. The prevalence was 100% in the ≥ 1 yr age class ($n = 37$) and 98% in the ≥ 2 yr and older age classes ($n = 104$). In the ≥ 0 yr age class ($n = 52$) the prevalence was 48%. There was no evidence of infection in nine lambs examined in January approximately 2.5 mo after birth. Nodules were observed along the lateral border of the caudal lobes of the lung in one of six lambs in February, and in one of four lambs in March. Microscopically, these were eosinophilic granulomas, with fragments of a parasite observed in the nodule from the lamb in March. However, neither case could be confirmed as being due to *P. calcaratus*. Infection was confirmed in two of five lambs in April, approximately 4.5 mo after lambing. In the August sample all five lambs examined were infected, and all six were infected in the October sample.

The most common gross lesions associated with *P. calcaratus* infection were firm tan-grey nodules along the lateral borders of the caudal lobes of the lung, although nodules also were observed along the borders of the cranial lobes and on the dorsal surface (Fig. 1). Small nodules were confined to one or two lobules, while larger nodules involved several adjoining lobules. In 16 of the 104 impala in the ≥ 2 age classes there were adhesions between the lung and thoracic wall. In these cases the lungs were tan in color, and had miliary

abscesses and calcified nodules throughout.

The microscopic lesions associated with *P. calcaratus* infection were variable. In lambs collected in April, adult parasites, embryonating eggs and first stage larvae were observed in large numbers in the alveoli and bronchioles (Fig. 2); these formed a nodule which sometimes compressed the adjacent lung. Nodules were, in part, bordered by the interlobular septa which were thickened with lymphocytes, plasma cells and scattered eosinophils, and there was an accumulation of mononuclear cells under the pleura. Where nodules were not bounded by interlobular septa, the adjacent alveolar septa were thickened with edema fluid and a mixed cellular infiltrate, with some alveolar edema. In some areas within the nodule there was consolidation with a mixed inflammatory infiltrate, including some macrophages and small syncytia, but little reaction was evident around individual nematodes, eggs or larvae. There was marked perivascular and peribronchiolar mononuclear cuffing, with prominent lymphoid follicles.

Parasites in the bronchioles were often associated with excess mucus and degenerate polymorphonuclear inflammatory cells. The bronchiolar epithelium in these areas was hyperplastic and usually devoid of cilia, with mononuclear cells and eosinophils in the epithelium. In lesions from older animals there was accumulation of alveolar macrophages and small giant cells containing ceroid, with mild fibrosis of the alveolar septa and alveolar epithelialization.

More severe lesions were found in adult impala and juveniles >6 mo of age. In these cases the parenchymal architecture in nodules was effaced by eggs, larvae and adult nematodes, and a heavy infiltrate of mononuclear cells, including alveolar macrophages and eosinophils (Fig. 3). Foci of parenchymal necrosis of varying size were heavily infiltrated with degenerate eosinophils, and were associated with apparently non-viable eggs, larvae and adult

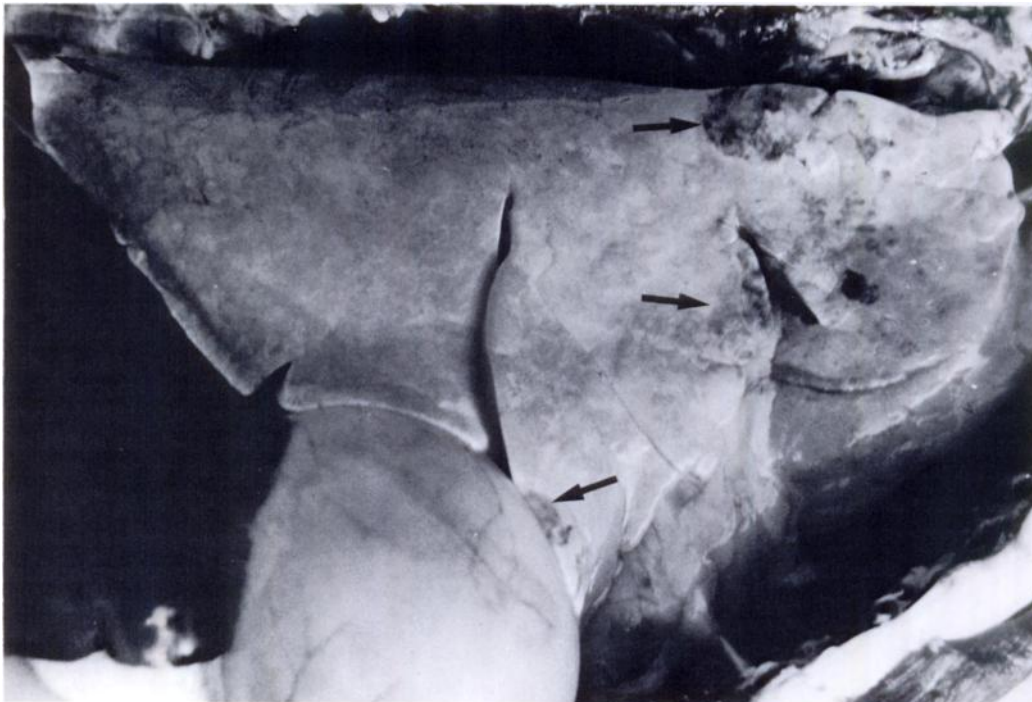


FIGURE 1. Lung of mature male impala with nodules (arrows) observed in a typical *Pneumostrongylus calcaratus* infection.

nematodes. These lesions appeared to evolve to form discrete eosinophilic granulomas walled off by macrophages and giant cells, and associated with a heavy peripheral lymphocyte infiltrate. Parasites

were usually sparse in the lung parenchyma of animals with well developed eosinophilic granulomas and mineralizing debris, although degenerate parasites were often present within the granulomas. In

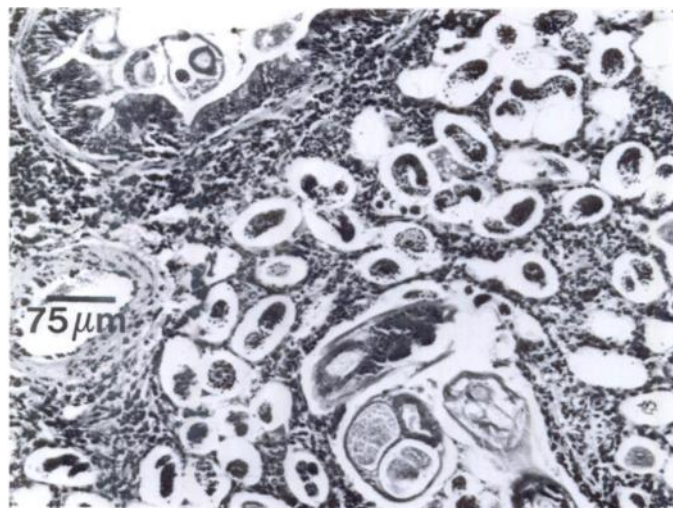


FIGURE 2. Tissue section of a nodule in the lung of an impala lamb approximately 4.5 mo of age, with adult nematodes, larvae and eggs in the alveoli, and peribronchiolitis and periarteritis, with mononuclear infiltrate in the alveolar septa. A nematode is present in the lumen of a bronchiole (top left). H&E.

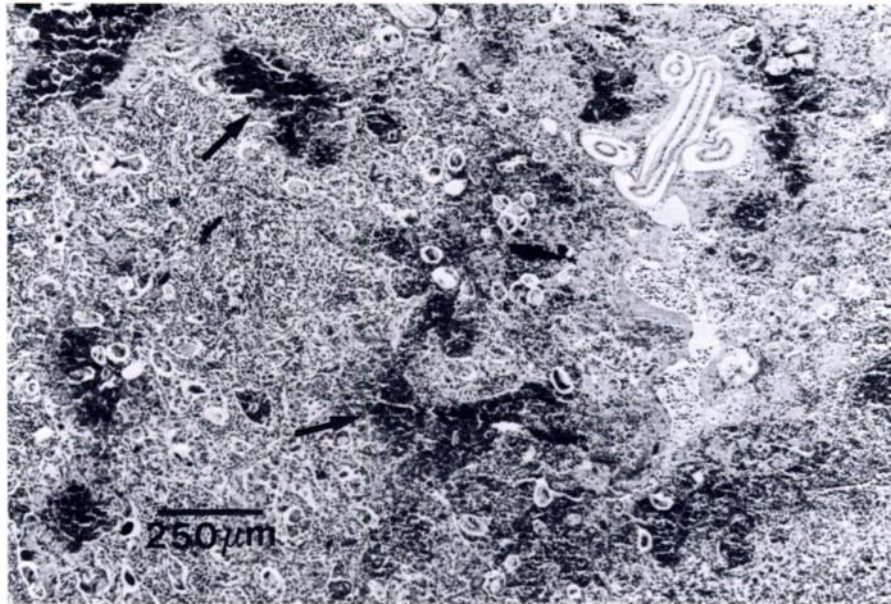


FIGURE 3. Tissue section of a nodule in the lung of an older impala, with consolidation with macrophages and giant cells, and areas of necrosis associated with degenerating eosinophils (arrows). H&E.

the lungs of several adult impala interpreted as having a resolving parasitic pneumonia, there was marked alveolar septal and interlobular fibrosis, with focal

aggregates of macrophages and giant cells, eosinophils or mineralizing eosinophilic granulomas with a well developed mantle of lymphocytes (Fig. 4).

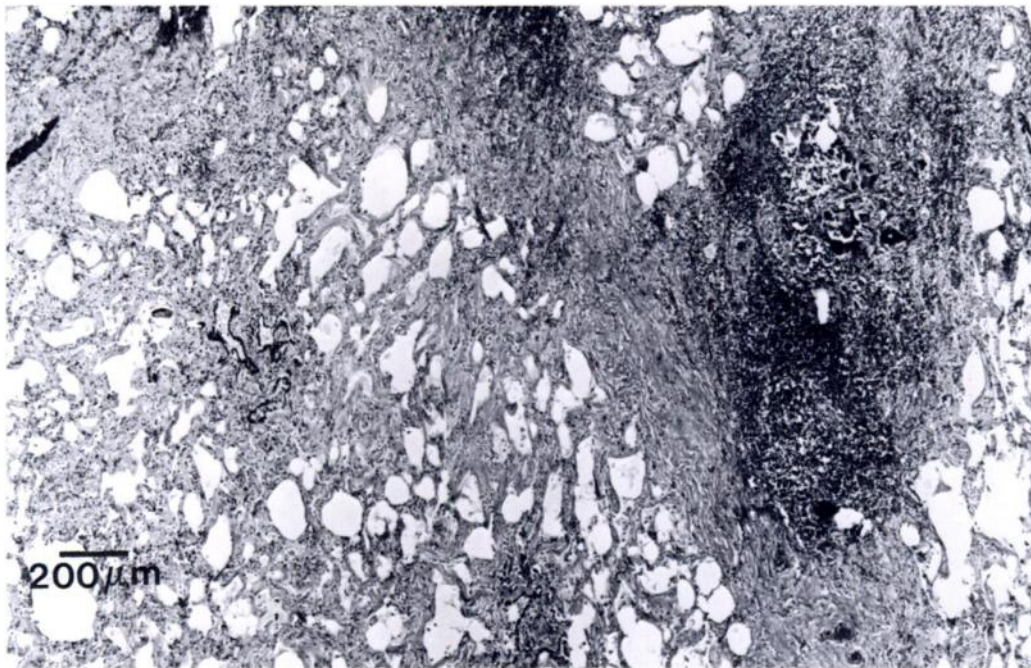


FIGURE 4. Tissue section of lung from an adult impala with a resolving parasitic pneumonia. There is interlobular and alveolar septal fibrosis and a mineralized granuloma with a mantle of lymphocytes. H&E.

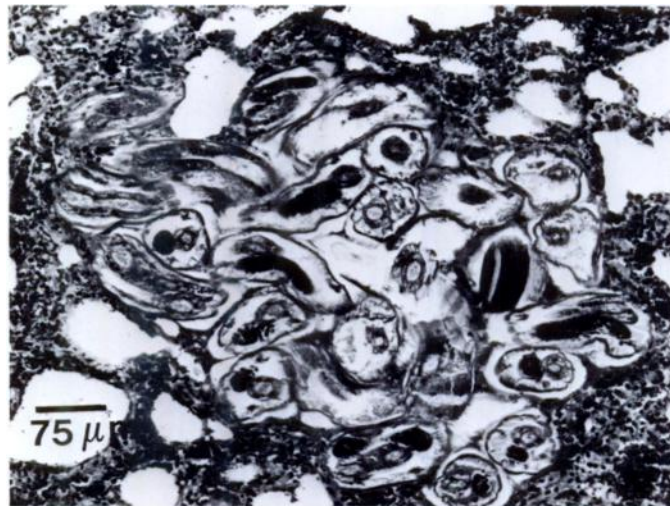


FIGURE 5. Group of adult parasites, presumably *P. calcaratus*, outside the typical nodule. There is some compression of the surrounding lung parenchyma, and a mild edema and cellular response. H&E.

Animals with chronic lesions occasionally had bronchioles obstructed by eosinophils, larvae and necrotic debris, and there was erosion or ulceration of the bronchiolar epithelium. In some severe cases this had developed to bronchiolitis obliterans. The cases with granulomatous lesions typically had associated villous proliferation of the visceral pleura, with prominent mesothelial cells, and in most cases, adhesions between the visceral and parietal pleura.

In several cases, eggs and larvae were observed in alveoli outside the parasitic nodules. These were usually accompanied by edema and a local eosinophilic infiltrate. Small groups of adult nematodes, similar in microscopic appearance to those in the large nodules, also were observed in the lung parenchyma outside the nodules. These nematodes were confined to discrete foci (Fig. 5), which in some instances appeared to be compressing the adjacent parenchyma, and were associated with edema and a local eosinophilic infiltrate. However, in other cases the foci were surrounded by macrophages, fibroblasts and lymphocytes. Mineralizing eosinophilic granulomas centered on small aggregates of degenerate nematodes and corresponded to the palpable presence of miliary nod-

ules approximately 1 mm in diameter in the lung parenchyma.

DISCUSSION

The high prevalence of *P. calcaratus* in impala in Mlawula Nature Reserve is similar to that reported in other areas of eastern and southern Africa (Ortlepp, 1962; Dinnik and Sachs, 1968; Young and Wagener, 1968; Heinichen, 1973; Anderson, 1983), but differs from Ortlepp's (1962) observation at an unspecified location in Swaziland. Horak (1978, 1980) did not report *P. calcaratus* from Nylsvley Nature Reserve in the northern Transvaal or from Pafuri in northeastern Kruger National Park, although Young and Wagener (1968) reported a high prevalence from southern Kruger National Park. Horak (1981) has suggested that *P. calcaratus* is restricted to warm, moist regions. This may explain the discrepancy between the findings in the present study and that of Ortlepp (1962) since several other areas of Swaziland in which impala occur receive considerably less rainfall than Mlawula, or are considerably cooler.

The youngest impala in which *P. calcaratus* infection was confirmed microscopically were approximately 4.5 mo old.

These animals had fully developed adult nematodes and first stage larvae in the lungs. The observation of nodules in the lungs of lambs 2.5 and 3.5 mo of age, and of parasite fragments in a section of lung from the 3.5-mo-old lamb, suggests that infection occurs relatively early in life. The yellow slug (*Elisolimax flavescens*) has been suggested as the intermediate host of *P. calcaratus*, with infection resulting from the ingestion of infected slugs (Heinichen, 1974; Heinichen-Anderson, 1976, 1982). In this situation, infection may occur as early as 1.5 mo of age since lambs were already consuming grass and browse in January (G. J. Gallivan, unpubl. obs.). Little is known of the endogenous development of *P. calcaratus*. Heinichen-Anderson (1976) did not find *P. calcaratus* in impala 18 days after inoculation with third stage larvae, but recorded lesions in a sheep at 51 days and third stage larvae in the lungs of a guinea pig 8 days postinoculation (Heinichen-Anderson, 1982). However, since guinea pigs and sheep are abnormal hosts, the significance of these findings is limited.

The typical gross lesions observed in the present study were similar to those described by Moulton and Sachs (1970) and Heinichen-Anderson (1982). The emphysematous areas described by Young and Wagener (1968) were never observed. Adult parasites, presumably *P. calcaratus*, were observed in eosinophilic granulomas and calcified nodules scattered in the lung parenchyma, indicating that *P. calcaratus* does not always localize in nodules along the lobar borders. This was usually observed in older animals, with only one case in an animal <3-yr-old.

The microscopic lesions were similar to those observed in other metastrongyloid infections (Beresford-Jones, 1967; Moulton and Sachs, 1970; Stockdale, 1976). The wide range of lesions observed in the present study may be due in part to differences in the age of the host and the time of infection coupled with variation in the host response. The general pattern of response

to *P. calcaratus* appears to be similar to that described for *Muellerius capillaris* in sheep (Beresford-Jones, 1967). The initial response involves lymphocytes and macrophages, and a few eosinophils. Later, the accumulation of eosinophils leads to tissue necrosis and death of the parasites, with the formation of granulomas.

The nature of the inflammatory response suggests that impala may acquire immunity to *P. calcaratus*, although immunity may take considerable time to develop. The mechanism of immunity to lungworms is poorly understood and appears to be dependent on the challenge dose. Rose (1973) suggested that the relatively poor immune response to *M. capillaris* in sheep may be due to the fact that under natural conditions they receive continual small doses, rather than the single large doses often used in experimental studies. A similar situation probably occurs in impala, since the median number of larvae in naturally infected *E. flavescens* was only five, with a maximum of 93 (Heinichen-Anderson, 1976). Thus, a widespread granulomatous reaction with walling off of small groups of parasites was observed only in older animals.

While *P. calcaratus* is a common parasite of impala in Mlawula Nature Reserve, it does not appear to be a significant health problem and no clinical signs of pneumonia were observed. In most cases the lesions involved only a small portion of the lung (Fig. 1). The most extensive lesions were in animals with adhesions and granulomatous pneumonia. However, the body condition of these animals did not appear to differ from that of other animals of similar age and sex collected at the same time.

ACKNOWLEDGMENTS

The assistance of G. Dlamini, T. Lapidos, H. Hunter and E. W. Eaton is greatly appreciated. Funding for this project was provided by the Research and Publication Committee, University of Swaziland to GJG. The Swaziland National Trust Commission, Tambankulu Estates and Simunye Sugar Estates kindly provided logistical support.

LITERATURE CITED

- ACOCKS, J. P. H. 1975. Veld types of South Africa. Botanical Survey of South Africa, Memoirs 40: 1-128.
- ANDERSON, I. G. 1983. The prevalence of helminths in impala *Aepyceros melampus* (Lichtenstein 1812) under game ranching conditions. South African Journal of Wildlife Research 13: 55-70.
- BERESFORD-JONES, W. P. 1967. Observations on *Muellerius capillaris* (Müller, 1899) Cameron, 1927. III—Experimental infection of sheep. Research in Veterinary Science 8: 272-279.
- DINNIK, J. A., AND R. SACHS. 1968. A gigantic *Protostrongylus*, *P. africanus* sp. nov., and other lung nematodes of antelope in the Serengeti, Tanzania. Parasitology 58: 819-829.
- HEINICHEN, I. G. 1973. Parasitological studies on impala: Preliminary report. Journal of the South African Veterinary Association 44: 265-269.
- . 1974. Preliminary note on the life cycle of the lungworm, *Pneumostrongylus calcaratus*, Mönnig, 1932. Journal of the South African Veterinary Association 45: 219-220.
- HEINICHEN-ANDERSON, I. G. 1976. Studies on the life cycle of the lungworm, *Pneumostrongylus calcaratus*, Mönnig, 1932. Journal of the South African Veterinary Association 47: 23-27.
- . 1982. The life cycle of the lungworm, *Pneumostrongylus calcaratus*. Journal of the South African Veterinary Association 53: 109-114.
- HORAK, I. G. 1978. Parasites of domestic and wild animals in South Africa. X. Helminths in impala. Onderstepoort Journal of Veterinary Research 45: 221-228.
- . 1980. The incidence of helminths in pigs, sheep, cattle, impala and blesbok in the Transvaal. Ph.D. Dissertation. University of Natal, Pietermaritzburg, Republic of South Africa, 201 pp.
- . 1981. Host specificity and the distribution of the helminth parasites in sheep, cattle, impala and blesbok according to climate. Journal of the South African Veterinary Association 52: 201-206.
- MEESER, M. J. N. 1952. A preliminary survey of the endo- and ectoparasites of the impala—*Aepyceros melampus*. Journal of the South African Veterinary Medical Association 23: 221-223.
- MÖNNIG, H. O. 1933. Wild antelopes as carriers of nematode parasites of domestic ruminants—Part III. Onderstepoort Journal of Veterinary Science and Animal Industry 1: 77-92.
- MOULTON, J. E., AND R. SACHS. 1970. Verminous pneumonia in East African antelopes. Journal of Comparative Pathology 89: 169-172.
- ORTLEPP, R. J. 1962. Lungworms from South African antelopes. Onderstepoort Journal of Veterinary Research 29: 173-181.
- ROSE, J. H. 1973. Lungworms of the domestic pig and sheep. Advances in Parasitology 11: 559-599.
- STOCKDALE, P. H. G. 1976. Pulmonary pathology associated with metastrongyloid infections. British Veterinary Journal 132: 595-608.
- YOUNG, E., AND L. J. J. WAGENER. 1968. The impala as a source of food and by-products. Data on production potential, parasites and pathology of free-living impalas of the Kruger National Park. Journal of the South African Veterinary Medical Association 39: 81-86.

Received for publication 9 May 1988.