

## **A REVIEW OF MARBLE SPLEEN DISEASE OF RING-NECKED PHEASANTS**

Authors: Fitzgerald, Scott D., and Reed, Willie M.

Source: Journal of Wildlife Diseases, 25(4) : 455-461

Published By: Wildlife Disease Association

URL: <https://doi.org/10.7589/0090-3558-25.4.455>

---

BioOne Complete ([complete.BioOne.org](https://complete.BioOne.org)) is a full-text database of 200 subscribed and open-access titles in the biological, ecological, and environmental sciences published by nonprofit societies, associations, museums, institutions, and presses.

Your use of this PDF, the BioOne Complete website, and all posted and associated content indicates your acceptance of BioOne's Terms of Use, available at [www.bioone.org/terms-of-use](https://www.bioone.org/terms-of-use).

Usage of BioOne Complete content is strictly limited to personal, educational, and non - commercial use. Commercial inquiries or rights and permissions requests should be directed to the individual publisher as copyright holder.

---

BioOne sees sustainable scholarly publishing as an inherently collaborative enterprise connecting authors, nonprofit publishers, academic institutions, research libraries, and research funders in the common goal of maximizing access to critical research.

## REVIEW ARTICLE . . .

# A REVIEW OF MARBLE SPLEEN DISEASE OF RING-NECKED PHEASANTS

Scott D. Fitzgerald and Willie M. Reed

Department of Veterinary Pathobiology, School of Veterinary Medicine,  
Animal Disease Diagnostic Laboratory, Purdue University,  
West Lafayette, Indiana 47907, USA

**ABSTRACT:** Marble spleen disease (MSD) is a contagious disease of captive-reared ring-necked pheasants (*Phasianus colchicus*) characterized by variable mortality and high morbidity. The etiologic agent is a type II avian adenovirus closely related to hemorrhagic enteritis virus of turkeys and splenomegaly virus of chickens. Gross lesions of MSD consist of enlargement and mottling of the spleen and pulmonary edema. Microscopic alterations are most pronounced in the spleen and are characterized by reticuloendothelial (RE) cell hyperplasia and lymphoid necrosis. Intranuclear viral inclusions occur within hyperplastic RE cells. Serologic detection of MSD is routinely accomplished using an agar gel precipitin test. Oral vaccination with hemorrhagic enteritis virus or avirulent strains of MSD virus is effective in preventing MSD. There is no specific treatment available for MSD but supportive care, strict sanitation and good management practices are helpful in reducing mortalities and limiting the spread of an epizootic.

**Key words:** Marble spleen disease, ring-necked pheasant, *Phasianus colchicus*, type II avian adenovirus, splenomegaly, review.

## INTRODUCTION

Marble spleen disease (MSD) is one of the most important viral diseases affecting ring-necked pheasants (*Phasianus colchicus*). Although the first report of MSD appeared <25 yr ago (Mandelli et al., 1966), the disease is now recognized worldwide in captive pheasants. MSD is closely related to two diseases of domestic poultry, hemorrhagic enteritis of turkeys and splenomegaly of chickens. The purpose of this paper is to provide a current review of the present literature on MSD.

## DISTRIBUTION

MSD has been a significant cause of mortality in pheasants since the first documented outbreak occurred in Italy during 1966 (Mandelli et al., 1966). Subsequent outbreaks of MSD have been reported throughout the United States including Connecticut, Pennsylvania, Virginia, Michigan and California (Mayeda et al., 1982). Documented outbreaks worldwide have been reported from Canada (Carlson et al., 1973), England (Bygrave and Pattison, 1973), Spain (Lu-

cientes et al., 1984), German Democratic Republic (Bergmann and Muller, 1982), Poland (Szankowska et al., 1982), Hungary (Sztajkov et al., 1978), Bulgaria (Stoikov and Nikiforov, 1983), Czechoslovakia (Rachac and Marjankova, 1983) and Australia (Tham and Theis, 1988).

The only reported serologic survey of wild birds for antibody against MSD and HE viruses (Domermuth et al., 1977a) failed to detect any individuals positive for the MSD virus. This survey was conducted on birds collected in Virginia, Florida and Texas. Six hundred eighteen birds, representing 42 species, were tested for antibody using an agar gel precipitin assay. The higher population-density of confinement-reared birds may account for the prevalence of MSD in captive pheasants and explain why there are no reports of MSD lesions or antibodies in wild birds; this is an issue which requires further investigation.

## CLINICAL SIGNS AND PATHOLOGY

In naturally occurring MSD, young adult pheasants between 3 and 8 mo of age are usually affected (Tham and Theis, 1988).



FIGURE 1. Enlarged and mottled spleens from pheasants with marble spleen disease.

Respiratory distress, occasionally accompanied by nasal discharge, is often the only sign preceding death. Mortality rates in naturally occurring epizootics vary from 5 to 20% and the course of disease is 10 days to several weeks (Carlson et al., 1973; Domermuth et al., 1979; Mayeda et al., 1982). The detection of antibody in convalescent flocks indicates a higher morbidity (Jarkowski and Wyand, 1972).

The spleen and lung frequently have gross lesions in birds infected with MSD virus. The spleen becomes enlarged two to three its times normal size (Wyand et al., 1972). There are gray confluent areas of necrosis which give the spleen its typical marbled appearance (Fig. 1). The lung is severely edematous and congested resulting in anoxia and eventual death (Bygrave and Pattison, 1973). Occasionally petechial hemorrhages are present on the epicardium (Wyand et al., 1972). Another infrequently reported lesion is enlargement of the liver (Bygrave and Pattison, 1973).

Histologic lesions occur primarily in the spleen and lung (Wyand et al., 1972). The spleen is infiltrated with heterophils and

there is depletion and necrosis of lymphoid follicles. Hyaline deposits occur in the sinusoids, around the lymphoid follicles and perivascularly (Wyand et al., 1972). There is reticuloendothelial (RE) cell hyperplasia (Fig. 2), with individual RE cell degeneration and necrosis. RE cell degeneration is due to viral replication and formation of intranuclear inclusions. Inclusions are large eosinophilic bodies within greatly enlarged nuclei with margined chromatin (Fig. 3). In experimentally reproduced cases of MSD the splenic inclusions are present for a relatively short period, usually from 3 to 5 days postinoculation (Ilitis et al., 1975a, b). The presence of intranuclear inclusions in association with splenic mottling and enlargement is pathognomonic for MSD (Wyand et al., 1972).

Pulmonary pathology is characterized by exudation of red blood cells and fibrin in atria and tertiary bronchi (Bygrave and Pattison, 1973). There are multiple foci of coagulative necrosis of epithelial cells. Occasional intranuclear inclusions are present within RE cells (Carlson et al., 1973;

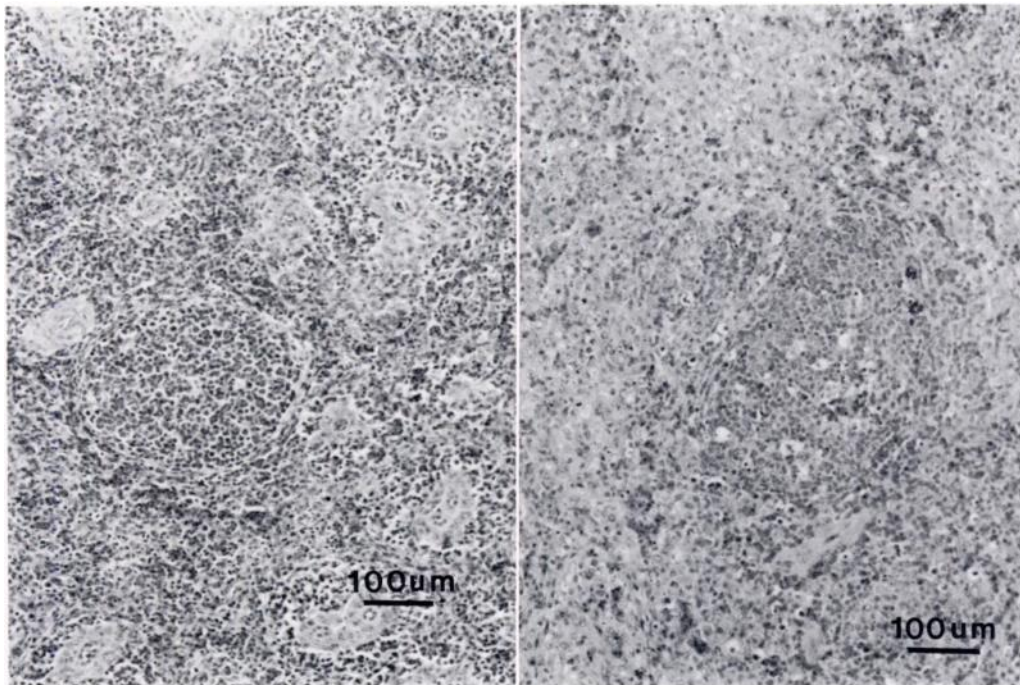


FIGURE 2. Normal and infected spleens of ring-necked pheasants. A. Normal spleen with normal lymphoid follicle and thin sheath of reticuloendothelial cells surrounding vessels. B. Lymphoid necrosis and hyperplastic coalescing reticuloendothelial cells seen in marble spleen disease. H&E.

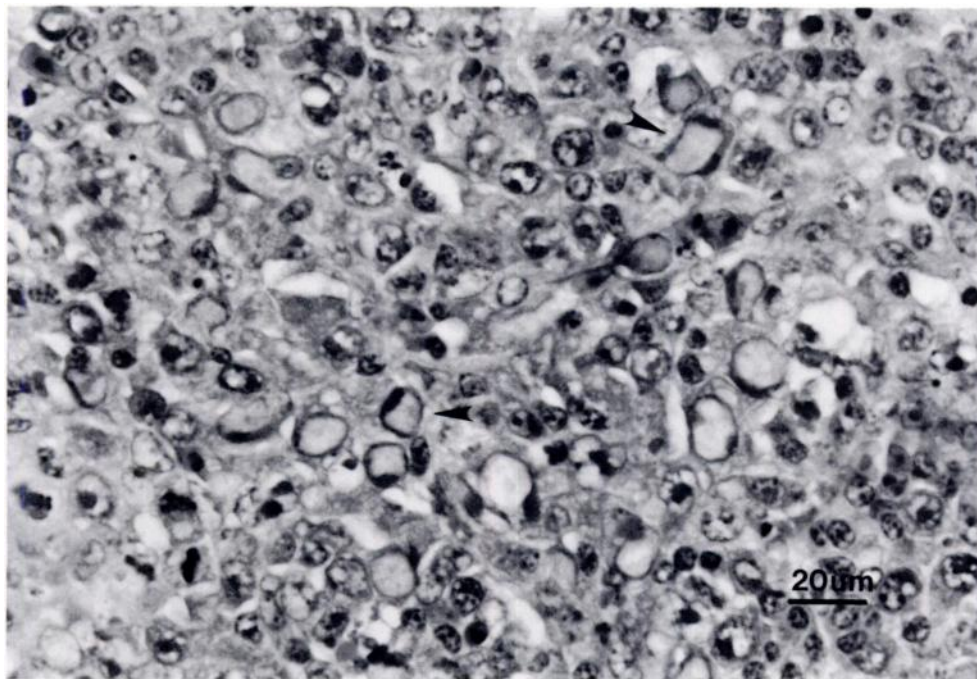


FIGURE 3. Splenic reticuloendothelial cells of ring-necked pheasant with enlarged nuclei (arrows) and margined chromatin due to intranuclear inclusions of marble spleen disease virus. H&E.



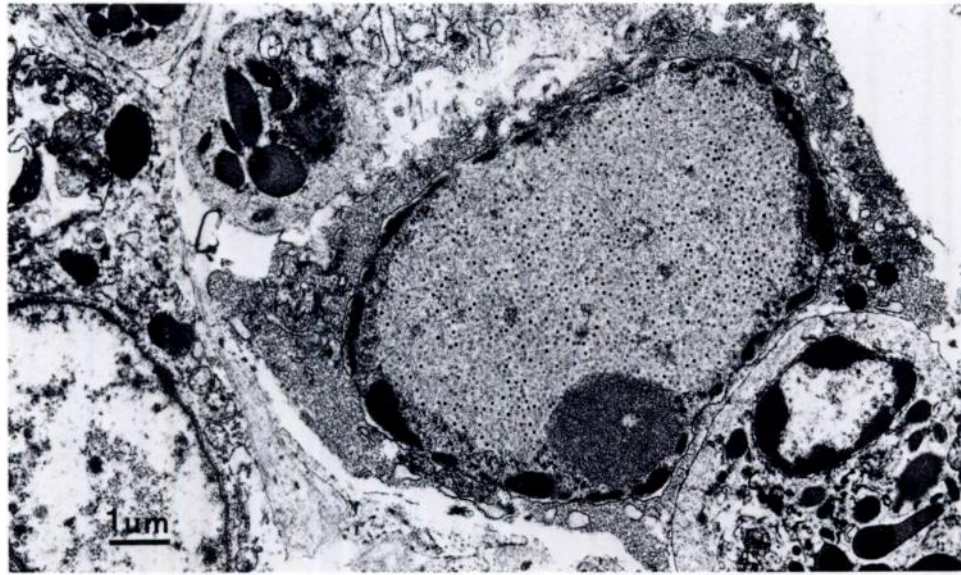


FIGURE 4. Electron micrograph: Splenic reticuloendothelial cell from a pheasant with marble spleen disease with enlarged nucleus, marginated chromatin and intranuclear nonenveloped viral particles.

Wyand et al., 1972), similar to those previously described in the spleen. Pulmonary changes are usually absent in experimentally-reproduced cases of MSD (Ilitis et al., 1975a; Fadly et al., 1988), questioning the role of MSD virus in the development of pulmonary lesions.

Other reported lesions in natural MSD epizootics occur in the liver and include sinusoidal congestion, centrilobular necrosis and formation of intranuclear inclusions within Kupffer cells (Carlson et al., 1973). Hepatic lesions, with the exception of intranuclear inclusions, have not been reproduced experimentally. Occasionally, in naturally occurring MSD cases, inclusions are found within RE cells of the proventriculus, bursa of Fabricius, and bone marrow (Carlson et al., 1973; Ilitis et al., 1975a).

#### ETIOLOGY

Ultrastructurally, splenic RE cell intranuclear inclusions contain numerous non-enveloped spherical viral particles ranging in size from 70 to 90 nm in diameter (Figs. 4, 5), which is consistent with avian adenovirus morphology (Ilitis et al., 1977).

The viral particles lie mainly within the nuclear membrane, with a few in close proximity outside the membrane (Ilitis and Wyand, 1974). The virus has been purified using chloroform extraction and centrifugation on a cesium chloride cushion and Koch's postulates have been fulfilled with the virus, thus establishing it as the causative agent for MSD (Ilitis et al., 1977).

Adenoviruses are responsible for many diseases of birds including quail bronchitis, inclusion body hepatitis of chickens and turkey viral hepatitis (Winterfield, 1984). The viruses which cause these diseases are classified as type I avian adenoviruses. Another group of avian adenoviruses, classified as type II, includes those which cause hemorrhagic enteritis of turkeys (HE), splenomegaly of chickens and MSD of pheasants (Domermuth and Gross, 1984).

Type I and type II avian adenoviruses are serologically distinct groups. Type I adenoviruses are further divided into 12 different serotypes (Winterfield, 1984). Conversely, type II adenoviruses are serologically indistinguishable from each other (Domermuth and Gross, 1984). There are major differences between type I and

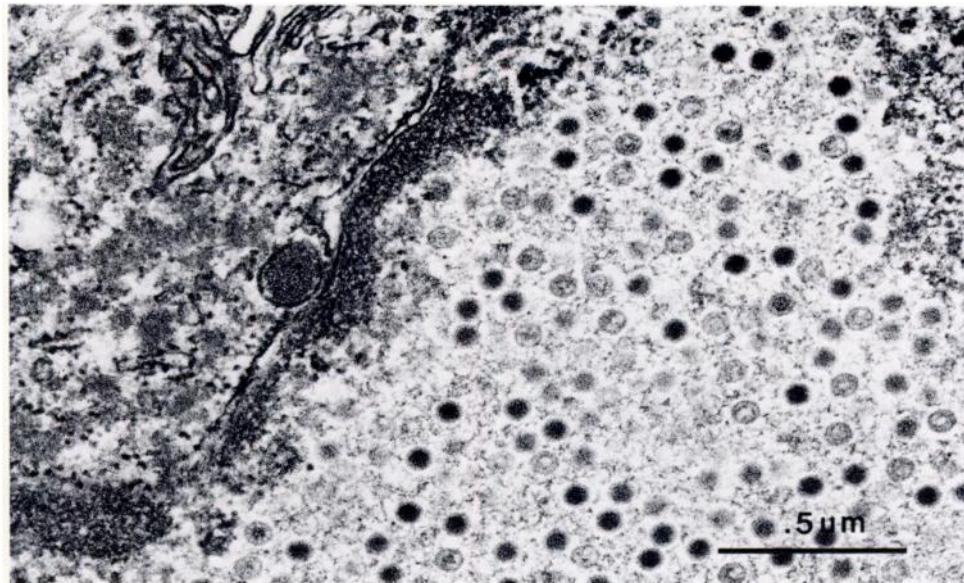


FIGURE 5. Electron micrograph: Close-up of nonenveloped, 70 to 90 nm marble spleen disease viral particles within an intranuclear inclusion of a reticuloendothelial cell from a pheasant.

type II adenoviruses, including differences in mode of transmission, age at which they infect the bird, and adaptability to in vitro culture techniques. Type I adenoviruses are transmitted both vertically and horizontally, they are most pathogenic to birds <1-mo-old and they are readily propagated in standard monolayer cell cultures (Winterfield, 1984). Type II adenoviruses are transmitted horizontally by direct contact, they are pathogenic to birds >1-mo-old and they are propagated in vitro only by using specific cell lines (Domermuth and Gross, 1984).

The type II avian adenoviruses are difficult to propagate in vitro. For many years researchers failed in their attempts to replicate the MSD virus in cell-culture systems such as chicken embryo fibroblasts, chicken or pheasant kidney cells or turkey embryos. Lines of lymphoblastic cells derived from turkey liver and transformed by Marek's disease virus are the only known in vitro cell lines in which type II adenoviruses will replicate (Nazerian and Fadly, 1982). The cell line most susceptible to viral infection, designated MDTC-RP19, is unusual in that it grows only in suspen-

sion, rather than in more typical monolayer. Another unusual finding is that type II adenoviruses replicate only within lymphoblastic cells which have B-cell (bursal origin) markers, while similarly transformed lymphoblastic cells which have T-cell (thymus origin) markers will not permit virus replication. Due to the specialized cell culture requirements of type II avian adenoviruses, naturally occurring cases are not generally confirmed by virus isolation.

Because of the similarity in ultrastructural characteristics, antigenicity, and splenic lesions produced by HE, MSD and splenomegaly virus of chickens, separation into distinct viruses has been based primarily on species infectivity. Only recently have the type II avian adenoviruses from chickens, pheasants and turkeys been shown to be genetically distinct (Zhang and Nagaraja, 1988). The DNA from field isolates of HE virus, MSD virus, and splenomegaly virus of chickens was digested with five restriction endonucleases. Marked differences were demonstrated to exist in the DNA cleavage patterns for these three viruses.

### SEROLOGIC DETECTION

Detection of antibodies against MSD virus was first accomplished by means of an agar gel precipitin (AGP) assay (Jarkowski and Wyand, 1972), which is still the standard method used at present. AGP can detect MSD virus antigen in splenic tissue or MSD antibody in serum. More recently, an enzyme-linked immunosorbency assay (ELISA) was developed to detect antibody against MSD virus and other type II avian adenoviruses (Ianconescu et al., 1984). ELISA is a significantly more sensitive assay than AGP, as much as 300 times more sensitive in detecting passively acquired antibody (Van der Hurk, 1986). ELISA can also quantitate the level of antibody; unfortunately this assay is not presently available in commercial kits nor through diagnostic laboratories. Neither assay is able to distinguish between the antibodies produced against various type II avian adenoviruses.

### PREVENTION

Because of the antigenic similarity between MSD and HE viruses, both have been very effectively utilized in the development of vaccines for both MSD and HE. Inoculation of MSD virus into turkey poults results in splenic enlargement but no mortality. The resultant antibodies formed against MSD virus are protective against subsequent infection by HE virus (Domermuth et al., 1977b). The reverse is also true; when HE virus is inoculated into young pheasants they develop splenomegaly but no mortality and are protected against future infection with MSD virus (Domermuth et al., 1979). Additionally, avirulent strains of MSD virus have been developed by propagation in turkeys. Both types of live-virus splenic-homogenate vaccines, those containing HE virus or avirulent MSD virus, have been administered through the drinking water to confinement-reared pheasants during the last decade with favorable results. The vaccine is administered after 4 wk of age to avoid maternal antibody, but before 6 wk of age

if possible. Recently, a cell culture propagated avirulent HE virus has been reported to provide excellent protection against infection by MSD virus (Fadly et al., 1988).

### PRACTICAL CONSIDERATIONS

There is no treatment for MSD at present. General supportive care, strict sanitation and prophylactic treatment with antibiotics to prevent secondary infections, isolation of infected birds to prevent further spread of the virus and reducing bird density are helpful in minimizing mortality during an outbreak. Concurrent parasitism by *Syngamus trachea* (gapeworm) and *Heterakis* sp. (cecal worm), as well as "feather picking" have all been suggested as factors which may prolong the course or aid in the spread of MSD during an outbreak (Mayeda et al., 1982). Routine parasite control and the use of "spectacles" or other anti-pecking devices may help to minimize losses. Once an epizootic has occurred in a facility, there may be an annual reoccurrence (Carlson et al., 1973; Domermuth et al., 1979; Mayeda et al., 1982); therefore regular vaccination after recovery from a confirmed MSD occurrence is advisable.

Sudden mortality in captive pheasants, coupled with splenic marbling and enlargement, should immediately suggest to gamebird personnel the possibility of MSD. Local diagnostic laboratories can quickly confirm the disease by histopathology or AGP assay. In spite of the lack of known outbreaks among wild pheasants, field biologists and wildlife personnel should be familiar with the clinical and pathologic manifestations of MSD.

### ACKNOWLEDGMENTS

Submitted as journal paper number 11,816 of the Purdue University Agricultural Experiment Station. We thank JoAnn Swackhamer for technical assistance with the electron microscopy.

### LITERATURE CITED

BERGMANN, V., AND H. MULLER. 1982. Detection of marble spleen disease in pheasants in the Ger-

- man Democratic Republic. Monatshefte für Veterinärmedizin 37: 154.
- BYGRAVE, A. C., AND M. PATTISON. 1973. Marble spleen disease in pheasants (*Phasianus colchicus*). Veterinary Record 92: 534-535.
- CARLSON, H. C., J. C. PETTIT, R. V. HEMSLEY, AND W. R. MITCHELL. 1973. Marble spleen disease of pheasants in Ontario. Canadian Journal of Comparative Medicine 37: 281-286.
- DOMERMUTH, C. H., D. J. FORRESTER, D. O. TRAINER, AND W. J. BIGLER. 1977a. Serologic examination of wild birds for hemorrhagic enteritis of turkey and marble spleen disease of pheasants. Journal of Wildlife Diseases 13: 405-408.
- , AND W. B. GROSS. 1984. Hemorrhagic enteritis and related infections. In Diseases of poultry, 8th ed., M. S. Hofstad, H. J. Barnes, B. W. Calneck, W. M. Reid, and W. H. Yoder, Jr. (eds.). Iowa State University Press, Ames, Iowa, pp. 511-516.
- , ———, C. S. DOUGLASS, R. T. DUBOSE, J. R. HARRIS, AND R. B. DAVIS. 1977b. Vaccination for hemorrhagic enteritis of turkeys. Avian Diseases 21: 557-565.
- , ———, L. D. SCHWARTZ, E. T. MALLINSON, AND R. BRITT. 1979. Vaccination of ring-necked pheasant for marble spleen disease. Avian Diseases 23: 30-38.
- FADLY, A. M., B. S. COWEN, AND K. NAZERIAN. 1988. Some observations on the response of ring-necked pheasants to inoculation with various strains of cell-culture-propagated type II avian adenovirus. Avian Diseases 32: 548-552.
- IANCONESCU, M., E. J. SMITH, A. M. FADLY, AND K. NAZERIAN. 1984. An enzyme linked immunosorbent assay for detection of hemorrhagic enteritis virus and associated antibodies. Avian Diseases 28: 667-692.
- ILITIS, J. P., S. B. DANIELS, AND D. S. WYAND. 1977. Demonstration of an avian adenovirus as the causative agent of marble spleen disease. American Journal of Veterinary Research 38: 95-101.
- , R. M. JARKOWSKI, AND D. S. WYAND. 1975a. Transmission of marble spleen disease in turkeys and pheasants. American Journal of Veterinary Research 36: 97-101.
- , ———, AND ———. 1975b. Experimentally transmitted marble spleen disease in the pen raised wild turkey. Journal of Wildlife Diseases 11: 484-485.
- , AND D. S. WYAND. 1974. Indications of a viral etiology for marble spleen disease in pheasants. Journal of Wildlife Diseases 10: 272-278.
- JARKOWSKI, R. M., AND D. S. WYAND. 1972. Marble spleen disease in pheasants: Demonstration of agar gel precipitin antibody in pheasants from an infected flock. Journal of Wildlife Diseases 8: 261-263.
- LUCIENTES, J., J. F. GARCIA-MARIN, AND J. J. BADIO-LA. 1984. Outbreak of marble spleen disease in Spain. Medicina Veterinaria 1: 59-61.
- MANDELLI, G., A. RINALDI, AND G. CERVIO. 1966. A disease involving the spleen and lungs in pheasants: Epidemiology, symptoms and lesions. La Clinica Veterinaria 89: 129-138.
- MAYEDA, B., G. B. WEST, A. A. BICKFORD, AND B. R. CHO. 1982. Marble spleen disease in pen-raised pheasants in California. Proceedings of the American Association of Veterinary Laboratory Diagnosticians 25: 261-270.
- NAZERIAN, K., AND A. M. FADLY. 1982. Propagation of virulent and avirulent turkey hemorrhagic enteritis virus in cell culture. Avian Diseases 26: 816-827.
- RACHAC, V., AND K. MARJANKOVA. 1983. Occurrence of marble spleen disease in pheasants in southern Bohemia. Veterinarstvi 33: 359-361.
- STOIKOV, V., AND I. NIKIFOROV. 1983. Clinical features, epidemiology and pathology of marble spleen disease in pheasants. Veterinarnomeditsinski Nauki 20: 89-97.
- SZANKOWSKA, Z., E. KUBISSA, M. PIOTROWSKA, AND H. PANUFNIK. 1982. Outbreak of marble spleen disease in pheasants in Poland. Medycyna Weterynaryjna 38: 288-290.
- SZTOJKOV, V., F. RATZ, AND E. SAGHY. 1978. Marble spleen disease of pheasants in Hungary. Magyar Alltorvosok Lapja 33: 223-226.
- THAM, V. L., AND N. F. THEIS. 1988. Marble spleen disease of pheasants. Australian Veterinary Journal 65: 130-131.
- VAN DER HURK, J. V. 1986. Quantitation of hemorrhagic enteritis virus antigen and antibody using enzyme-linked immunosorbent assays. Avian Diseases 30: 662-671.
- WINTERFIELD, R. W. 1984. Adenovirus infections of chickens. In Diseases of poultry, 8th ed., M. S. Hofstad, H. J. Barnes, B. W. Calneck, W. M. Reid, and W. H. Yoder, Jr. (eds.). Iowa State University Press, Ames Iowa, pp. 497-506.
- WYAND, D. S., R. M. JARKOWSKI, AND C. N. BURKE. 1972. Marble spleen disease in ring-necked pheasants: Histology and ultrastructure. Avian Diseases 16: 319-329.
- ZHANG, C., AND K. V. NAGARAJA. 1988. Restriction endonuclease finger-printing for avian adenovirus type II isolates. Journal of the American Veterinary Medical Association 192: 1790.

Received for publication 30 January 1989.