

Herpes-like Viral Dermatitis in a Beluga Whale (*Delphinapterus leucas*)

Authors: Barr, Bradd, Dunn, J. Lawrence, Daniel, M. D., and Banford, Amy

Source: Journal of Wildlife Diseases, 25(4) : 608-611

Published By: Wildlife Disease Association

URL: <https://doi.org/10.7589/0090-3558-25.4.608>

BioOne Complete (complete.BioOne.org) is a full-text database of 200 subscribed and open-access titles in the biological, ecological, and environmental sciences published by nonprofit societies, associations, museums, institutions, and presses.

Your use of this PDF, the BioOne Complete website, and all posted and associated content indicates your acceptance of BioOne's Terms of Use, available at www.bioone.org/terms-of-use.

Usage of BioOne Complete content is strictly limited to personal, educational, and non - commercial use. Commercial inquiries or rights and permissions requests should be directed to the individual publisher as copyright holder.

BioOne sees sustainable scholarly publishing as an inherently collaborative enterprise connecting authors, nonprofit publishers, academic institutions, research libraries, and research funders in the common goal of maximizing access to critical research.

Herpes-like Viral Dermatitis in a Beluga Whale (*Delphinapterus leucas*)

Bradd Barr,¹ J. Lawrence Dunn,² M. D. Daniel,³ and Amy Banford,⁴ ¹The California Veterinary Diagnostic Laboratory System, P.O. Box 1770, Davis, California 95617, USA; ²Mystic Marinelife Aquarium, Division of Sea Research Foundation, Inc., Mystic, Connecticut 06355, USA; ³New England Regional Primate Research Center, Harvard Medical School, One Pine Hill Drive, Southborough, Massachusetts 01772, USA; ⁴Pfizer Central Research, Eastern Point Rd., Groton, Connecticut 06340, USA

ABSTRACT: Approximately 3.5 mo following its capture, a beluga whale (*Delphinapterus leucas*) developed focal pale gray skin lesions. These lesions persisted for at least 8 mo. A biopsy from one of these sites revealed epithelial intranuclear inclusions. Herpes-like viral particles were seen by transmission electron microscopy. The eventual regression of skin lesions and lack of other clinical signs suggests the virus was only mildly pathogenic in this animal.

Key words: Beluga whale, *Delphinapterus leucas*, Cetacea, herpesvirus, dermatitis, case report.

Herpesvirus infections are reported in a variety of animal species, as well as man (Andrews et al., 1978; Roizman et al., 1981; Cheville, 1984; Osterhaus et al., 1985; Borst et al., 1986; Kennedy-Stoskopf et al., 1986; Martineau et al., 1988). Among marine mammals, herpes viral infections are reported in harbor seals (*Phoca vitulina*) and California sea lions (*Zalophus californianus*); also, there is one report of a herpes-like viral dermatitis in a beluga whale (*Delphinapterus leucas*) (Osterhaus et al., 1985; Borst et al., 1986; Kennedy-Stoskopf et al., 1986; Martineau et al., 1988). Depending on the particular herpesvirus and the host species involved, herpes infections may be latent, produce localized diseases or fatal systemic infections (Cheville, 1984). This report documents the presence of a herpes-like virus associated with focal necrotizing dermatitis in a beluga whale.

A young adult female beluga whale was captured at the mouth of the Churchill River (58°46'N, 94°12'W) in Manitoba, Canada, and transported to the Mystic Marinelife Aquarium (Division of Sea Research Foundation, Inc., Mystic, Connecticut 06355, USA). The whale was placed in the whale/dolphin exhibit, composed of

three indoor interconnected pools and a holding facility for California sea lions with a total volume of 1.55×10^6 liters of salted water, as described elsewhere (Dunn et al., 1982). It was fed approximately 30 lb of thawed frozen fish consisting of capelin (*Mallotus villosus*) and herring (*Clupea harengus*) daily, supplemented with multiple vitamins and thiamine HCl. There were a total of three beluga whales and four Atlantic bottle-nosed dolphins (*Tursiops truncatus*) in the exhibit. Approximately 3.5 mo after arrival, the attending staff noted a skin lesion over the dorsal ridge of the beluga whale. The involved area appeared slightly raised and the skin was a pale grey when compared to surrounding normal skin. The whale acclimated well to its new environment and seemed in good health, although the skin lesion increased in size. Eight mo following arrival, the lesion was cultured. Swabs were inoculated onto blood agar, mannitol salts agar, eosin methylene blue agar, thiosulfate citrate bile sucrose agar, Sabouraud's dextrose agar with 15 mg/liter of chloramphenicol, trypticase soy broth and Sabouraud's dextrose broth with 15 mg/liter of chloramphenicol. No significant pathogenic organisms were identified following 48 to 72 hr incubation at 37 C. The skin lesion was approximately 10 cm in diameter at this time. A second, smaller skin lesion approximately 6 × 8 cm in size was also noted at this time on the side of the whale. One mo later the whale was again examined and skin biopsies were taken from both the dorsal ridge and lateral skin lesions. At this time, the dorsal lesion covered a large area roughly 20 to 30 cm in diameter and consisted of a depressed, pale




FIGURE 1. Photograph of the skin lesion seen on the lateral aspect of the body at the time of the initial biopsy. The biopsy was taken in a region approximated by the arrowhead. Note the central depressed, eroded, pale region rimmed by a large zone of slightly raised or swollen epithelium. This entire focus was estimated to be 20 cm in length. Bar = 2 cm.

epithelialized region with an irregular border. The lesion on the side of the whale (Fig. 1) covered an elliptical area of skin estimated to be about 6×15 cm. This lesion had a slightly raised and pale epithelial border with a central pale, roughened and depressed, or somewhat pitted region. The skin seemed to be softer in the affected area. Both skin lesions were biopsied and specimens placed in Trump's fixative (Pentilla et al., 1975). Blood samples were collected from vessels of the tail fluke for a routine complete blood count (CBC), and to harvest serum. Biopsies were taken from the edge of the dorsal lesion and the edge of the central pitted area on the lateral lesion (Fig. 1) and processed using routine procedures for paraffin embedding and sectioning. Five micrometer thick hematoxylin and eosin stained sections were examined.

Histologically, significant changes were seen only in the biopsy taken from the lateral site. The biopsy consisted of epithelium with some papillary dermis which had a moderate mononuclear cell infiltrate. Along one edge of the biopsy the epithelium was characterized by intracellular edema with microvesicle formation in superficial epithelium. There were random areas of epithelial necrosis marked by

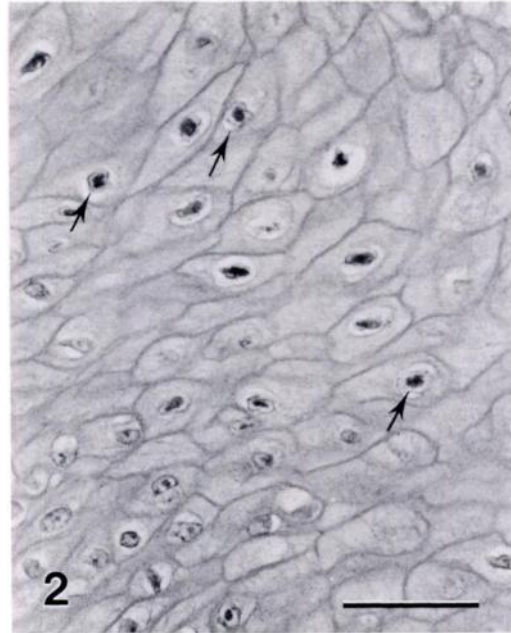


FIGURE 2. Photomicrograph of epithelium from the skin biopsy showing several epithelial cells with central nuclear inclusions rimmed by clear halos. There is also intracellular edema (arrows). Bar = 50 μ m.

nuclear pyknosis and karyorrhexis. Large numbers of epithelial cells had prominent intranuclear eosinophilic inclusions rimmed by clear nuclear halos (Fig. 2).

Based on the histopathology, suggesting a probable viral dermatitis, small pieces of remaining tissue in Trump's fixative were postfixed in 1% osmium tetroxide, stained with 2% uranyl acetate, embedded in Spurr's medium (Electron Microscopy Sciences, Fort Washington, Pennsylvania 19034, USA) and 90 nm sections were cut for transmission electron microscopic examination. By transmission electron microscopy (Zeiss E.M. 109 Transmission Electron Microscope, Carl Zeiss Inc., Thornwood, New York 10594, USA) numerous epithelial cells were found which contained intranuclear viral particles consisting of capsids and nucleocapsids (Figs. 3, 4). Enveloped virions could be seen just outside the nuclear membrane (Figs. 3, 4). These enveloped virions measured ap-

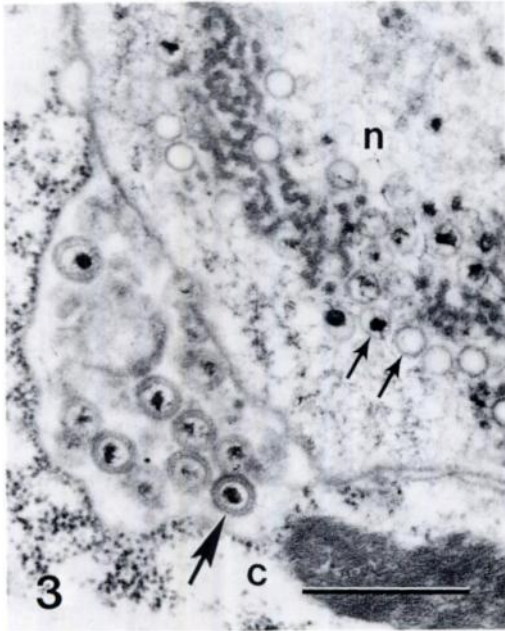

FIGURE 3. Transmission electron micrograph of an epithelial cell to demonstrate the nonenveloped viruses in the nucleus (n) (small arrows) as opposed to enveloped virus in the cytoplasm (c) (large arrows). Bar = 0.5 μ m.

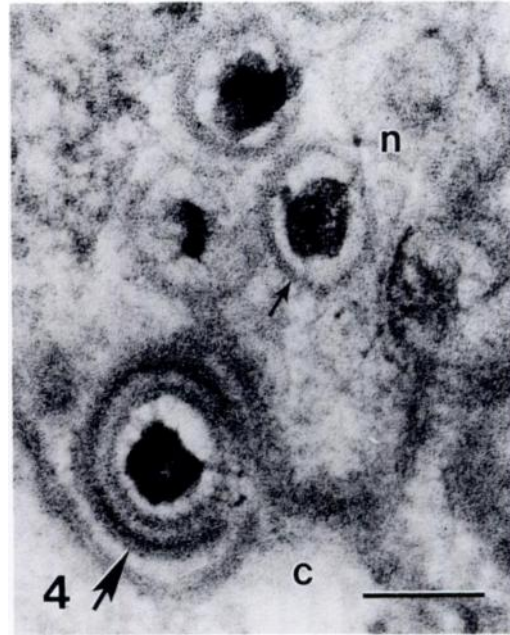


FIGURE 4. Transmission electron micrograph of another region at the edge of a cell nucleus (n) to demonstrate detail of single virions. A nonenveloped virus (small arrow) lies in the nucleus. Adjacent to it is an enveloped virus (large arrow) that has just passed through the inner nuclear membrane. Cytoplasm (c). Bar = 0.1 μ m.

proximately 140 to 160 nm in diameter. Their size and morphology were considered to be typical for herpesviruses (Andrews et al., 1978; Roixman et al., 1981; Cheville, 1984).

A second biopsy was obtained 9 wk following the first in an attempt to isolate the virus by cultivating it on Vero cells (African Green Monkey kidney cell line obtained from the American Tissue Culture Association, Rockville, Maryland 20852, USA). Attempts were also made to establish explant cell cultures from adjoining unaffected whale epithelium. Explant cultures were set up on 60 mm petri dishes using minimal essential medium with 20% heat inactivated fetal calf serum. Medium was changed every 5 days and cultures were observed for 6 wk. The results of both these procedures were negative. Serum from blood drawn at each biopsy was also tested for antibody titers to herpes simplex virus by indirect immunofluorescence and

were negative. Viral inclusions were not seen on this second biopsy.

To date, visible skin lesions are still present at these original sites over the dorsal ridge and lateral body wall, although they have not progressed and appear to be healed foci. However, occasional transient pale skin foci are seen elsewhere on the whale. The whale itself has remained active and in good health.

The eruption of multiple skin lesions, at least one of which was viral in origin, on this beluga whale suggests either the recrudescence of a latent herpes infection acquired prior to capture or transmission of the virus from some other animal source following capture. Herpesviruses generally are fairly species specific (Von Lichtenberg, 1984). Since a similar viral dermatitis has been reported from a free-living beluga whale (Martineau et al., 1988), we believe that the virus in this case was either

latent or that it was transmitted from other beluga whales following capture. Similar lesions have been seen on several beluga whales captured and released in the Churchill River in 1984 (J. L. Dunn, pers. obs.). Aside from other beluga whales, the animal also had contact with Atlantic bottle-nosed dolphins, California sea lions and Harbor seals (*Phoca vitulina*), of which herpesviruses have been found in the latter two species (Osterhaus et al., 1985; Borst et al., 1986; Kennedy-Stoskopf et al., 1986).

This particular herpesvirus infection, much like *Herpes simplex* infections in man (Von Lichtenberg, 1984), apparently has been confined to transient skin eruptions. There have been no serious disease problems with this particular beluga whale or with other marine mammals in contact with the whale, which could be attributed to a herpes infection. The previous reported case (Martineau et al., 1988) from a beluga whale had a very similar focal dermatitis. That particular whale was found dead, but death appeared to be due to perforation of a gastric ulcer associated with parasites (Martineau et al., 1988). Whether or not the herpesvirus reported in this case manifests itself solely in the form of a dermatitis in beluga whales remains to be seen.

Special thanks are extended to Pfizer Central Research for use of their technical facilities. Dea Greatbanks and Pat Bubucis provided technical assistance.

LITERATURE CITED

- ANDREWS, S. C., H. G. PEREIRA, AND P. WILDY. 1978. Viruses of vertebrates, 4th ed. Bailliere Tindall, London, England, 421 pp.
- BORST, G. H. A., H. C. WALVOORT, P. J. H. REIJNDERS, J. S. VAN DER KAMP, AND A. D. M. E. OSTERHAUS. 1986. An outbreak of herpesvirus infection in harbor seals (*Phoca vitulina*). *Journal of Wildlife Diseases* 22: 1-6.
- CHEVILLE, N. F. 1984. Cytopathology in viral diseases. Monographs in virology, Vol. 10. S. Karger, Basel, Switzerland, 236 pp.
- DUNN, J. L., J. D. BUCK, AND S. SPOTTE. 1982. Candidiasis in captive cetaceans. *Journal of the American Veterinary Medical Association* 181: 1316-1321.
- KENNEDY-STOSKOPF, S., M. K. STOSKOPF, M. A. ECKHAUS, AND S. D. STRANDBERG. 1986. Isolation of retrovirus and a herpesvirus from a captive California sea lion. *Journal of Wildlife Diseases* 22: 156-164.
- MARTINEAU, D., A. LA GACÉ, P. BELARD, R. HIGGINS, D. ARMSTRONG, AND L. R. SHUGART. 1988. Pathology of stranded beluga whales (*Delphinapterus leucas*) from the St. Lawrence Estuary, Quebec, Canada. *Journal of Comparative Pathology* 98: 287-311.
- OSTERHAUS, A. D. M. E., H. YANG, H. E. M. SPIJKERS, J. GROEN, J. A. TEPPEMA, AND G. VAN STEENIS. 1985. The isolation and partial characterization of a highly pathogenic herpesvirus from the harbor seal (*Phoca vitulina*). *Archives of Virology* 86: 239-251.
- PENTILLA, A., E. M. McDOWELL, AND B. F. TRUMP. 1975. Effects of fixation and postfixation treatments on volume of injured cells. *Journal of Histochemistry and Cytochemistry* 23: 251-270.
- ROIZMAN, L. E., F. CARMICHAEL, F. DEINHARDT, G. DE-THE, A. J. NAKMIUS, W. PLOWRIGHT, F. REPP, P. SHELDRIK, M. TAKAHASHI, AND K. WOLF. 1981. Herpesviridae definition, provisional nomenclature, and taxonomy. *Intervirology* 16: 201-217.
- VON LICHTENBERG, F. 1984. Infectious diseases. In *Pathologic basis of disease*, 3rd ed., S. I. Robbins, R. S. Cotran, and V. Kumar (eds.). W. B. Saunders, Philadelphia, Pennsylvania, pp. 284-285.

Received for publication 28 February 1989.