

## **Notoedric Acariasis in the Porcupine (*Erethizon dorsatum*)**

Authors: Snyder, Daniel E., Hamir, Amir N., Hanlon, Cathleen A., and Rupprecht, Charles E.

Source: Journal of Wildlife Diseases, 27(4) : 723-726

Published By: Wildlife Disease Association

URL: <https://doi.org/10.7589/0090-3558-27.4.723>

---

BioOne Complete ([complete.BioOne.org](https://complete.BioOne.org)) is a full-text database of 200 subscribed and open-access titles in the biological, ecological, and environmental sciences published by nonprofit societies, associations, museums, institutions, and presses.

Your use of this PDF, the BioOne Complete website, and all posted and associated content indicates your acceptance of BioOne's Terms of Use, available at [www.bioone.org/terms-of-use](https://www.bioone.org/terms-of-use).

Usage of BioOne Complete content is strictly limited to personal, educational, and non - commercial use. Commercial inquiries or rights and permissions requests should be directed to the individual publisher as copyright holder.

---

BioOne sees sustainable scholarly publishing as an inherently collaborative enterprise connecting authors, nonprofit publishers, academic institutions, research libraries, and research funders in the common goal of maximizing access to critical research.

## Notoedric Acariasis in the Porcupine (*Erethizon dorsatum*)

Daniel E. Snyder,<sup>1</sup> Amir N. Hamir,<sup>2</sup> Cathleen A. Hanlon,<sup>3</sup> and Charles E. Rupprecht,<sup>3</sup> <sup>1</sup> U.S. Department of Agriculture, Agricultural Research Service, Animal Parasite Research Laboratory, POB 952, Auburn, Alabama 36831, USA; <sup>2</sup> University of Pennsylvania, School of Veterinary Medicine, New Bolton Center, 382 West Street Road, Kennett Square, Pennsylvania 19348, USA; <sup>3</sup> The Wistar Institute of Anatomy and Biology, 3601 Spruce St., Philadelphia, Pennsylvania 19104, USA

**ABSTRACT:** Six of 16 porcupines (*Erethizon dorsatum*) live-trapped in Sullivan County, Pennsylvania were infested with the mite *Notoedres douglasi*. Alopecia was evident in the ventral inguinal area and the infested skin was thickened, wrinkled and had multifocal areas of extensive hyperkeratosis. Microscopically the skin lesions consisted of extensive acanthosis and hyperkeratosis with variable cellular infiltrate in the dermis. Mites were seen in tunnels in the hyperkeratotic skin sections. This is the first report of notoedric acariasis in the porcupine.

**Key words:** *Notoedres douglasi*, porcupine, *Erethizon dorsatum*, acariasis, skin lesions, case report.

Mites of the genus *Notoedres* have been recorded from many species of mammals; there are presently 38 valid species in this genus (Klompen, 1991). Mites of this genus are similar morphologically to *Sarcoptes* spp., except that in the former the anal opening is located dorsally while in the latter it is at the posterior terminal margin. *Notoedres douglasi* is known to cause acariasis in several species of squirrels, including *Sciurus griseus*, *S. carolinensis*, *S. niger*, *Tamias striatus*, *Glaucomys volans* and *Ratufa bicolor* (Klompen, 1991). There are no reports of notoedric acariasis in the porcupine. This report describes gross and microscopic skin lesions in the porcupine caused by *Notoedres douglasi*.

Sixteen porcupines were live-trapped from October 1989 to October 1990 in Sullivan County, State Gamelands-13, Pennsylvania (76°30'N, 41°20'W) as part of baseline data collection and site selection for potential field trials with a recombinant rabies vaccine intended for use in raccoons (Rupprecht et al., 1986). Examination of six of these 16 (38%) animals revealed moderate to severe alopecia and broken hairs in the ventral inguinal area

(Fig. 1). The alopecic skin was thickened, wrinkled and covered by crusty white material (Fig. 2). Each animal was euthanized by an intravenous barbiturate overdose and a complete necropsy was performed. Representative tissue samples, including skin from the affected areas, were taken, fixed in 10% neutral buffered formalin, embedded in paraffin, sectioned at 5  $\mu$ m, stained with hematoxylin and eosin and examined by light microscopy. Microscopic skin lesions consisted of extensive acanthosis and hyperkeratosis with a variable cellular infiltrate in the dermis consisting primarily of lymphocytes and plasma cells. Within the keratotic epidermis there were many clear spaces (tunnels) and in some of these sections mites were seen (Figs. 3, 4). Skin scrapings revealed numerous adult (Fig. 5) and immature mites. These mites were identified as *Notoedres douglasi* based on the description of Lavoipierre (1964); however, Klompen (1991) has placed the species name *N. douglasi* in synonymy with *N. centrifera*. These mites are small (length 0.25  $\times$  breadth 0.24 mm) and can be easily missed. Klompen (1991) lists the following diagnostic characteristics to distinguish *N. douglasi* (= *N. centrifera*) from related species: female with internal scapular and anteriormost dorsal setae (*sci* and *d1*) more than 20  $\mu$ m long; male without dorsal shields, pretarsus IV extremely reduced and setae *kT* of tibio-tarsi III–IV are strong spines. A portion of formalin fixed skin and mites in situ are deposited in the U.S. National Parasite Collection (Beltsville, Maryland 20705, USA; Accession number 81899). Additionally, slide mounted specimens of this mite have been deposited in the University of Michigan Museum of

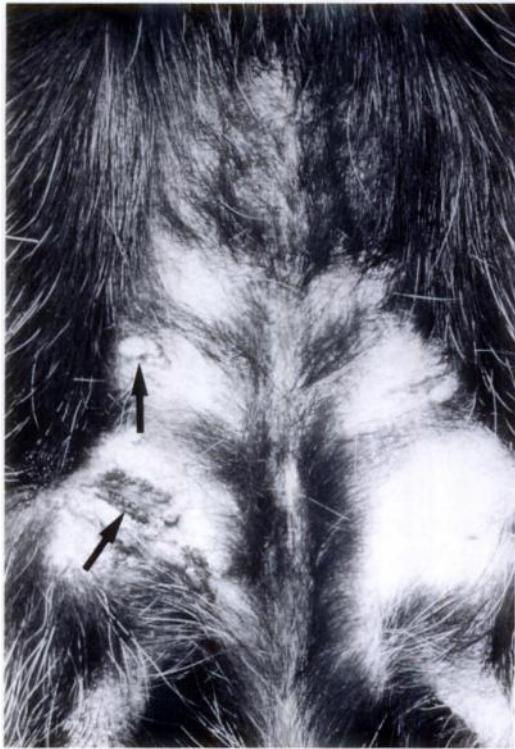

FIGURE 1. Ventral abdominal-inguinal region of porcupine illustrating extensive alopecia and multifocal areas (arrows) with extensive hyperkeratosis.

Natural History (Ann Arbor, Michigan 48109, USA; Accession number UMMZ 91-0314-1).

*Notoedres douglasi* is the etiologic agent of notoderic acariasis in several species of squirrels (see species list above; Bryant, 1921, 1926; Lavoipierre, 1964; Fain, 1965; Carlson et al., 1982; Kazacos et al., 1983; Evans, 1984; Klompen, 1991). In sciurid rodents, scaly lesions and alopecia first appear on the head and neck and then spread to the body. The microscopic lesions found on the porcupines described above are similar to those found on squirrels; however, the distribution of alopecia is different.

There is no previously published information on the occurrence of *Notoedres* spp. infestation on porcupines in the United States. The large number of porcupines infested with this mite as described above would indicate that this parasite is endem-

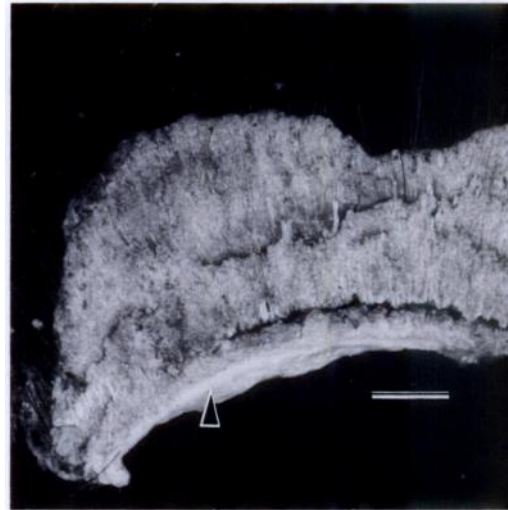


FIGURE 2. Excised portion of affected skin (arrowhead) illustrating thickness of encrusted material. Bar = 1.0 cm.

ic and that ongoing transmission is occurring via direct contact with other porcupines in this geographic area. The potential for cross-transmission between squirrels and the porcupine is not known. Factors that may predispose an animal to acariasis, such as stress, poor nutritional status, or other disease, were not found in these particular animals. Payne and O'Meara (1958) described *Sarcoptes scabiei* infestations on

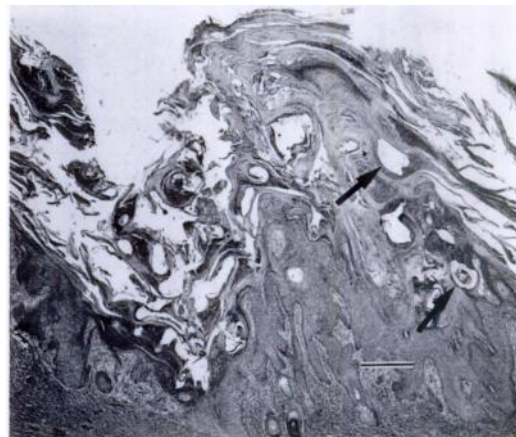


FIGURE 3. Low magnification of skin illustrating hyperkeratosis and tunnels with and without mites (arrows). H&E. Bar = 200  $\mu$ m.

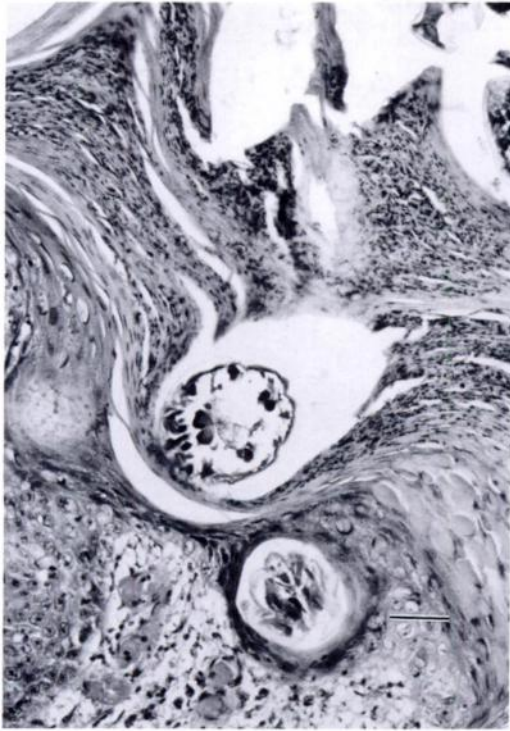


FIGURE 4. Higher magnification with *Notoedres douglasi* mite within tunnel in keratotic layer of skin. H&E. Bar = 50  $\mu$ m.

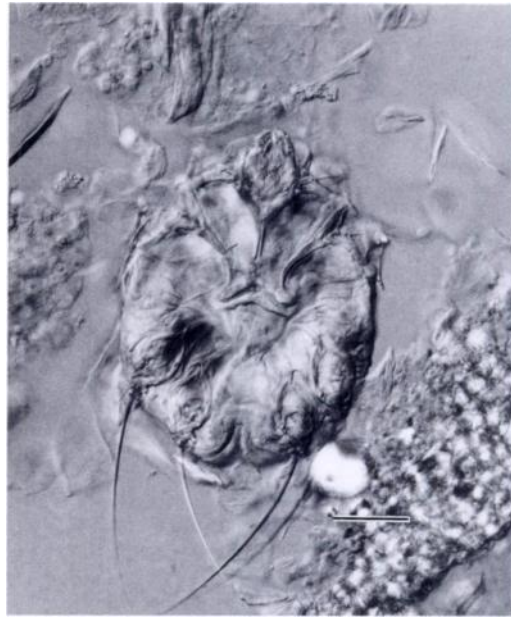

FIGURE 5. Adult *Notoedres douglasi* mite from skin scraping. Bar = 50  $\mu$ m.

porcupines and O'Meara et al. (1960) described a *S. scabei* infestation on a fisher (*Martes pennanti*), both from Maine (USA). The descriptions of the gross lesions, including a ventral inguinal location, in both of these cases are identical to the lesions described herein for porcupines from Pennsylvania. Ivermectin has been used to successfully treat hosts infested with *Notoedres* spp. and may be useful in the treatment of porcupines infested with *N. douglasi* (Evans, 1984; Klompen and Nachman, 1990).

This work was supported in part by the Pennsylvania Department of Agriculture.

#### LITERATURE CITED

- BRYANT, H. C. 1921. Tree squirrels infested with scabies. *California Fish and Game* 7: 128.
- . 1926. Gray squirrel disease still exists. *California Fish and Game* 11: 205–206.
- CARLSON, B. L., D. P. ROHER, AND S. W. NIELSEN. 1982. Notoedric mange in gray squirrels (*Sci-*
- urus carolinensis*). *Journal of Wildlife Diseases* 18: 347–348.
- EVANS, R. H. 1984. Ivermectin treatment of notoedric mange in two fox squirrels. *Journal of the American Veterinary Medical Association* 185: 1437–1438.
- FAIN, A. 1965. Notes sur le genre *Notoedres* Raillet, 1893 (Sarcoptidae: Sarcoptiformes). *Acarologia* 7: 321–342.
- KAZACOS, E. A., K. R. KAZACOS, AND H. A. DEMAREE. 1983. Notoedric mange in two fox squirrels. *Journal of the American Veterinary Medical Association* 183: 1281–1282.
- KLOMPEN, J. S. H. 1991. Phylogenetic relationships in the family Sarcoptidae (Acari: Astigmata). Miscellaneous Publications, Museum of Zoology, University of Michigan, Ann Arbor, Michigan. In press.
- , AND M. W. NACHMAN. 1990. Occurrence and treatment of the mange mite *Notoedres muris* in marsh rats from South America. *Journal of Wildlife Diseases* 26: 135–136.
- LAVOPIERRE, M. M. J. 1964. Mange mites of the genus *Notoedres* (Acari: Sarcoptidae) with descriptions of two new species and remarks on notoedric mange in the squirrel and the vole. *Journal of Medical Entomology* 1: 5–17.
- O'MEARA, D. C., D. D. PAYNE, AND J. F. WITTER. 1960. *Sarcoptes* infestation of a fisher. *The Journal of Wildlife Management* 24: 339.
- PAYNE, D. D., AND D. C. O'MEARA. 1958. *Sarcoptes scabei* infestation of a porcupine. *The Journal of Wildlife Management* 22: 321–322.

- RUPPRECHT, C. E., T. J. WIKTOR, D. H. JOHNSON, A. N. HAMIR, B. DIETZSCHOLD, W. H. WUNNER, L. T. GLICKMAN, AND H. KOPROWSKI. 1986. Oral immunization and protection of raccoons (*Procyon lotor*) with a vaccinia rabies glycoprotein recombinant virus vaccine. *Proceedings of the National Academy of Sciences USA* 83: 7947–7950.
- Received for publication 7 February 1990.*