



Chondrosarcoma in a Wild Great White Heron from Southern Florida

Authors: Spalding, Marilyn G., and Woodard, J. Carroll

Source: Journal of Wildlife Diseases, 28(1) : 151-153

Published By: Wildlife Disease Association

URL: <https://doi.org/10.7589/0090-3558-28.1.151>

BioOne Complete (complete.BioOne.org) is a full-text database of 200 subscribed and open-access titles in the biological, ecological, and environmental sciences published by nonprofit societies, associations, museums, institutions, and presses.

Your use of this PDF, the BioOne Complete website, and all posted and associated content indicates your acceptance of BioOne's Terms of Use, available at www.bioone.org/terms-of-use.

Usage of BioOne Complete content is strictly limited to personal, educational, and non - commercial use. Commercial inquiries or rights and permissions requests should be directed to the individual publisher as copyright holder.

BioOne sees sustainable scholarly publishing as an inherently collaborative enterprise connecting authors, nonprofit publishers, academic institutions, research libraries, and research funders in the common goal of maximizing access to critical research.

Chondrosarcoma in a Wild Great White Heron from Southern Florida

Marilyn G. Spalding¹ and J. Carroll Woodard,² ¹ Department of Infectious Diseases; ² Department of Comparative and Experimental Pathology, College of Veterinary Medicine, University of Florida, Gainesville, Florida 32611, USA

ABSTRACT: A typical chondrosarcoma is reported from the nictitating membrane of a great white heron (*Ardea herodias occidentalis*). This is the first report of a neoplasm in a free flying ciconiiform, and was the only one found in a survey of 957 carcasses from Florida.

Key words: Neoplasm, chondrosarcoma, great white heron, *Ardea herodias occidentalis*, Ciconiiformes, case report.

Neoplasms have been reported infrequently in birds of the order Ciconiiformes. Published reports have been from captive birds including a seminoma from the sacred ibis (*Threskiornis aethiopicus*); a hepatocellular carcinoma, hepatocellular tumor and cholangiocarcinoma from three lesser flamingos (*Phoenicopterus minor*); an adenocarcinoma and cholangiocarcinoma from two greater flamingos (*Phoenicopterus ruber*); and a metastatic osteosarcoma from a Panama boat-billed heron (*Cochlearius cochlearius panamensis*) (Effron et al., 1977; Wadsworth et al., 1985; Lopez and Merino-Moncada, 1986; Liu et al., 1982). Siegfried (1983) found neoplasms to be extremely rare in free-flying birds. No record could be found for neoplasms in free-flying ciconiiformes.

In a 4-yr survey to determine the cause of death of adult ($n = 174$), post-fledging juvenile ($n = 68$) and nestling ($n = 715$) ciconiiformes in Florida, only this case of neoplasia was encountered among 125 great white herons (*Ardea herodias*), 110 great blue herons (*A. herodias*), 138 great egrets (*Casmerodius albus*), 141 snowy egrets (*Egretta thula*), 113 tricolored herons (*E. tricolor*), 61 little blue herons (*E. caerulea*), seven reddish egrets (*E. rufescens*), one American bittern (*Botaurus lentiginosus*), four black-crowned night herons (*Nycticorax nycticorax*), six yellow-crowned night herons (*Nycticorax violaceus*), 13 cattle egrets (*Bubulcus ibis*),

11 green-backed herons (*Butorides striatus*), 83 white ibis (*Eudocimus albus*), 137 roseate spoonbills (*Ajaia ajaja*), and seven wood storks (*Mycteria americana*) (M. G. Spalding and D. J. Forrester, unpublished data).

An adult great white heron on Ramrod Key, Monroe County, Florida (USA; 24°38'N, 81°24'W) was noted to be weak and to have a tumorous mass associated with the right eye. The bird was easily captured on 18 January 1990 and died the next day. It was taken to the Florida Keys Wild Bird Center (Islamorada, Florida 33036, USA). The frozen carcass was submitted for necropsy.

A complete necropsy was performed. The carcass was that of a severely emaciated mature male great white heron. A $3.3 \times 3.5 \times 3.0$ cm round, firm, pedunculated mass (Fig. 1) was firmly attached to the ventromedial region of the conjunctival space by a firm white band of tissue that was presumed to be the hypertrophied tendon of pyramidalis. Conjunctival tissue surrounded this tendon and the base of the mass. Thus, the mass appeared to arise from the nictitating membrane, possibly from the pyramidalis tendon. The mass occupied the conjunctival space; the larger part of it protruded from the palpebrae. The surface was rough and yellow/tan, except where it was covered by a brown crust. No connection could be found between the mass and the scleral ossicles. There was no gross bony lesion or contact between the tumor and the orbit.

Tissue from the mass, both eyes, lung, and pectoral muscle were fixed in 10% buffered formalin. Histologic sections were stained with hematoxylin and eosin.

Both globes appeared grossly and histologically normal. It was easy to physically separate the partly encapsulated mass

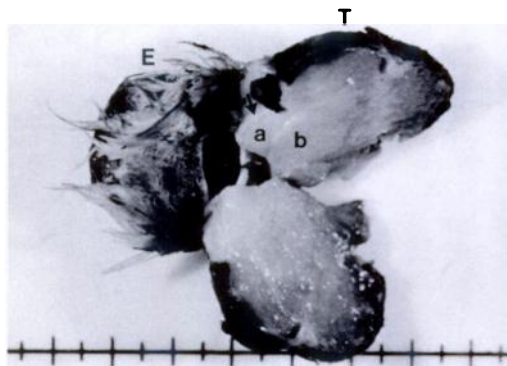


FIGURE 1. Bisected tumor (T) attached by the nictitating membrane to the removed right eye (E) of a great white heron showing the tendinous portion (arrowhead), spindle cell portion (a), and cartilaginous portion (b). Bar = 0.5 cm/division.

into three portions (illustrated by a, b, and the arrow in Fig. 1). The dense white tissue band appeared histologically as very dense collagenous connective tissue. Separate and adjacent to this was a wedge of elastic firm tan tissue. Histologically this appeared as dense spindle cells in a regular pattern with interlacing bundles (Fig. 2c). Cellular morphology was somewhat obscured by freezer artifact; however, pleomorphism was evident. Occasionally pale basophilic matrix was present between more loosely packed spindle cells, and in some areas islands of cartilage were formed. The third and largest portion (80%) of the tumor consisted of variably sized islands of cartilage separated by loose fibrovascular connective tissue (Fig. 2b). Chondrocytes were quite pleomorphic, often had hyperchromatic multiple nuclei, and were frequently nested in pale basophilic matrix. Rarely, the matrix was mineralized. The cartilaginous and spindle cell portions of the tumor intergraded in one small area near the conjunctival attachment (Fig. 2a). The surface of the mass was ulcerated and covered by a crust of necrotic cells that contained bacterial colonies and fungal hyphae. There was evidence of local invasion but not of metastasis. Representative tissue from this

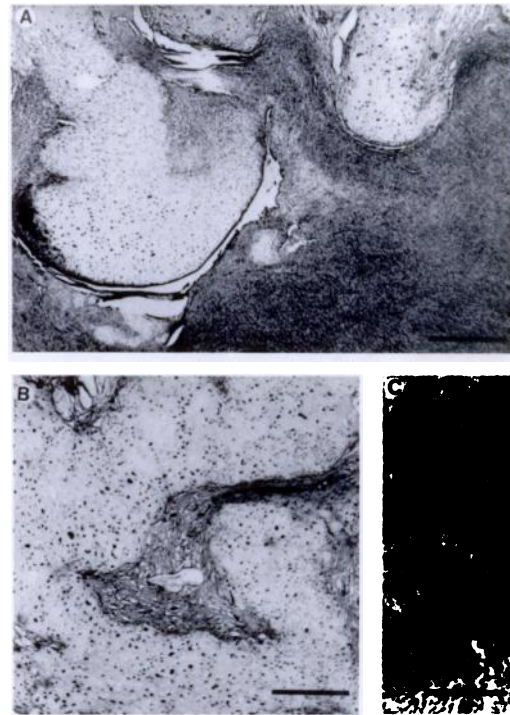


FIGURE 2. Photomicrographs of tumor showing (a) region of interaction of tissue types (bar = 500 µm), (b) cartilaginous portion (bar = 500 µm), and (c) spindle cell portion (bar = 100 µm).

tumor has been deposited in the Registry of Comparative Pathology (Armed Forces Institute of Pathology, Washington, D.C., 20306, USA; Accession number 2311227-9-0).

Pool (1990) described the wall of the orbit as a site for multilobular tumor of bone in the canine skull. In his experience, however, spindle cell mesenchyme never formed a major part of the tumor. Chondroma rodens (=multilobular chondroma/osteoma) has been described from the orbit of a dog (Pletcher et al., 1979) and was likened to juvenile aponeurotic fibroma found in humans; however, this tumor rarely occurred on the head in humans.

A chondrosarcoma with similar islands of cartilage was described on the metatarsal-phalangeal joint of a free-flying ruffed grouse (*Bonasa umbellus*) by Siegfried (1983); however, that mass was very large

and had eroded or invaded adjacent bone. A spindle cell portion was not described by Siegfried (1983).

The cartilaginous portion of the tumor from this case was almost identical histologically to multiple tumors that were found on the legs of a sandhill crane (*Grus canadensis*) in Florida (J. C. Woodard, unpublished data). Similar masses were seen on the legs of approximately 1 per 1,000 cranes in Florida (S. Nesbitt, pers. comm.) suggesting an infectious or genetically transmitted cause. Siegfried (1983) suggested that the fibrosarcomas she observed and a multicentric neurofibrosarcoma reported by Locke (1963) in a wild Canada goose (*Branta canadensis*) might be genetically transmitted or of viral origin. The location of the cartilage tumors in the great white heron, sandhill cranes, and ruffed grouse suggest that arthropod borne virus, such as avian pox virus (Akey et al., 1981), could be a cause. Pox virus was not found in chondrosarcomatous tissue from the sandhill crane examined by electron microscopy (J. C. Woodard, unpublished data).

This study was funded by the Nongame Wildlife Program of the Florida Game and Fresh Water Fish Commission (Contract #88007) and is publication number R-01327 of the Florida Agricultural Experiment Stations. Laura Quinn of the Florida Keys Wild Bird Rehabilitation Center provided the specimen. We thank Steve Nesbitt for his contribution and comments.

LITERATURE CITED

- AKEY, B. K., J. K. NAYER, AND D. J. FORRESTER. 1981. Avian pox in Florida wild turkeys: *Culex nigripalpus* and *Wyeomyia vanduzeei* as experimental vectors. *Journal of Wildlife Diseases* 17: 597-599.
- EFFRON, M., L. GRINER, AND K. BENIRSCHKE. 1977. Nature and rate of neoplasia found in captive wild mammals, birds, and reptiles at necropsy. *Journal of the National Cancer Institute* 59: 185-198.
- LIU, S., E. P. DOLENSEK, AND J. P. TAPPE. 1982. Osteosarcoma with multiple metastases in a Panama boat-billed heron. *Journal of the American Veterinary Medical Association* 181: 1396-1398.
- LOCKE, L. N. 1963. Multicentric neurofibrosarcoma in a Canada goose, *Branta canadensis*. *Avian Diseases* 7: 196-202.
- LOPEZ, A., AND M. MERINO-MONCADA. 1986. Cholangiocarcinoma and hepatic megalocytosis in a captive flamingo, *Phoenicopterus ruber*. *Journal of Zoo Animal Medicine* 17: 147-148.
- PLETCHER, J. M., S. A. KOCH, AND M. A. STEDHAM. 1979. Orbital chondroma rodens in a dog. *Journal of the American Veterinary Medical Association* 175: 187-190.
- POOL, R. R. 1990. Tumors of bone and cartilage. In *Tumors in domestic animals*, 3rd ed., J. E. Moulton (ed.). University of California Press, Berkeley, California, pp. 157-230.
- SIEGFRIED, L. M. 1983. Neoplasms identified in free-flying birds. *Avian Diseases* 27: 86-99.
- WADSWORTH, P. F., D. M. JONES, AND S. L. PUGSLEY. 1985. A survey of mammalian and avian neoplasms at the Zoological Society of London. *Journal of Zoo Animal Medicine* 16: 73-80.

Received for publication 25 January 1991.