



Systemic Infection with a Yeast-like Organism in Captive Banded Rock Rattlesnakes (*Crotalus lepidus klauberi*)

Authors: Reddacliff, G. L., Cunningham, M., and Hartley, W. J.

Source: Journal of Wildlife Diseases, 29(1) : 145-149

Published By: Wildlife Disease Association

URL: <https://doi.org/10.7589/0090-3558-29.1.145>

BioOne Complete (complete.BioOne.org) is a full-text database of 200 subscribed and open-access titles in the biological, ecological, and environmental sciences published by nonprofit societies, associations, museums, institutions, and presses.

Your use of this PDF, the BioOne Complete website, and all posted and associated content indicates your acceptance of BioOne's Terms of Use, available at www.bioone.org/terms-of-use.

Usage of BioOne Complete content is strictly limited to personal, educational, and non - commercial use. Commercial inquiries or rights and permissions requests should be directed to the individual publisher as copyright holder.

BioOne sees sustainable scholarly publishing as an inherently collaborative enterprise connecting authors, nonprofit publishers, academic institutions, research libraries, and research funders in the common goal of maximizing access to critical research.

Systemic Infection with a Yeast-like Organism in Captive Banded Rock Rattlesnakes (*Crotalus lepidus klauberi*)

G. L. Reddacliff,¹ M. Cunningham, and W. J. Hartley, Taronga Zoo, P.O. Box 20, Mosman, New South Wales 2088, Australia. ¹ Present address: Elizabeth Macarthur Agricultural Institute, PMB 8, Camden, New South Wales 2570, Australia.

ABSTRACT: Three captive banded rock rattlesnakes (*Crotalus lepidus klauberi*) died at Taronga Zoo, Sydney, Australia, between 1984 and 1987 with similar lesions in each case. Grossly, the liver and kidneys had multiple grey, fleshy nodules replacing much of the parenchyma. Histologically, these lesions were massive accumulations of yeast-like organisms, located mainly within macrophages in capillaries and sinusoids. There was little other inflammatory reaction. Organisms also were seen in the muscle and adventitial coats of the intestine, in the spleen, pancreas, brain, lungs, ovary, and fat body. Apparent budding was observed in fresh smears, and the organisms stained Gram-positive and periodic acid-Schiff positive but failed to grow on routine fungal media. Based on transmission electron microscopy, the organisms were typical yeast cells with thick, apparently single-layered cell walls showing evidence of enteroblastic proliferation. Two of the snakes had concurrent bacterial infections.

Key words: Polymicrobial infection, systemic mycosis, yeast-like organism, banded rock rattlesnake, *Crotalus lepidus klauberi*, mortality, case reports.

Many fungi, including several genera associated with the phycomycoses and the genera *Paecilomyces*, *Aspergillus*, *Beauveria*, *Cephalosporium*, *Metarhizium*, *Candida*, *Geotrichum*, and *Chrysosporium*, cause systemic infections of the respiratory and alimentary tracts in reptiles (Austwick and Keymer, 1981; Migaki et al., 1984). Lesions characteristically are granulomata surrounding growing fungal colonies. Systemic mycoses featuring intracellular infections such as histoplasmosis, blastomycosis and coccidioidomycosis have not been recorded, except for a single case of coccidioidomycosis in a gopher snake (Timm et al., 1988). We describe unusual pathology associated with yeast-like organisms in three female band-

ed rock rattlesnakes (*Crotalus lepidus klauberi*).

Two snakes were obtained from San Diego Zoo, San Diego, California (USA) in 1970 and third from Gladys Porter Zoo, Brownsville, Texas (USA) in 1980. They were kept together at Taronga Zoo, Sydney, New South Wales, Australia in a small indoor vivarium and were not individually identified. Each weighed about 500 grams. The animals were fed laboratory-reared mice and the enclosure was cleaned regularly of feces and urates. No other reptiles were kept in the same vivarium, but reptiles of many other species were kept in the same building.

Case 1 was presented in April 1984 with a diffuse firm swelling about 10 cm cranial to the cloaca and an inability to pass feces. Under halothane anesthesia, a tumor mass adjacent to, and involving the distal part of, the left kidney was removed surgically; the remaining part of the left kidney appeared grossly unaffected. The snake was given three doses of 1 mg gentamycin (Gentam®, Ilium, Smithfield, New South Wales) intramuscularly at 72 hr intervals, and supportive care. Two mo later the snake was fully healed, had resumed eating and was passing normal feces and urates.

Grossly the mass removed at surgery was pale yellow and grey, and without obvious internal structure. It was not highly vascularized. Histologically, most of the mass was composed of oval to pyriform organisms 5 to 10 μ m in length, located apparently within large macrophage-like cells. The organisms stained well with Giemsa, periodic acid-Schiff reaction and Gomori

methamine-silver, and were strongly Gram-positive. Apparent budding was observed in some cells. There was a sparse fibrous and vascular supporting stroma; intracellular clumps of similar organisms were observed within the lumina of some blood vessels. No necrosis was seen and the only inflammatory response was a light scattering of granulocytes throughout the tissue.

The snake remained apparently normal for 7 mo and then died without observed illness. At necropsy the snake was fat. The fat bodies were congested and had multiple chalky plaques, the liver had multiple pale irregular foci and the kidneys had apparent urate streaking. The lung contained frothy fluid and had multiple pale nodules in the wall. The surgical site was fully healed with no obvious lesion. Fat, liver and lung were cultured aerobically and anaerobically on sheep blood agar and MacConkey agar (Oxoid Australia, Hurstville, New South Wales, Australia), at 37 C and 23 C. This yielded a heavy mixed growth of *Salmonella arizonae* and *Pseudomonas aeruginosa*. There were large numbers of apparently budding, mainly intracellular, yeast-like organisms in unstained wet squashes of the tissues. Material was cultured for fungi on Mycophil and Mycosel agar (BBL, Becton Dickinson Microbiology Systems, Cockeysville, Maryland, USA) at 28 C. No growth was obtained after 4 wk.

Histologically, the liver had multiple focal areas of recent non-inflammatory necrosis associated with bacterial colonies and occasional caseated chronic bacterial abscesses. The whole liver also had a diffuse intrasinusoidal infiltration with yeast-like organisms. The lung had focal bacterial emboli, with associated necrosis, and diffuse infiltration of lung capillaries with yeast-like organisms (Fig. 1). The fat body was diffusely infiltrated with similar organisms and had focal areas of inflammatory necrosis. Smaller numbers of these organisms were seen in clumps in the lamina propria, submucosa and adventitial

coats of the intestine. Clumps of yeast-like organisms also were observed in the kidney, mainly in interstitial blood vessels and occasionally in the glomeruli. In all tissues, as in the surgically removed mass, the organisms were mainly intracellular, within macrophages or endothelial cells, and there was little other inflammatory response.

We concluded that this snake died from an overwhelming bacterial septicemia, possibly originating from longstanding hepatic abscesses, and associated with widespread organ invasion by a yeast-like organism.

The second snake (Case 2) died in June 1987 after refusing to eat for 5 weeks. It was found 3 wk before death with a pebble lodged in its mouth. At gross necropsy we observed only a swollen, mottled, pale liver and multiple, pale foci in the kidneys. Yeast-like organisms also were seen in unstained wet squashes from these tissues. No bacterial isolation was attempted, but fungal cultures from the kidney were made as for Case 1. A single colony of a yeast-like organism was obtained. This was submitted to the Australian National Mycology Reference Laboratory (Royal North Shore Hospital, St Leonards, New South Wales, Australia) where it was identified as *Trichosporon beigeli* (Emmons et al., 1970).

Histologically, there was a widespread and severe accumulation of yeast-like organisms in liver sinusoids, apparently within macrophages, and forming intrasinusoidal granulomata (Fig. 2). There also were foci of recent hepatocellular necrosis with some granulocytic infiltration. There was no evidence for bacterial involvement. Lung and kidney had masses of the same organism within the capillaries but no other pathology, while much of the splenic parenchyma was replaced by yeast-laden macrophages, and focal clumps of the same organism were present in the pancreas. A single focus of caseating inflammatory necrosis with marked surrounding gliosis was present in the ventral pontine region of the brain. There were masses of the yeast-

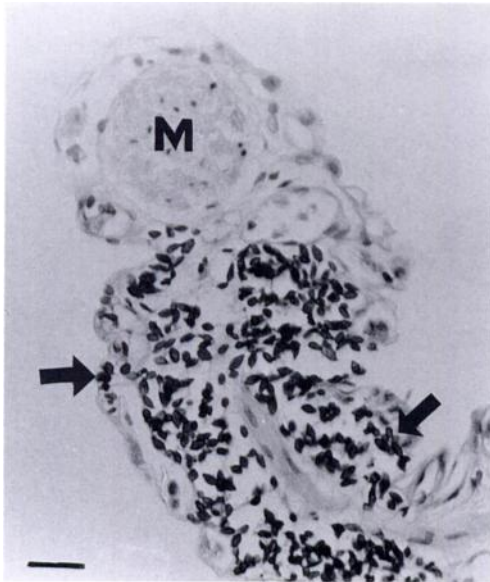


FIGURE 1: Lung from Case 1. Diffuse infiltration of capillaries with large numbers of yeast-like organisms (arrows). Normal pulmonary smooth muscle bundle (M). Periodic acid-Schiff reaction. Bar = 20 μ m.

like organisms within surrounding blood vessels. No lesions were observed in sections examined of muscle, skin or stomach.

We ascribed the death of this snake to the massive multisystem invasion by the yeast-like organism.

Case 3 was presented in July 1987 with a history of several weeks' inappetence and a firm immobile swelling 5 cm anterior to the cloaca. On direct microscopic examination of cloacal swabs we observed a mixed bacterial flora and large numbers of trichomonad-like protozoa. We also examined the aspirate obtained with a 21 gauge needle inserted percutaneously into the palpable mass, and observed yeast-like organisms as in Cases 1 and 2. The snake was treated for possible protozoal colitis with 20 mg dimetridazole (Emtryl Soluble,[®] May & Baker Aust., West Footscray, Victoria, Australia) given orally by stomach tube and repeated once after one week. No fungal growth was obtained on Mycophil and Mycosel agar.

The snake did not improve and was

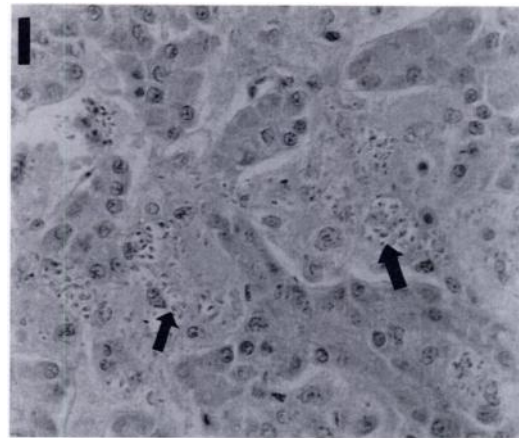


FIGURE 2: Liver from Case 2. Sinusoidal infiltration by macrophages (arrows) which contain yeast-like organisms. H&E stain. Bar = 20 μ m.

killed by intracardiac injection with 100 mg pentobarbitone (Lethabarb,[®] Arnolds of Reading, Boronia, Victoria, Australia) in August 1987. On gross necropsy the snake had moderate fat reserves. The liver was markedly enlarged and mottled, with grey, fleshy, and yellow caseous areas, while the kidneys were almost totally replaced with grey, fleshy lesions. Yeast-like organisms were evident in wet smears from the grey, fleshy lesions in these tissues. Lungs were congested and the colon wall was grossly thickened. Fresh liver and kidney were submitted to the Mycology Reference Laboratory. There the tissues were cultured on Sabouraud's dextrose agar and Sabouraud's agar with gentamycin, Brain heart infusion agar and Czapek agar (Oxoid Australia, Hurstville, New South Wales, Australia) and incubated at 28 C and 37 C. No fungi were isolated after a 4 week incubation. *Salmonella arizonae* was isolated from the liver and kidney. On histopathological examination, the kidney was replaced almost entirely with masses of intracellular yeast-like organisms. There was similar infiltration of the ovary, of the abdominal fat body, and of the muscle and adventitial coats of the intestine. Occasional foci of walled-off caseous necrosis containing bacterial colonies were present in the intestinal wall. The liver had a gen-

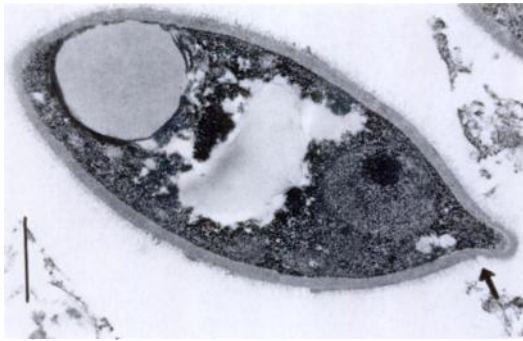


FIGURE 3: Transmission electron micrograph of kidney (surgical biopsy material) from Case 1, showing typical yeast-like morphology with evidence of enteroblastic proliferation (arrow). Bar = 1 μ m.

eralized sinusoidal infiltration by intracellular yeast-like organisms plus foci of bacteria-associated necrosis with granulocytic reaction. In the lungs there was a mild infiltration of yeast-like organisms, plus foci of bacterial embolic necrosis. There was a moderate infiltration of the epi- and pericardium with macrophages, some of which contained yeast-like organisms. No lesions were seen in the sections examined of venom gland, eye, brain, muscle or thyroid.

The clinical condition of this snake was ascribed to chronic, widespread multisystem infiltration by yeast-like organisms, along with subacute bacterial enterohepatic infection.

In transmission electron micrographs made from sections of formalin-fixed biopsy material from Case 1, we observed typical fungal cells with lipid droplets, cytoplasmic organelles and nuclei with an electron-dense nucleolus. The cell wall appeared to be single-layered and had evidence of enteroblastic proliferation, as commonly seen in yeast-like fungi (Fig. 3). The intracellular location of the organisms was confirmed and an apparent broad unstained capsule was present; however artifactual separation from the surrounding cellular material could not be ruled out.

The significance of the single isolate of *T. beigelii* from Case 2 is worthy of discussion in the light of recent reports of

systemic infection by this organism in immunocompromised human patients (Hoy et al., 1986). *Trichosporon beigelii* is widely distributed and commonly found in soil, water and animal excreta, and is the cause of white piedra, a common and innocuous hair infection of humans in tropical and subtropical regions (Hoy et al., 1986). It grows easily on routine fungal culture. Literally thousands of yeast-like organisms were observed in wet squashes of organs from all three snakes. Yet only a single colony of *T. beigelii* was obtained from many attempted cultures. Either the yeast-like organism observed was not *T. beigelii*, or it was a strain of *T. beigelii* not amenable to culture.

Because of the failure to grow and unequivocally identify the organism it is difficult to speculate on the source of the infection. It is possible that all three snakes originally were collected from the wild in the same geographic area, and possibly all could have been subclinically infected with an enzootic yeast-like organism. Age, as well as bacterial and protozoal infections, might then have weakened the animals sufficiently to allow recrudescence of chronic infection. However, the apparent rarity of this infection and its occurrence in all three snakes of this species at one zoo strongly suggests infection in the captive environment.

We thank D. Ellis for his comments on the electron micrographs. Representative sections and paraffin blocks are held in the Registry of Non-domestic Animal Pathology at Taronga Zoo; accession numbers: 0016, 0023, 0073, 0081.

LITERATURE CITED

- AUSTWICK, P. K. G., AND I. F. KEYMER. 1981. Fungi and actinomycetes. In *Diseases of the Reptilia*, J. E. Cooper and O. F. Jackson (eds.). Academic Press, London, England, pp. 193-231.
- EMMONS, C. W., C. H. BINFORD, AND J. P. UTZ. 1970. *Medical mycology*, 2nd ed. Lea & Febiger, Philadelphia, pp. 164-165.
- HOY, J., K. HSU, K. ROLSTON, R. L. HOPFER, M. LUNA, AND G. P. BODEY. 1986. *Trichosporon beigelii* infection: A review. *Reviews of Infectious Diseases* 8: 959-967.

- MIGAKI, G., E. R. JACOBSON, AND H. W. CASEY. 1984. Fungal diseases in reptiles. *In* Diseases of amphibians and reptiles, G. L. Hoff, F. L. Frye and E. R. Jacobson (eds.). Plenum Press, New York, New York, pp. 183–204.
- TIMM, K. I., R. J. SONN, AND B. D. HULTGREN. 1988. Coccidioidomycosis in a Sonoran gopher snake, *Pituophis melanoleucus affinis*. *Journal of Medical and Veterinary Mycology* 26: 101–104.

Received for publication 21 November 1991.