

Enteric Coccidia (Apicomplexa) in the Small Intestine of the Northern Spotted Owl (*Strix occidentalis caurina*)

Authors: Hoberg, E. P., Cawthorn, R. J., and Hedstrom, O. R.

Source: Journal of Wildlife Diseases, 29(3) : 495-497

Published By: Wildlife Disease Association

URL: <https://doi.org/10.7589/0090-3558-29.3.495>

BioOne Complete (complete.BioOne.org) is a full-text database of 200 subscribed and open-access titles in the biological, ecological, and environmental sciences published by nonprofit societies, associations, museums, institutions, and presses.

Your use of this PDF, the BioOne Complete website, and all posted and associated content indicates your acceptance of BioOne's Terms of Use, available at www.bioone.org/terms-of-use.

Usage of BioOne Complete content is strictly limited to personal, educational, and non - commercial use. Commercial inquiries or rights and permissions requests should be directed to the individual publisher as copyright holder.

BioOne sees sustainable scholarly publishing as an inherently collaborative enterprise connecting authors, nonprofit publishers, academic institutions, research libraries, and research funders in the common goal of maximizing access to critical research.

Enteric Coccidia (Apicomplexa) in the Small Intestine of the Northern Spotted Owl (*Strix occidentalis caurina*)

E. P. Hoberg,^{1,4} R. J. Cawthorn,² and O. R. Hedstrom,³ ¹ Biosystematic Parasitology Laboratory, Agricultural Research Service, U.S. Department of Agriculture, Beltsville Agricultural Research Center, Beltsville, Maryland 20705, USA; ² Department of Pathology and Microbiology, Atlantic Veterinary College, University of Prince Edward Island, Charlottetown, Prince Edward Island, Canada C1A 4P3; ³ College of Veterinary Medicine, Oregon State University, Corvallis, Oregon 97331, USA. ⁴ Corresponding author

ABSTRACT: Sporulated oocysts (mean dimensions = $13.0 \times 10.8 \mu\text{m}$) and sporocysts ($11.3 \times 5.5 \mu\text{m}$) of a coccidian resembling *Frenkelia* sp. or *Sarcocystis* sp. were present in the lamina propria of the small intestine of a naturally-infected northern spotted owl (*Strix occidentalis caurina*) collected near Medford, Oregon (USA). Dimensions of these oocysts and sporocysts appear to be considerably smaller than those from other sarcocystid species with avian definitive hosts. Additionally, numerous developmental stages and unsporulated oocysts (mean dimensions $22.8 \times 17.8 \mu\text{m}$) of a possible species of *Isospora* also were observed in the intestinal epithelium. This constitutes the first report of enteric coccidia from spotted owls. Neither parasite appeared to cause the death of the bird.

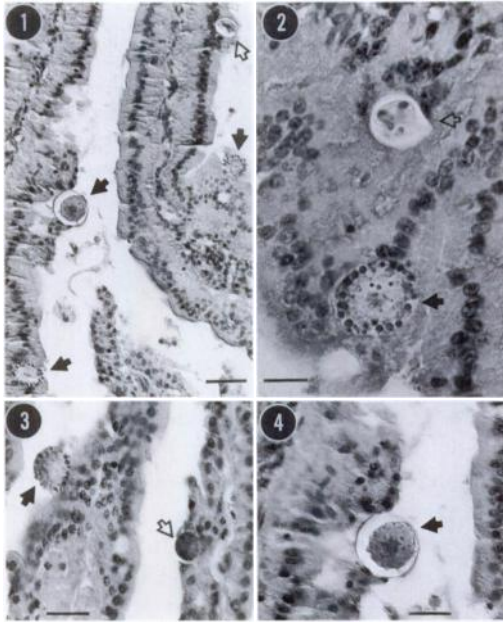
Key words: *Strix occidentalis caurina*, northern spotted owl, *Frenkelia* sp., *Sarcocystis* sp., intestinal coccidia.

The northern spotted owl (*Strix occidentalis caurina*) has been the focus of a continuing ecological confrontation in the old-growth forests of the Pacific Northwest (USA) (Simberloff, 1987). Although detailed knowledge of the biology of spotted owls has developed as a consequence of this debate (Forsman et al., 1984; Gutiérrez and Carey, 1985), until recently there has been a paucity of information concerning parasitism. Hoberg et al. (1989) and Gutiérrez (1989) conducted studies of parasitic helminths and hemoprotozoans, respectively, but there have been no previous reports of enteric coccidia from spotted owls as summarized by Cawthorn et al. (1984) and Levine (1986).

In the present study we report the discovery of at least two genera of enteric coccidia from a juvenile female spotted owl submitted to the Veterinary Diagnostic Laboratory (VDL, College of Veterinary Medicine, Oregon State University,

Corvallis, Oregon, USA) in November 1985. The owl, found dead near Medford, Oregon (approximately $42^{\circ}16'N$; $122^{\circ}50'W$), had been wearing a radio transmitter for the preceding 4 mo as part of a study of juvenile dispersal in western Oregon (Miller and Meslow, 1985). The owl was necropsied within 2 days of death, having been transported from the field on ice and stored at 4 C for a short period immediately prior to examination. Fresh tissues and feces were not examined. Tissue specimens from the liver, spleen, kidney, lung, heart, brain, small intestine, and gizzard were fixed in 10% neutral buffered formalin, embedded in paraffin, sectioned at $5 \mu\text{m}$, and stained with hematoxylin and eosin. A few sporulated oocysts containing sporocysts and sporozoites of a *Frenkelia*-like parasite (or *Sarcocystis*) were observed in the small intestine (Figs. 1, 2). Numerous developmental stages of another unidentified coccidian also were found in intestinal epithelium (Figs. 1 to 4). Because *Frenkelia* and *Sarcocystis* are known only from the subepithelium, these stages may represent a species of *Isospora*. Representative tissue sections were deposited in the U.S. National Parasite Collection (No. 82810), U.S. Department of Agriculture, Agricultural Research Service, Biosystematic Parasitology Laboratory, Beltsville, Maryland (USA).

The level of infection by the *Frenkelia*-like organism appeared to be minimal. Few sporulated oocysts (containing two sporocysts each with four sporozoites) were observed in the lamina propria. Thin-walled oocysts ($n = 10$) (Figs. 1, 2) measured 12.4 to $15.5 \mu\text{m}$ (mean \pm SD = 13 ± 0.997) \times



FIGURES 1 to 4. Enteric stages of a *Frenkelia* sp.-like organism and an unidentified coccidian shown in tissue sections from the intestinal epithelium of a northern spotted owl, *Strix occidentalis caurina*. All preparations are with hematoxylin and eosin. Figure 1. Sporulated oocyst of a *Frenkelia*-like coccidian (open arrow) and developing and unsporulated oocysts of an unidentified coccidian (black arrows). Bar = 25 μ m. Figure 2. Sporulated oocyst of a *Frenkelia*-like organism (open arrow) with two sporocysts visible within the oocyst wall; also, a developing oocyst of an unidentified coccidian (black arrow). Bar = 10 μ m. Figure 3. Microgametocyte (open arrow) and oocyst lacking differentiated wall (black arrow) attributable to an unidentified coccidian. Bar = 15 μ m. Figure 4. Unsporulated oocyst of an unidentified coccidian (black arrow). Bar = 15 μ m.

9.3 to 12.4 (10.8 ± 0.776); sporocysts ($n = 3$) were 11 to 12 μ m (11.3 ± 0.577) \times 5 to 6 μ m (5.5 ± 0.701) and had a shape index (length/width) of 1.83 to 2.4; sporozoites could not be accurately measured. A Steida body or sporocyst residuum was not observed. Few unsporulated oocysts were observed and microgametocytes and asexual stages attributable to this coccidian were not identified.

Another coccidian was even more numerous in the intestinal villi. Parasites were located above the nucleus of the epithelial cells and primarily at or near the tips of

the villi. Microgametocytes, macrogametocytes, along with developing oocysts (with poorly differentiated walls), and unsporulated oocysts were observed (Figs. 1 to 4). These latter stages were distinctly larger than those attributed to the *Frenkelia*-like organism. Microgametocytes ($n = 10$) measured 7.8 to 10.4 μ m (mean \pm SD = 9.8 ± 0.91) in diameter (Fig. 3); developing oocysts ($n = 10$) with distinctly granular margins were 15.5 to 18.6 μ m (17.2 ± 1.09) in diameter (Figs. 1, 3, 4); and unsporulated oocysts with well differentiated walls ($n = 10$) were 20.2 to 27.9 μ m (22.8 ± 2.64) \times 17.8 to 23.3 μ m (19.7 ± 1.75) (Figs. 1, 4). Oocysts and developmental stages were distributed largely near the tips of the villi and were not observed in the crypts.

Development and sporulation in situ are characteristic of species of *Frenkelia* and *Sarcocystis* in avian definitive hosts (Cawthorn et al., 1984; Lindsay et al., 1987; Lindsay and Blagburn, 1989). Life cycle studies and experimental transmission would be necessary for generic and species-level identification of the sarcocystid from spotted owls. However, based on comparisons of the oocysts and sporocysts these specimens apparently are not a nominal species among these genera. The two valid species of *Frenkelia* (*F. glareoli*, *F. microti*) typically occur in *Buteo* spp. in the Palearctic and Holarctic regions, respectively. Sporocysts of *F. microti* in North America are larger and differ in shape index (1.1 to 1.5) from those found in spotted owls (Upton and McKown, 1992). Although four of the five species of *Sarcocystis* from raptors occur in strigiforms (*S. rauschorum*, *S. dispersa*, *S. scotti*, and *S. sebeki*) the oocysts and sporocysts of these generally are larger and less elongate than those reported in the present study (Cawthorn et al., 1984).

Transmission of the *Frenkelia*-like organism from spotted owls is likely to involve rodent intermediate hosts. Microtine rodents (*Phenacomys longicaudus*, *Clethrionomys* spp.), sciurids (*Glaucomys sa-*

brinus), and cricetids (*Neotoma* spp.) are among the primary prey taken by these owls, although the diet includes 31 species of mammals (Forsman et al., 1984). Examination of these small mammals in the Pacific Northwest is required to determine their role in the life cycle.

Infection with either the *Frenkelia*-like organism or the unidentified coccidian did not appear to contribute to the death of the owl; although oocysts and developmental stages were relatively numerous within the mucosal enterocytes or along the mucosal surface, we observed no significant inflammatory response. However, intestinal infection by species of *Sarcocystis* may be associated with clinical disease and death in some raptors (Cawthorn et al., 1984). Consequently, these and other parasites should continue to be studied as a potential contributing factor influencing the population biology of threatened and endangered species (Gutiérrez, 1989).

We thank G. S. Miller at the Oregon Cooperative Wildlife Research Unit, Department of Fisheries and Wildlife, Oregon State University for originally making this owl available for examination. The necropsy was conducted by E. Wallner-Pendleton at VDL, College of Veterinary Medicine, Oregon State University. Histological preparations were provided by the staff of the VDL. Critical comments which improved the manuscript were kindly provided by R. Fayer and M. Jenkins, U.S. Department of Agriculture, Agricultural Research Service, Beltsville, Maryland.

LITERATURE CITED

- CAWTHORN, R. J., A. A. GAJADHAR, AND R. J. BROOKS. 1984. Description of *Sarcocystis rauschorum* sp. n. (Protozoa: Sarcocystidae) with experimental cyclic transmission between varying lemmings (*Dicrostonyx richardsoni*) and snowy owls (*Nyctea scandiaca*). *Canadian Journal of Zoology* 62: 217–225.
- FORSMAN, E. D., E. C. MESLOW, AND H. M. WIGHT. 1984. The distribution and biology of the spotted owl in Oregon. *Wildlife Monographs* 87: 1–64.
- GUTIÉRREZ, R. J. 1989. Hematozoa from the spotted owl. *Journal of Wildlife Diseases* 25: 614–618.
- , AND A. B. CAREY (editors). 1985. Ecology and management of the spotted owl in the Pacific Northwest. General Technical Report PNW-185. U.S. Department of Agriculture Forest Service, Pacific Northwest Forest and Range Experiment Station, Portland, Oregon, 119 pp.
- HOBERG, E. P., G. S. MILLER, E. WALLNER-PENDLETON, AND O. R. HEDSTROM. 1989. Helminth parasites of northern spotted owls (*Strix occidentalis caurina*) from Oregon. *Journal of Wildlife Diseases* 25: 246–251.
- LEVINE, N. D. 1986. The taxonomy of *Sarcocystis* (Protozoa, Apicomplexa) species. *The Journal of Parasitology* 72: 372–382.
- LINDSAY, D. S., AND B. L. BLAGBURN. 1989. *Caryospora uptoni* and *Frenkelia* sp.-like coccidial infections in red-tailed hawks (*Buteo borealis*). *Journal of Wildlife Diseases* 25: 407–409.
- , S. I. AMBRUS, AND B. L. BLAGBURN. 1987. *Frenkelia* sp.-like infection in the small intestine of a red-tailed hawk. *Journal of Wildlife Diseases* 23: 677–679.
- MILLER, G. S., AND E. C. MESLOW. 1985. Dispersal data for juvenile spotted owls: The problem of small sample size. In *Ecology and management of the spotted owl in the Pacific Northwest*, R. J. Gutiérrez and A. B. Carey (eds.). General Technical Report PNW-185. U.S. Department of Agriculture Forest Service, Pacific Northwest Forest and Range Experiment Station, Portland, Oregon, pp. 69–73.
- SIMBERLOFF, D. 1987. The spotted owl fracas: Mixing academic, applied and political ecology. *Ecology* 68: 766–772.
- UPTON, S. J., AND R. D. MCKOWN. 1992. The red-tailed hawk, *Buteo jamaicensis*, a native definitive host of *Frenkelia microti* (Apicomplexa) in North America. *Journal of Wildlife Diseases* 28: 85–90.

Received for publication 30 March 1990.