



SARCOCYSTIS SP. IN WADING BIRDS (CICONIIFORMES) FROM FLORIDA

Authors: Spalding, Marilyn G., Atkinson, Carter T., and Carleton, Renee E.

Source: Journal of Wildlife Diseases, 30(1) : 29-35

Published By: Wildlife Disease Association

URL: <https://doi.org/10.7589/0090-3558-30.1.29>

BioOne Complete (complete.BioOne.org) is a full-text database of 200 subscribed and open-access titles in the biological, ecological, and environmental sciences published by nonprofit societies, associations, museums, institutions, and presses.

Your use of this PDF, the BioOne Complete website, and all posted and associated content indicates your acceptance of BioOne's Terms of Use, available at www.bioone.org/terms-of-use.

Usage of BioOne Complete content is strictly limited to personal, educational, and non - commercial use. Commercial inquiries or rights and permissions requests should be directed to the individual publisher as copyright holder.

BioOne sees sustainable scholarly publishing as an inherently collaborative enterprise connecting authors, nonprofit publishers, academic institutions, research libraries, and research funders in the common goal of maximizing access to critical research.

SARCOCYSTIS SP. IN WADING BIRDS (CICONIIFORMES) FROM FLORIDA

Marilyn G. Spalding,¹ Carter T. Atkinson,² and Renee E. Carleton¹

¹ Department of Infectious Diseases, College of Veterinary Medicine, University of Florida, Gainesville, Florida 32611, USA

² National Wildlife Health Research Center, Hawaii Volcanoes Field Station, P.O. Box 218, Hawaii Volcanoes National Park, Hawaii 96718, USA

ABSTRACT: Sarcocysts were found in striated muscle of 21 adult wading birds among 145 examined grossly and 70 examined histologically (calculated prevalence = 24%), and in none of 332 immature wading birds examined from Florida (USA). Six of 12 species of ciconiiforms were infected (*Ardea herodias*, *Casmerodius albus*, *Egretta caerulea*, *Nyctanassa violacea*, *Butorides striatus*, *Eudocimus albus*). Cysts were filamentous, usually extended the entire length of the muscle fiber, and were visible grossly in 33% of the positive cases. We concluded from ultrastructural examination of cysts that the same species of *Sarcocystis* may occur in all species of wading birds in Florida; however, two cyst diameters were noted that appeared to differ in their distribution by host species.

Key words: *Sarcocystis*, Ciconiiformes, Florida, protozoa, survey.

INTRODUCTION

Cysts of *Sarcocystis* spp. typically occur in muscles of intermediate hosts which are prey of the definitive host; however, sarcocysts have been reported in muscle of predatory falconiforms (Crawley et al., 1982) and mammals (Greiner et al., 1989). Wading birds potentially meet the criteria of both intermediate and definitive hosts because they are predatory, and also are consumed by both mammalian (Lipinot, 1951) and avian (Norman et al., 1989) predators. We could find no report of intestinal gametogony, characteristic of the definitive host stage, for wading birds.

Munday et al. (1979) reported sarcocysts in five of 28 individual ardeids (infected species included *Ardea pacifica*, *Egretta alba*, and *Nycticorax caledonicus*), and in one of 27 individual threskiornithids (only *Platalea flavipes* infected) examined from Australia. Kaiser and Markus (1983) found 33% of ciconiiforms to be infected in South Africa; infected species included *Egretta garzetta*, *Egretta intermedia*, *Bubulcus ibis*, *Nycticorax nycticorax*, *Bostrychia hagedash*. Sarcocysts have been described in a captive lesser flamingo (*Phoeniconaias minor*) (Murata, 1986), a wild lesser flamingo (Karstad et al., 1982); Aquirre et al. (1991) found *Besnoitia*-like cysts in small intestine smooth muscle and merozoites in

pectoral muscle of immature wild Caribbean flamingos (*Phoenicopterus ruber ruber*) in Mexico. We found only one report of sarcocysts in wading birds in North America: a great blue heron in Maryland (Clark, 1958). Our objective was to determine the prevalence of *Sarcocystis* spp. infection among birds of Florida (USA); this was part of a larger study to determine cause-of-death for wading birds in Florida.

MATERIALS AND METHODS

Carcasses of 477 wading birds were collected from peninsular Florida (24° to 30°N, 80° to 83°W), 1987 to 1992. All were >1 wk of age and were not severely autolytic. They consisted of birds found dead in nesting colonies, along roadsides, with the aid of radiotransmitters, or were birds submitted to rehabilitation centers and which died ≤3 days of submission. The following species were examined: great blue heron (*Ardea herodias*) and a color morph which nests only in Florida Bay, the great white heron (*A. h. occidentalis*) ($n = 156$); great egret (*Casmerodius albus*) ($n = 81$); snowy egret (*Egretta thula*) ($n = 60$); tricolored heron (*E. tricolor*) ($n = 31$); little blue heron (*E. caerulea*) ($n = 18$); reddish egret (*E. rufescens*) ($n = 6$); black-crowned night heron (*Nycticorax nycticorax*) ($n = 2$); yellow-crowned night heron (*Nyctanassa violacea*) ($n = 5$); green-backed heron (*Butorides striatus*) ($n = 11$); white ibis (*Eudocimus albus*) ($n = 37$); roseate spoonbill (*Ajaja ajaja*) ($n = 67$); and wood stork (*Mycteria americana*) ($n = 3$).

Striated muscle was examined grossly for sar-

TABLE 1. Calculated prevalence of sarcocysts in striated muscle of immature and adult ciconiforms identified by gross and histologic examination in Florida, 1987 to 1992.

Host	Gross exam all birds		Histologic exam on birds with no gross cysts		Calculated* percent of adults infected (if $n > 4$)
	Immature	Adult	Immature	Adult	
Ardeidae					
Great blue/white heron	0/74 ^b	3/82	0/32	5/30	20
Great egret	0/53	4/28	0/14	1/15	20
Snowy egret	0/54	0/6	0/3	0/4	
Tricolored heron	0/28	0/3	0/6	0/2	
Little blue heron	0/15	0/3	0/3	3/3	
Reddish egret	0/5	0/1	0/3	—	
Black-crowned night-heron	0/1	0/1	—	0/1	
Yellow-crowned night-heron	0/1	0/4	—	1/1	
Green-backed heron	0/3	0/8	—	2/7	29
Threskiornithidae					
Roseate spoonbill	0/64	0/3	0/28	0/2	
White ibis	0/31	0/6	0/1	2/5	40
Ciconiidae					
Wood stork	0/3	—	0/1	—	
Total	0/332	7/145	0/91	14/70	24

* [Number grossly infected + proportion identified by histologic exam (number with no gross lesions)] \times 100/total number examined.

^b Number infected/number examined.

cocysts in all birds. Samples of pectoral muscle from the seven grossly infected birds and 161 of the birds with no gross cysts were fixed in 10% neutral buffered formalin and embedded in paraffin. Six micron thick sections stained with hematoxylin and eosin were prepared. Muscle sections were scanned for the presence of sarcocysts using a compound microscope at 100 \times power and the smallest diameter of 10 of each cyst stage was measured for each bird when possible. Stages of cysts were categorized as immature (stage 1), intermediate (stage 2), or mature or degenerating (stage 3) according to Smith et al. (1989) and Neill et al. (1989).

Tissues were prepared for electron microscopy as described by Atkinson et al. (1993). Transmission electron microscopy (TEM) was used to examine the cysts in two great white herons, one great blue heron, one great egret, one little blue heron, and to examine two cyst types in a great egret.

Cyst stage 3 measurements were solved for maximum likelihood estimates of parameters describing a mixture of two normal distributions using Newton-Raphson algorithm. The computation was done using the interactive matrix algebra language procedure (PROC IML) in SAS System (SAS Institute Inc., 1985). Analysis of variance (ANOVA) was used to test cyst size by

species of wading bird. A chi square test was used to test differences in prevalence between sexes (Siegel, 1956). Paraffin blocks containing representative specimens have been deposited in the Registry of Comparative Pathology, Armed Forces Institute of Pathology, Washington, D.C. 20306, USA (Accession Nos. 2401021–2401027).

RESULTS

No sarcocysts were observed in muscle tissue of immature ciconiforms examined grossly ($n = 332$) or histologically ($n = 91$) (Table 1). Cysts were observed in 21 adult birds. In seven (5%) of 145 adults, cysts were observed by gross examination of striated muscle, and in 14 (20%) of 70 adults, cysts were found by histologic examination when no cysts were observed by gross examination. Macroscopic cysts were seen in only 33% of the infected birds and in only two species, great blue/white herons and great egrets. Prevalence was calculated by multiplying the percentage of infected birds with no grossly observed cysts by the

total number without gross cysts, adding the number of birds with gross cysts, and dividing by the total number examined. The calculated prevalence for all ciconiiforms was 24%.

Cysts were white, opaque, and had a mean (\pm SE) diameter of $80.8 \pm 62 \mu\text{m}$ (range = 14 to $365 \mu\text{m}$); they appeared to extend the entire length of the muscle fiber, which was $\geq 15 \text{ cm}$ in pectoral muscle of the larger species. Cysts were most easily observed and most consistently found in the deep pectoral muscles (Fig. 1). They never were observed in heart muscle. In birds with severe grossly visible infections, it was common to see cysts throughout the striated musculature of the body. It could not be determined if these long cysts consisted of one long cyst or of many cysts stacked within a fiber; however discontinuous cysts within a fiber were never seen grossly or histologically. In only one case did we find shorter cysts similar to those described as “grains of rice” or cysts that appeared to end within a fiber. No differences in cyst walls were observed at the ultrastructural level. However, because this bird was infected with both cyst shapes, we could not be sure that we were actually observing a short cyst by TEM.

Cysts were classified into immature, intermediate, or mature or degenerating cyst stage (Fig. 2). The three cyst stages differed from each other in diameter (stage 1, \bar{x} (\pm SE) = $27.2 \pm 19.6 \mu\text{m}$, (16.8 to $88.8 \mu\text{m}$), $n = 12$; stage 2, \bar{x} (\pm SE) = $69.9 \pm 50.5 \mu\text{m}$, (14.4 to $232.8 \mu\text{m}$), $n = 124$; stage 3, \bar{x} (\pm SE) = $123.3 \pm 74.2 \mu\text{m}$, (21.6 to $365.8 \mu\text{m}$), $n = 47$) (ANOVA, log transformed, $P < 0.001$).

Stage 3 cysts were found in four species of wading birds. There appeared to be two size populations within the stage 3 cysts ($P = 0.07$, log transformed) (Fig. 3). The smaller cysts had a mean (\pm SE) of $44.2 \pm 5.9 \mu\text{m}$ and occurred in all four species. The mean (\pm SE) for larger cysts was $162.2 \pm 14.1 \mu\text{m}$; these cysts only occurred in great blue/white herons and great egrets. There were significant differences in cyst

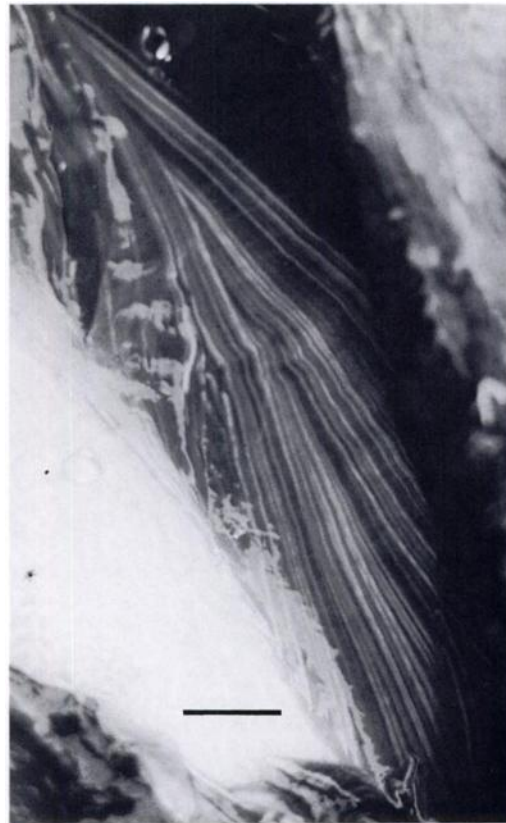

FIGURE 1. Exposed deep pectoral muscle on the sternum of a great white heron illustrating the filamentous nature of sarcocysts. Bar = 1 cm.

stage 3 size by species (ANOVA, log transformed, $P < 0.05$). Cysts in great blue herons (\bar{x} (\pm SE) = $154.8 \pm 39.4 \mu\text{m}$) and great egrets (\bar{x} (\pm SE) = $146.4 \pm 84.1 \mu\text{m}$) were significantly larger than those in little blue herons (\bar{x} (\pm SE) = $30.5 \pm 6.3 \mu\text{m}$). A single white ibis cyst ($62.4 \mu\text{m}$) did not differ significantly from any other species.

Sarcocysts were not observed in tissues other than striated muscle in 151 of these same wading birds examined histologically for cause of death (Spalding, unpubl.). Myositis was present in only one case, and myodegeneration in another. However, in both of these cases there was another potential cause for the lesions, and they did not appear to be centered around cysts.

Infected birds were found throughout the state with no significant distribution

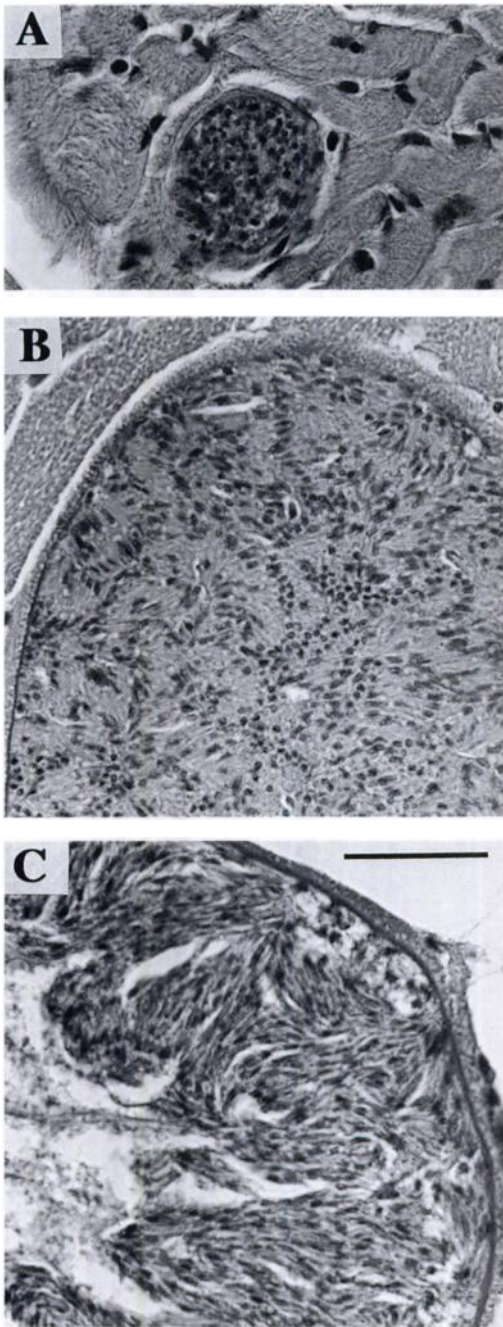


FIGURE 2. Light photomicrographs of pectoral muscle of ciconiforms illustrating the different stages of sarcocysts encountered. A) immature cyst containing merozoites in a green-backed heron, B) intermediate stage cyst containing bradyzoites in a great egret and C) mature stage cyst containing bradyzoites and degenerate material centrally in a great white heron. H&E. Bar = 20 μ m for each.

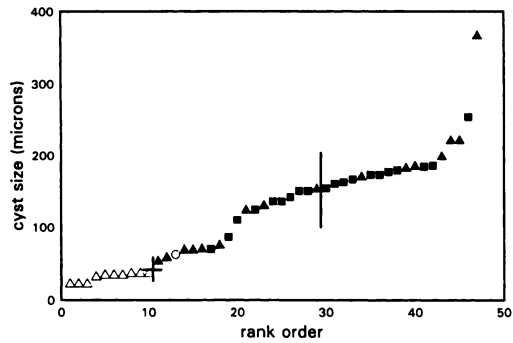


FIGURE 3. Mean and standard error bars for the minimum diameter of two size populations of stage 3 cysts in four species of ciconiforms, great blue/white herons (■), great egrets (▲), little blue herons (Δ), and white ibis (O). Forty-seven stage 3 cysts are plotted in rank order by size.

pattern for region or habitat (Fig. 4). Based on a chi-square test, no significant difference was found in prevalence between 68 females (19%) and 78 males (10%) ($P < 0.20$).

Ultrastructural morphology of the cyst wall was similar in multiple cysts in all of the cases examined by TEM (Figs. 5 and 6) and resembled Type 9 sarcocysts described by Dubey et al. (1989). No ultrastructural differences in cyst wall morphology were observed among any of the cysts other than those which could be at-

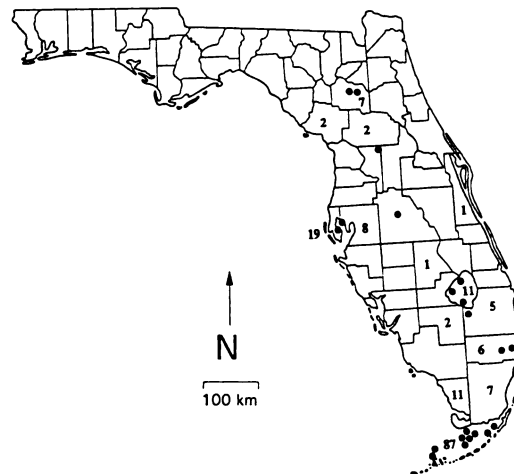


FIGURE 4. Distribution of *Sarcocystis* sp. infected individuals (●) and sample size by county (numbers) for ciconiforms collected in Florida, 1987-92.

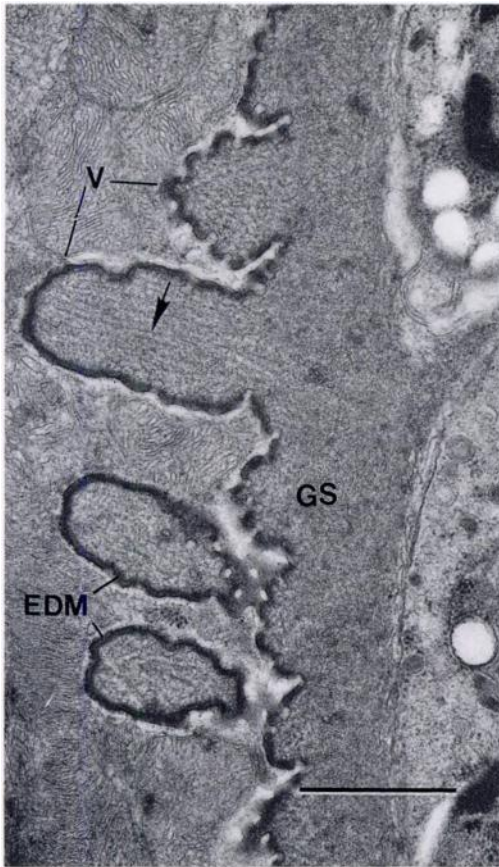


FIGURE 5. Electron micrograph of the wall of a sarcocyst from a great blue heron. The cyst wall is composed of broad villar projections (V) with uneven, slightly undulating surfaces. The parasitophorous vacuole membrane is underlain by a thin layer of electron-dense, submembranous material (EDM). Villi contain intermediate filaments (arrow) that are embedded in an amorphous substance that is continuous with the ground substance (GS) of the cyst wall. Bar = 1 μm .

tributed to differences in quality of fixation. All appeared to be mature cysts containing bradyzoites. All were septate, conforming to the morphology of *Sarcocystis* spp. The cyst wall contained broad-based villar projections with uneven, undulating villar surfaces and was underlain by a narrow band of electron-dense submembranous material. The core of the villi contained intermediate filaments. Measurements of two well-fixed sarcocysts from a great blue heron and a great egret were

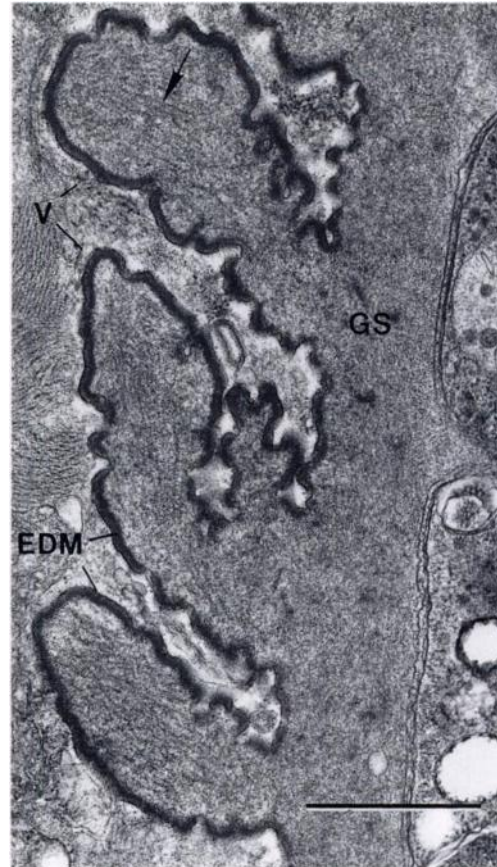

FIGURE 6. Electron micrograph of the wall of a sarcocyst from a great egret. The structure of the cyst wall is identical to that from other species of wading birds. Note broad villar projections (V), electron-dense, submembranous material (EDM), intermediate filaments (arrows) in the villar cores and amorphous ground substance (GS) of the cyst wall. Bar = 1 μm .

similar. Depending on plane of sections, the cyst from the great blue heron had a wall thickness ranging from 0.94 μm to 2.40 μm (\bar{x} ($\pm\text{SE}$) = 1.79 \pm 0.36 μm , n = 15). The ground substance in this cyst ranged from 0.32 to 0.99 μm in thickness (\bar{x} = 0.56 \pm 0.20 μm , n = 16). Villar projections had basal diameters of 0.38 to 0.71 μm (\bar{x} = 0.57 \pm 0.12 μm , n = 16). The cyst from the great egret had slightly thicker walls that ranged from 1.58 to 3.67 μm (\bar{x} = 2.52 \pm 0.62 μm , n = 13) in thickness. The ground substance was also thicker, ranging from 0.71 to 1.67 μm (\bar{x} = 1.01 \pm 0.37 μm , n = 12). Villar projections had

basal diameters of 0.56 to 1.22 μm (\bar{x} = $0.82 \pm 0.22 \mu\text{m}$, $n = 11$).

DISCUSSION

Sarcocysts were found in a relatively high prevalence in adult wading birds when compared to other species such as mottled ducks (*Anas fulvigula*), which had a prevalence of 14% with macrocysts in adults (Moorman et al., 1991). When compared with surveys of ciconiforms on other continents, prevalences were similar (33%, Africa; Kaiser and Markus, 1983) or higher (7%, Australia; Munday et al., 1979). The presence of sarcocysts in great white herons, which do not migrate outside of Florida, is evidence that transmission occurred within Florida. Cyst development in striated muscle occurred at 8 days post inoculation in experimentally infected budgerigars (Smith et al., 1989). Therefore, the complete absence of cysts in nestling (≤ 2 mo of age) and fledged birds with immature plumage (≤ 3 yr of age) is probably not due to age alone. Other factors such as season, foraging habitat, region, or exposure to paratenic hosts, may be important in the life cycle of *Sarcocystis* spp. in these species.

The cysts found in wading birds were not the typical "rice grain" shaped cysts that have been described for many species (Tuggle, 1987), including the lesser flamingo (*Phoenicopterus minor*) (averaging 2.7×1.03 mm, the longest was 3.10 mm; Murata, 1986). Munday et al. (1979) mentioned cysts measuring ≤ 2.5 mm in grebes (*Podiceps poliocephalus*), cormorants (*Phalacrocorax melanoleucus*), and a pelican (*Pelecanus conspicillatus*). However, this was a histologic measurement and he did not find any macroscopic cysts in his survey of birds (including ciconiforms) in Australia. Clark (1958) described long sarcocysts in leg muscle and smaller cysts in cardiac muscle of a great blue heron.

It appears that the cysts examined in this study were all one species based upon ultrastructural analysis. Without further ultrastructural analysis and experimental in-

fections this is only speculative. Based on the measurement of the cyst diameter, however, either two species were present, or cyst size was somehow regulated by host species. The larger cysts were found in the two larger species of wading birds, great blue/white herons and great egrets, the same two species for which macroscopic cysts were observed. No differences were noted in uninfected muscle fiber diameters between the larger and smaller wading birds; therefore, it does not appear that fiber size was regulating the cyst diameter. Box and Smith (1982) found little intermediate host specificity to *Sarcocystis* sp. between different orders of birds experimentally, unlike mammalian species. The diets, foraging habitats, and nesting locations of all ciconiforms included in this study overlapped considerably, and thus could account for infections by only one or two species of *Sarcocystis* spp.

The potential definitive hosts for sarcocysts in wading birds include many groups. The most common predator of wading birds in Florida Bay is the bald eagle (*Haliaeetus leucocephalus*) (Spalding, unpubl.). Eagles commonly nest in wading bird colonies and wading bird carcasses have been found in their nests in Florida and elsewhere (Baldwin, 1940; Immler and Kalmbach, 1955). Sporocysts have been found in the feces of bald eagles in Florida (Carleton, unpubl.) and elsewhere (Tuggle, 1982). Other important predators of wading birds in Florida include vultures, other falconiformes, raccoons and alligators (Frederick and Spalding, 1993). Vultures scavenge many wading birds and are found commonly in wading bird colonies.

ACKNOWLEDGMENTS

We thank the following for assisting with procuring or providing specimens or assisting with necropsy examinations: Tom Bancroft, Robin Bjork, Naomi Edelson, Peter Frederick, Deborah Jansen, Howard Jelks, John Ogden, George Powell, Darren Rumbold, Jeff Smith, Garry Foster, Sylvia Tucker, John Simon, Mary Beth Decker, Su Jewell, Allen Strong, Rick Sawicki,

Cindy Thompson, Alison Brody, Jessie Lowe, Chris Beale, Harriet Powell, Charlotte Wilson, Robin Corcoran, Laura Quinn, and Barbara Suto. Discussions with Donald Forrester and Ellis Greiner contributed to the results reported here. Ana Milosavljevic assisted with sectioning tissues. Steve Linda performed the statistical analysis of cyst size. This research was supported by the Nongame Program of the Florida Game and Fresh Water Fish Commission (Contract #88007) and the National Audubon Society Research Office in Tavernier, Florida. This is Florida Agricultural Experiment Stations Journal Series No. R-03124.

LITERATURE CITED

- AGUIRRE, A. A., R. S. COOK, R. G. MCLEAN, T. J. QUAN, AND T. R. SPRAKER. 1991. Occurrence of potential pathogens in wild caribbean flamingos (*Phoenicopterus ruber ruber*) during a lead poisoning die off in Yucatan, Mexico. *Journal of Zoo and Wildlife Medicine* 22: 470-475.
- ATKINSON, C. T., S. D. WRIGHT, S. R. TELFORD, JR., G. S. MCLAUGHLIN, D. J. FORRESTER, M. E. ROELKE, AND J. W. McCOWN. 1993. Morphology, prevalence, and distribution of *Sarcocystis* spp. in white-tailed deer (*Odocoileus virginianus*) from Florida. *Journal of Wildlife Diseases* 29: 73-84.
- BALDWIN, W. P. 1940. Bald eagle robbing marsh hawk. *The Auk* 57: 413.
- BOX, E. D., AND J. H. SMITH. 1982. The intermediate host spectrum in a *Sarcocystis* species of birds. *The Journal of Parasitology* 68: 668-673.
- CLARK, G. M. 1958. *Sarcocystis* in certain birds. *The Journal of Parasitology* 44: 41.
- CRAWLEY, R. R., J. V. ERNST, AND J. L. MILTON. 1982. *Sarcocystis* in a bald eagle (*Haliaeetus leucocephalus*). *Journal of Wildlife Diseases* 18: 253-255.
- DUBEY, J. P., C. A. SPEER, AND R. FAYER. 1989. *Sarcocystosis of animals and man*. CRC Press, Boca Raton, Florida, 215 pp.
- FREDERICK, P. C., AND M. G. SPALDING. 1993. Factors affecting reproductive success by wading birds (Ciconiiformes) in the Everglades ecosystem. In *The everglades: The ecosystem and its restoration*, S. M. Davis and J. C. Ogden (eds.). St. Lucie Press, Delray Beach, Florida. In press.
- GREINER, E. C., M. E. ROELKE, C. T. ATKINSON, J. P. DUBEY, AND S. D. WRIGHT. 1989. *Sarcocystis* sp. in muscles of free-ranging Florida panthers and cougars (*Felis concolor*). *Journal of Wildlife Diseases* 25: 623-628.
- IMLER, R. H., AND E. R. KALMBACH. 1955. The bald eagle and its economic status. U.S. Fish and Wildlife Service Circular 30, U.S. Department of Interior, Washington, D.C., 51 pp.
- KAISER, I. A., AND M. B. MARKUS. 1983. *Sarcocystis* infection in wild southern African birds. *South African Journal of Science* 79: 470-471.
- KARSTAD, L., L. SILEO, AND W. J. HARTLEY. 1982. A *Besnoitia*-like parasite associated with arteritis in flamingos. In *Wildlife diseases of the Pacific Basin and other countries*, M. Fowler (ed.). Proceedings of the 4th International Conference of the Wildlife Disease Association, Wildlife Disease Association, Lawrence, Kansas, pp. 98-101.
- LIPINOT, A. C. 1951. Raccoon predation on the great blue heron, *Ardea herodias*. *The Auk* 68: 235.
- MOORMAN, T. E., G. A. BALDASSARRE, AND D. M. RICHARD. 1991. The frequency of *Sarcocystis* spp. and its effect on winter carcass composition of mottled ducks. *Journal of Wildlife Diseases* 27: 491-493.
- MUNDAY, B. L., W. J. HARTLEY, K. E. HARRINGAN, P. J. A. PRESIDENTE, AND D. L. OBENDORF. 1979. *Sarcocystis* and related organisms in Australian wildlife: II. Survey findings in birds, reptiles, amphibians, and fish. *Journal of Wildlife Diseases* 15: 57-73.
- MURATA, K. 1986. A case report of *Sarcocystis* infection in a lesser flamingo. *Japanese Journal of Parasitology* 35: 555-557.
- NEILL, P. J. G., J. H. SMITH, AND E. D. BOX. 1989. Pathogenesis of *Sarcocystis falcatula* (Apicomplexa: Sarcocystidae) in the budgerigar (*Melopsittacus undulatus*) IV. Ultrastructure of developing, mature and degenerating sarcocysts. *The Journal of Protozoology* 36: 430-437.
- NORMAN, D. M., A. M. BREAUULT, AND I. E. MOUL. 1989. Bald eagle incursions and predation at great blue heron colonies. *Colonial Waterbirds* 12: 215-217.
- SAS INSTITUTE INC. 1985. SAS/IML® user's guide for personal computers, Version 6. SAS Institute Inc., Cary, North Carolina, 243 pp.
- SIEGEL, S. 1956. *Nonparametric statistics for the behavioral science*. McGraw-Hill Inc., New York, New York, 312 pp.
- SMITH, J. H., P. J. G. NEILL, AND E. D. BOX. 1989. Pathogenesis of *Sarcocystis falcatula* (Apicomplexa: Sarcocystidae) in the budgerigar (*Melopsittacus undulatus*) III. Pathologic and quantitative parasitologic analysis of extrapulmonary disease. *The Journal of Parasitology* 75: 270-287.
- TUGGLE, B. N. 1982. Parasites of the bald eagle (*Haliaeetus leucocephalus*) of North America. *Journal of Wildlife Diseases* 16: 501-506.
- . 1987. *Sarcocystis*. In *Field guide to wildlife diseases*. Vol. 1. General field procedures and diseases of migratory birds, M. Friend (ed.). Resource Publication 167, U.S. Fish and Wildlife Service, Washington, D.C., pp. 153-158.

Received for publication 30 March 1993.