

## **EVALUATION OF HAWAIIAN GREEN TURTLES (CHELONIA MYDAS) FOR POTENTIAL PATHOGENS ASSOCIATED WITH FIBROPAPILLOMAS**

Authors: Aguirre, A. Alonso, Balazs, George H., Zimmerman, B., and Spraker, Terry R.

Source: Journal of Wildlife Diseases, 30(1) : 8-15

Published By: Wildlife Disease Association

URL: <https://doi.org/10.7589/0090-3558-30.1.8>

---

BioOne Complete ([complete.BioOne.org](https://complete.BioOne.org)) is a full-text database of 200 subscribed and open-access titles in the biological, ecological, and environmental sciences published by nonprofit societies, associations, museums, institutions, and presses.

Your use of this PDF, the BioOne Complete website, and all posted and associated content indicates your acceptance of BioOne's Terms of Use, available at [www.bioone.org/terms-of-use](https://www.bioone.org/terms-of-use).

Usage of BioOne Complete content is strictly limited to personal, educational, and non - commercial use. Commercial inquiries or rights and permissions requests should be directed to the individual publisher as copyright holder.

---

BioOne sees sustainable scholarly publishing as an inherently collaborative enterprise connecting authors, nonprofit publishers, academic institutions, research libraries, and research funders in the common goal of maximizing access to critical research.

## EVALUATION OF HAWAIIAN GREEN TURTLES (*CHELONIA MYDAS*) FOR POTENTIAL PATHOGENS ASSOCIATED WITH FIBROPAPILLOMAS

A. Alonso Aguirre,<sup>1,3</sup> George H. Balazs,<sup>2</sup> B. Zimmerman,<sup>3</sup> and Terry R. Spraker<sup>4</sup>

<sup>1</sup> Department of Fishery and Wildlife Biology, Colorado State University, P.O. Box 1522, Fort Collins, Colorado 80522, USA

<sup>2</sup> National Marine Fisheries Service, Southwest Fisheries Science Center, Honolulu Laboratory, 2570 Dole Street, Honolulu, Hawaii 96822-2396, USA

<sup>3</sup> Wildlife Pharmaceuticals, Inc., 1401 Duff Drive, Suite 600, Fort Collins, Colorado 80524, USA

<sup>4</sup> Diagnostic Laboratory, College of Veterinary Medicine, Colorado State University, Fort Collins, Colorado 80523, USA

**ABSTRACT:** Thirty-two juvenile green turtles (*Chelonia mydas*) were captured alive in Kaneohe Bay, Island of Oahu, Hawaii, during September 1991. Ten of the turtles sampled were afflicted with green turtle fibropapillomatosis (GTFP) in varying degrees of severity. Virus isolation attempts were negative in all individuals. Using nasopharyngeal and cloacal swabs, we isolated 28 Gram negative bacteria, five Gram positive cocci, *Bacillus* spp., and diphtheroids. The most common isolates included *Pseudomonas fluorescens* (68%), *P. putrefaciens* (66%), *Vibrio alginolyticus* (50%), non-hemolytic *Streptococcus* (50%), *V. damsela* (47%), and *V. fluvialis* (47%). Chlamydial antigen was detected in four of the turtles sampled. The primary lesions in animals with GTFP were hyperplasia of squamous epithelial cells and mesodermal proliferation with a marked degree of orthokeratotic hyperkeratosis. Mites, leeches, and other organisms were associated with the surface of papilloma lesions. The etiologic agent of GTFP was not isolated.

**Key words:** Bacteriology, *Chelonia mydas*, disease survey, fibropapillomas, green turtle, Hawaii, histopathology.

### INTRODUCTION

Green turtle fibropapillomatosis (GTFP) is a condition affecting the green turtle (*Chelonia mydas*) in several parts of the world including Florida (USA), Hawaii (USA), Australia, Bahamas, Barbados, Belize, Cayman Islands, Dominican Republic, Curaçao, Colombia, Panama, Puerto Rico, Venezuela, and Virgin Islands (Jacobson et al., 1991; Balazs and Pooley, 1991). This condition was first described in the Caribbean during the 1930's (Smith and Coates, 1939), but only in recent years has its worldwide incidence increased to epizootic proportions. A number of workers have suggested etiology by papillomavirus or herpesvirus (Balazs and Pooley, 1991; Jacobson et al., 1991). Other possible etiologic agents include an immune response to trematode ova, secretion of hirudin by marine leeches, excessive solar radiation, chemical pollutants impairing the immune system, stress, and a genetic predisposition to neoplasia (Balazs and Pooley, 1991).

Evidence of infection to potential pathogens epidemiologically linked to the

etiologic agent of GTFP is necessary to provide information on the health status of a population in endemic areas affected by GTFP (Aguirre, 1991). Our objective was to identify potentially pathogenic bacteria and other disease agents among green turtles both afflicted with, and free of, GTFP on Oahu, Hawaii. Tumor biopsies of turtles afflicted with GTFP also were characterized.

### MATERIALS AND METHODS

Kaneohe Bay (21°30'N, 157°50'W), Island of Oahu, Hawaii, is the largest bay in the Hawaiian islands comprising substantial foraging and resting habitat for green turtles. The earliest confirmed case of GTFP in Hawaii was reported in Kaneohe Bay in 1958 (Balazs, 1991). Live-captured turtles in this bay have had GTFP prevalences of 49 to 92% since February 1989, depending upon the study site sampled (Balazs, 1991).

Thirty-two green turtles were captured alive and unharmed by hand while snorkeling, 20 to 26 September 1991. Turtles were trapped at three sites in Kaneohe Bay: Ahu-O-Laka ( $n = 28$ ), Mark Reef ( $n = 2$ ) and Reef 42 ( $n = 2$ ). Turtles were transported a short distance by boat to the research facilities provided by the Hawaii Institute of Marine Biology on Coconut

Island located in Kaneohe Bay. Upon arrival, turtles were measured, tagged, and weighed following techniques described by Balazs et al. (1987). Barnacles (*Chelonibia testudinaria*) on the dorsal and ventral surfaces of the turtles were counted. The size, number, and location of the tumors were evaluated in turtles with GTFP. Turtles were coded by degree of tumor severity on a scale of 1 to 4, 4 being the most severe case. This evaluation was based on the size, number, and location of the tumors present (Balazs, 1991).

A set of nasopharyngeal and cloacal swabs was taken from all individuals and immediately placed in labeled vials containing a virus isolation diluent (VID) consisting of isotonic buffered (0.85%) saline solution, 0.1% nutrient broth (Bacto-Peptone®, Difco Laboratories, Detroit, Michigan, USA), 0.003% gelatin (Bacto-Gelatin®, Difco Laboratories) and 50 µg/ml gentamicin sulphate (Gentocin®, Schering Co., Kenilworth, New Jersey, USA). The vials were frozen at -70 C prior to their submission to the Hatfield Marine Science Center, Laboratory for Fish Disease Research, Newport, Oregon (USA).

Two sets of nasopharyngeal and cloacal swabs were taken for bacterial isolation and identification. A set of swabs was immediately placed in labeled vials containing Cary-Blair Transport Medium (Difco Laboratories); the second set was placed in Modified Stuart's Bacterial Transport Medium (Culturette®, Baxter Scientific Products, McGraw Park, Illinois, USA). All specimens were express-mailed to the Department of Health Services Office of the County Veterinarian Laboratory, San Diego, California (USA), for bacterial isolation and identification.

Cloacal swabs were collected from all 32 green turtles and immediately placed in labeled vials containing Bovarnick's Buffer Transport Medium with 10% fetal calf serum (Spencer and Johnson, 1983). Sealed tubes were frozen at -70 C for the detection of *Chlamydia* spp. antigen.

Two biopsies of early growths were collected from each of 10 green turtles with fibropapillomas. One biopsy was fixed in 10% neutral buffered formalin for histopathologic evaluation. A second biopsy was fixed in Karnovsky's solution (phosphate buffered 4.0% formaldehyde and 1.0% glutaraldehyde) and held at 4 C until evaluated with both light and transmission electron microscopy (McDowell, 1978).

Swabs transported in VID were defrosted and diluted each with 1 ml of Eagle's Minimum Essential Medium containing 200 IU penicillin and 200 µg streptomycin/ml, 10% fetal bovine serum, and 200 mM HEPES buffer (all from Sigma Chemical Company, St. Louis, Missouri, USA). Dilutions were vigorously mixed with a vortex mixer and inoculated onto four fish cell

lines commonly used in fish virology (American Type Culture Collection (ATCC), Rockville, Maryland, USA). These cell lines were originated from *Oncorhynchus tshawytscha* (CHSE-214, ATCC CRL 1681), *O. mykiss* (RTG-2, ATCC CCL 55), *Pimephales promelas* (FHM, ATCC CCL 42), and *Cyprinus carpio* (EPC). A sample of 0.05 ml of each preparation was inoculated onto each of four wells of a 96-well plate of each cell line. These cultures were incubated at 18 C and observed. Culture fluid and cell debris from wells displaying cytopathic effects were diluted at 1:100 then transferred to fresh cell cultures and further incubated and observed. Final subcultures were incubated for 28 days.

Material from nasopharyngeal and cloacal swabs and tissue specimens were cultured on blood agar (5% sheep blood), MacConkey agar, trypticase soy agar, and seawater agar (Difco Laboratories). To support organisms with an obligate salt requirement, all media contained 3% sodium chloride (NaCl). Plates were incubated at 25 C aerobically, then examined after 24 hr. If there was little or no growth, plates were incubated for an additional 24 hr. Each distinctive colony, based on color, texture, and growth pattern, was treated as a separate organism and isolated on blood agar plates for identification. Microorganisms were separated based on Gram reaction and morphology. Gram-negative bacteria were biochemically identified by the API 20E System® (Sherwood Medical, Plainview, New York, USA). Gram-positive organisms were identified based on colonial and cellular morphology and staining characteristics (Balows and Hausler, 1981).

A direct-binding monoclonal based enzyme immunoassay, the KODAK SURECELL™ Chlamydia Test Kit (Eastman Kodak Company, Clinical Products Division, Rochester, New York), was used for the rapid detection of chlamydial antigen. The test was performed according to the manufacturer's directions, except that centrifugation of the transport media containing fecal material was omitted.

For histopathology, fixed fibropapilloma lesions were embedded in paraffin, sectioned 6-µm thick, and stained with hematoxylin and eosin. Skin lesions later were prepared for transmission electron microscopy. One to 2 µm survey sections were cut from the blocks, stained with methylene blue-azure II-basic fuchsin, and examined with a light microscope (Hayat, 1986). Ultrathin sections from the tumor biopsies of two turtles were placed on copper grids, stained with uranyl acetate and lead citrate, and examined with a transmission electron microscope by Dr. Robert E. Lee (Colorado State University, Department of Anatomy and Neurobiology).

gy, Fort Collins, Colorado, USA) using the methods of Hayat (1986).

Biologic and bacteriologic data obtained from both, turtles afflicted with GTFP and turtles free of the disease, were statistically analyzed by Student's *t*-test and chi-square test (Schlotzhauer and Littell, 1991). Results were considered significant if  $\alpha \leq 0.05$ .

### RESULTS

Ten (31%) of 32 green turtles, with a mean ( $\pm$ SE) weight of 19 ( $\pm$ 2.0) kg (range, 11.8 to 22.3 kg) and a mean ( $\pm$ SE) straight carapace length (SCL) of 560 ( $\pm$ 21) mm (range, 445 to 683 mm), had cutaneous and conjunctival fibropapillomas. The degree of tumor severity in the turtles captured varied from mild to very severe. The tumor severity codes were 1 for one turtle, 2 for three turtles, 3 for five turtles, and 4 for one turtle. Eight (29%) of 28 turtles obtained at the Ahu-O-Laka study site had tumors. The two turtles taken at Reef 42 had tumors and the two from Mark Reef were free of GTFP. Twenty-two (69%) of 32 turtles captured, with a mean ( $\pm$ SE) weight of 12.2 ( $\pm$ 1.0) kg (range, 7.7 to 25.5 kg) and a mean ( $\pm$ SE) SCL of 440 ( $\pm$ 11) mm (range, 374 to 552 mm), were visibly free of GTFP. Turtles afflicted with GTFP were significantly ( $P < 0.05$ ) larger and heavier than turtles free of the disease.

Lobulated tumors were present on the skin of the axillary and inguinal regions, between the scales and scutes, and on the conjunctiva and corner of the eyes. These also were present in the mouth of two turtles examined. Fibropapillomas were in several growth stages ranging from 3 mm in diameter in the conjunctiva to 28 cm in diameter around the cloaca. Early growths were small tumors pigmented brown to dark grey with a rough surface. Larger tumors had a "cauliflower" appearance or a smooth surface. In three of 10 cases, tumors were necrotic, bloody, and infested with marine leeches.

Barnacles were found on the carapace and plastron of nine of 10 turtles afflicted with GTFP and on 15 of 22 green turtles free of the disease. The mean ( $\pm$ SE) dorsal

barnacle count in the green turtles afflicted by GTFP was 12.5 ( $\pm$ 4.0) (range, 0 to 41) and mean ( $\pm$ SE) ventral barnacle count was 20.2 ( $\pm$ 6.0) (range, 0 to 65). The group free of GTFP had a mean ( $\pm$ SE) dorsal barnacle count of 7.8 ( $\pm$ 3.0) (range, 0 to 59) and ventral barnacle average count of 15.0 ( $\pm$ 5.0) (range, 0 to 75). No differences ( $P > 0.05$ ) were observed between barnacle counts when comparing both turtle groups.

Five tumor biopsies and 30 sets of nasopharyngeal and cloacal swabs were inoculated into fish cell lines. None of the culture fluids and cell debris yielded any virus or produced cytopathic effects after the 28-day incubation period. All early cell death in several specimens was caused by toxic materials in the original inoculum.

From the nasopharyngeal and cloacal swabs taken from the turtles we isolated 28 Gram negative bacteria, five Gram positive cocci, *Bacillus* spp., and diphtheroids (Table 1). *Pseudomonas fluorescens* was the most frequent bacterium isolated in both groups (22 of 32 turtles), followed by *P. putrefaciens* (21/32), *Vibrio alginolyticus* (16/32), non-hemolytic *Streptococcus* (16/32), *V. damsela* (15/32), and *V. fluvialis* (15/32). No significant differences ( $P > 0.05$ ) were identified in the prevalence of bacterial species isolated between the two turtle groups. The difference in the number of bacterial species isolated from each group was significant ( $P > 0.05$ ); 23 bacterial species were isolated from turtles with GTFP and 32 from turtles without GTFP.

The microorganisms isolated only from sea turtles with GTFP were *Hafnia alvei*, *Klebsiella oxytoca*, and *Pseudomonas stutzeri*, and came from three different individuals. Alpha-streptococci, *Escherichia coli*, and *Citrobacter diversus* were isolated from a single specimen free of GTFP. During the field studies, an apparently healthy turtle presented sloughing of the skin from the front flippers with no other apparent lesions. *Staphylococcus epidermidis*, *Vibrio damsela*, and *V. flu-*

TABLE 1. Bacterial species isolated from two transport media used to sample 32 green turtles (*Chelonia mydas*) captured in Kaneohe Bay, Oahu Island, Hawaii, 1991, afflicted with or free of green turtle fibropapillomas (GTFP).

Bacteria	Number positive	
	Turtles with GTFP (n = 10)	Turtles without GTFP (n = 22)
<i>Acinetobacter anitratus</i>	2	8
<i>A. lwoffii</i> <sup>a</sup>	1	1
<i>Bacillus</i> spp.	2	3
<i>Citrobacter diversus</i> <sup>a,b</sup>	0	1
<i>C. freundii</i> <sup>a</sup>	5	4
Diphtheroids	2	6
<i>Enterobacter aerogenes</i> <sup>a</sup>	1	2
<i>E. agglomerans</i>	0	2
<i>E. cloacae</i>	1	1
<i>Escherichia coli</i> <sup>a,c</sup>	0	1
<i>Hafnia alvei</i> <sup>a,c</sup>	1	0
<i>Klebsiella pneumoniae</i> <sup>d</sup>	0	2
<i>K. oxytoca</i> <sup>a</sup>	1	0
<i>Lactobacillus</i> spp.	1	2
<i>Micrococcus</i> spp.	3	7
<i>Morganella morganii</i> <sup>a</sup>	0	1
<i>Proteus mirabilis</i> <sup>a</sup>	1	2
<i>P. penneri</i> <sup>a</sup>	0	2
<i>P. vulgaris</i> <sup>a,b</sup>	0	1
<i>Providencia alcalifaciens</i> <sup>b</sup>	0	2
<i>Pseudomonas aeruginosa</i>	1	4
<i>P. fluorescens</i>	7	15
<i>P. maltophilia</i>	5	5
<i>P. putida</i>	2	4
<i>P. putrefaciens</i>	5	16
<i>P. stutzeri</i> <sup>a</sup>	1	0
<i>P. viscidularis</i> <sup>d</sup>	0	1
<i>Staphylococcus aureus</i> <sup>d</sup>	0	2
<i>S. epidermidis</i> <sup>d</sup>	1	6
<i>Streptococcus alpha</i> <sup>c</sup>	0	1
<i>S. non-hemolytic</i>	3	13
<i>Vibrio alginolyticus</i>	4	12
<i>V. damsela</i>	4	11
<i>V. fluvialis</i>	6	9
<i>Vibrio</i> spp. <sup>b,d</sup>	0	1

<sup>a</sup> Isolated from cloacal swabs but not nasopharyngeal swabs.

<sup>b</sup> Isolated from Stuart's transport medium but not Cary-Blair.

<sup>c</sup> Isolated from Cary-Blair transport medium but not Stuart's.

<sup>d</sup> Isolated from nasopharyngeal swabs but not cloacal swabs.

*vialis* were isolated from swabs taken from the dermis. Of the 32 cloacal swabs examined, two turtles free of GTFP had detectable chlamydial antigen. No attempts were made to further culture and isolate the microorganism.

Tumor specimens from 10 turtles were

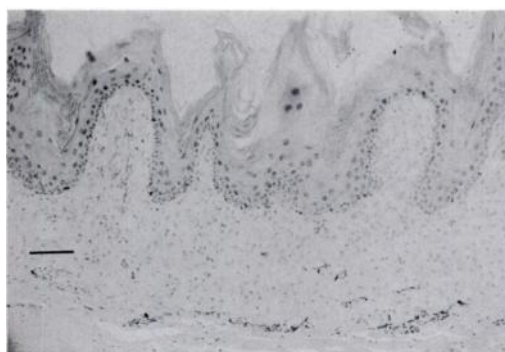


FIGURE 1. Hyperplasia and papillary projections of squamous epithelial cells, mesodermal proliferation, and hyperkeratosis of a green turtle fibropapilloma. H&E stain. Bar = 100  $\mu$ m.

examined for histopathology. The primary lesions in these animals were characterized by hyperplasia of squamous epithelial cells and mesodermal proliferation with a marked degree of orthokeratotic hyperkeratosis. In many places the epithelial cells formed outward papillary projections (Fig. 1). There was an extensive proliferation of fibroplastic cells underneath the squamous hyperplastic process. Necrotic foci were observed in the squamous epithelial cells of the epidermis in three of 10 turtle tumors. In many areas the lesions were flattened or plaque-like similar to a ballooning degeneration, whereas in others there was a papillary configuration with intercellular bridges in the epithelial cells. In some areas, lesions progressed from epidermis to dermis. Epithelial cells, especially in the outer edges of the epidermis, were markedly hypertrophic presenting large basophilic intranuclear bodies and extensive intracytoplasmic vacuolization.

In eight of 10 cases, granulomas containing a yellow nonstaining cuticle-like material both within normal dermis and within hyperplastic mesodermal areas were observed. These structures were identified histologically as spirorchid trematode eggs of the genus *Hapalotrema* (Fig. 2). One of the sections contained a specimen of the piscicolid leech *Ozobranchus branchiatus* attached to the surface of the tumor. At

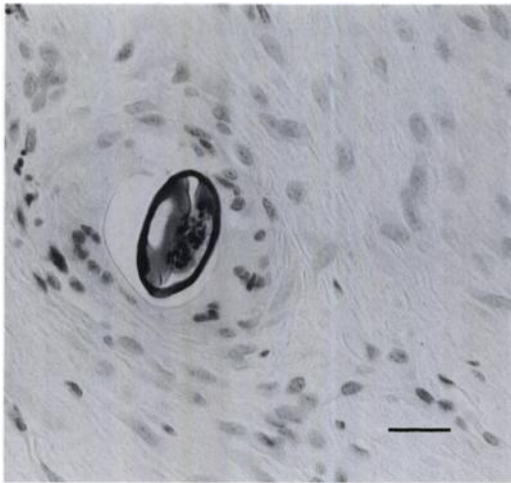


FIGURE 2. Spirorchid trematode egg within the dermis of a green turtle fibropapilloma. H&E stain. Bar = 500  $\mu$ m.

least nine of 10 of the specimens contained organisms compatible with yeast or algal growth and two contained fungi. These yeast, algae, and fungi were present on the surface and between layers of keratin. Seven of the specimens presented bacterial organisms on the keratinized layer and eight of 10 contained mites on the surface of the tumors (Fig. 3).

The electron microscopic findings in two tumor specimens included multiple epidermal folds associated with dermal proliferation, and the epidermis was thicker than normal. Dermal papillae were projected towards the epidermis and the intercellular spaces were enlarged. Increased numbers of subcellular organelles, endoplasmic reticulum, and mitochondria and hypertrophy and hyperplasia of the stratum spinosum with pleomorphic cells also were identified. In both cases, granules with electron-dense bodies about 150 nm in diameter and similar in shape to viral particles, were observed in the more superficial cells of the epidermis.

#### DISCUSSION

The morphologic appearance of fibropapillomas in this study resembled that of previous reports (Jacobson et al., 1989; Bal-

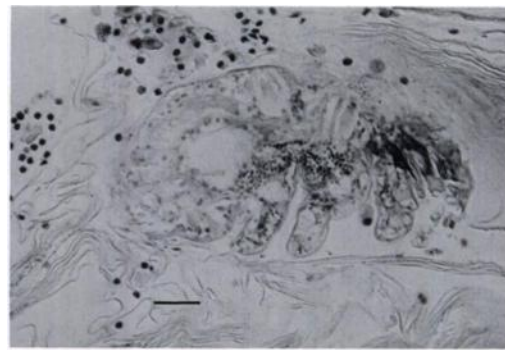


FIGURE 3. An unidentified mite (Acarina) and associated bacterial organisms within the epidermis keratinized layer of a green turtle fibropapilloma. H&E stain. Bar = 500  $\mu$ m.

azs and Pooley, 1991). Although GTFP has been reported in other organs such as kidneys (Norton et al., 1990), no specimens were available for necropsy during this study.

Our findings are consistent with Balazs (1991) report of a relationship between carapace length and the presence of fibropapillomas in green turtles. Furthermore, tumor severity apparently increases as turtles become larger (Balazs, 1991). This relationship may be explained by two hypotheses. Either turtles develop tumors after their recruitment to nearshore habitats from the pelagic environment or the incubation period of the disease agent is sufficiently long to extend through the oceanic phase which we speculate may range from 2 to 5 years, and then manifest itself at an age when nearshore recruitment occurs (Balazs, 1991).

Barnacles *C. testudinaria* are one of the three frequently encountered epizootic associates of sea turtles and apparently have little detrimental effect except in cases where incrustations on the head interfere with the action of eyelids (Lauckner, 1985). *Chelonibia testudinata* and *Platylepas hexastylus*, small barnacles of the soft skin surfaces, and *Stephanolepas muricata*, a burrowing barnacle of the plastron, carapace, and leading edges of flippers, have not been associated with pathologic signs

in green turtles, and their role in the metabolic process is unknown (Balazs and Pooley, 1991).

Papillomaviruses cause fibropapillomas in other species (Sundberg and O'Banion, 1989). The viral particles are extremely difficult to observe by light or electron microscopy and have not been isolated in tissue culture (Mansell et al., 1989).

Although the cellulolytic intestinal microflora of green turtles has been described (Bjorndal, 1979; Fenchel et al., 1979), normal bacterial flora and their role and persistence have not been characterized. A wide range of bacteria, including *Acinetobacter* spp., *Citrobacter* spp., *Enterobacter* spp., *Pseudomonas aeruginosa*, *P. maltophilia*, *Staphylococcus epidermidis*, *Vibrio alginolyticus*, and *V. damsela*, consistently were isolated from both groups of turtles. These potentially pathogenic bacteria could act as opportunistic invaders of tissues damaged by trauma, and have been associated in farmed sea turtles with ulcerative shell disease, traumatic ulcerative dermatitis, necrotic dermatitis, ulcerative stomatitis, obstructive rhinitis, keratoconjunctivitis, septicemia, bronchopneumonia, and osteomyelitis (Lauckner, 1985; Glazebrook and Campbell, 1990a).

*Citrobacter freundii* causes septicemic cutaneous ulcerative disease in other turtle species (Cooper and Jackson, 1981), and was isolated from 28% of the sea turtles sampled in our study. Coliforms and *Enterobacter* spp. have been incriminated in local and generalized disease in terrestrial reptiles (Hoff et al., 1984; Glazebrook and Campbell, 1990a).

Valvular endocarditis and septicemia were caused by *Vibrio damsela* in a stranded adult leatherback turtle (*Dermochelys coriacea*) (Obendorf et al., 1987). It is a known pathogen of fish, sharks, and humans and has been isolated from ulcerative skin lesions of damselfish (*Chromis punctinnis*).

*Klebsiella oxytoca*, *Pseudomonas stutzeri*, and *Hafnia alvei* were isolated from turtles afflicted with GTFP. These bacte-

rial species are distributed in aquatic environments and are commonly isolated from the oral cavity of terrestrial reptiles as saprophytes or commensals (Frye, 1991). *Hafnia alvei* has been isolated from animal clinical specimens and the environment (Carter and Chengappa, 1991). Their pathogenic significance is unknown.

Bacteria may act as secondary invaders of skin lesions produced by a herpesvirus. Gram-positive coccoids and Gram-negative rods were observed in the upper portion of the keratin layer in skin areas of green turtles affected with grey-patch disease (Lauckner, 1985). During our study, three of 11 turtles had epithelial necrosis associated with the presence of bacteria and fungi in the keratin layer.

Saprophytic bacteria including *Bacillus* spp., *Micrococcus* spp., and *Proteus* (*Providencia*) spp. are considered part of the normal skin flora of sea turtles (Glazebrook and Campbell, 1990a). Chlamydial infections in reptiles were unknown until recently (Frye, 1991).

The histologic characterization of normal green turtle skin and the cutaneous lesions identified as fibropapillomas have been previously described by Jacobson et al. (1989) and Jacobson (1991). The intranuclear bodies observed in the epithelial cells of several tumors appeared to be large nucleoli, and were compatible with intranuclear basophilic inclusion bodies described for papillomavirus (Sundberg and O'Banion, 1989; Jacobson, 1991). Viral particles, however, could not be observed under light or electron microscopy.

The electron microscopic findings of two turtle specimens were similar to the molecular examination of fibropapillomas reported by Jacobson et al. (1989). The most relevant finding in the specimens examined was the appearance of virus-like structures. These structures were found in both normal and diseased skin from green turtles and, although they had superficial characteristics of a herpesvirus, were part of the normal keratinization process of the skin. Intranuclear inclusions compatible



with a herpesvirus were reported in green turtles from Florida (Jacobson et al., 1991).

Mites (Acarina) (Glazebrook and Campbell, 1990a) and unidentified black "mites" (Balazs, 1985) have been reported embedded in the skin of green turtles. Eight of ten tumor biopsies we collected contained mites on the surface. The parasites identified in these turtles previously have been reported in green and other species of sea turtles, but most workers concentrated on taxonomic description with little or no information on infestation levels and associated clinical and pathologic signs (Lauckner, 1985; Glazebrook and Campbell, 1990b). Foreign organic materials (leeches, barnacles, algae) and digenetic trematodes also have been suggested as possible etiologic agents of GTFP in green turtles (Smith and Coates, 1939; Nigrelli and Smith, 1943; Dailey, 1991).

The taxonomy, biology, and life cycles of epizootic algae, barnacles, and ectoparasites and their role in GTFP need to be elucidated. Histopathologic, bacteriologic, virologic, parasitologic, and toxicologic studies would provide temporal trends and other epidemiologic features giving a better understanding of the natural history and etiology of GTFP.

#### ACKNOWLEDGMENTS

We deeply appreciate the support provided by C. Lannan, R. E. Lee, and R. G. McLean in this project and their insightful information related to virus isolation and identification attempts. We also gratefully acknowledge the assistance of R. Morris, Makai Animal Clinic, Kailua, Hawaii. This research was sponsored in part under contract No. 40-JJNF-1-0175 from the National Marine Fisheries Service SWFSC, Honolulu, Hawaii.

#### LITERATURE CITED

- AGUIRRE, A. A. 1991. Green turtle fibropapilloma: An epidemiologic perspective. *In* Research plan for marine turtle fibropapilloma, G. H. Balazs and S. G. Pooley (eds.). NOAA Technical Memorandum NMFS-SWFSC-156, U.S. Department of Commerce, Honolulu, Hawaii, pp. 107-113.
- BALAZS, G. H. 1985. Status and ecology of marine turtles at Johnston Atoll. *Atoll Research Bulletin* No. 285. The Smithsonian Institution, Washington, D.C., pp. 1-46.
- . 1991. Current status of fibropapillomas in the Hawaiian green turtle, *Chelonia mydas*. *In* Research plan for marine turtle fibropapilloma, G. H. Balazs and S. G. Pooley (eds.). NOAA Technical Memorandum NMFS-SWFSC-156, U.S. Department of Commerce, Honolulu, Hawaii, pp. 47-57.
- , AND S. G. POOLEY (editors). 1991. Research plan for marine turtle fibropapilloma. NOAA Technical Memorandum NMFS-SWFSC-156, U.S. Department of Commerce, Honolulu, Hawaii, 113 pp.
- , R. G. FORSYTH, AND A. K. H. KAM. 1987. Preliminary assessment of habitat utilization by Hawaiian green turtles in their resident foraging pastures. NOAA Technical Memorandum NMFS, NOAA-TM-NMFS-SWFC-71, U.S. Department of Commerce, Honolulu, Hawaii, 107 pp.
- BALOWS, A., AND W. J. HAUSLER, JR. (editors). 1981. Diagnostic procedures for bacterial, mycotic and parasitic infections, 6th ed. American Public Health Association. Washington, D.C., 1236 pp.
- BJORNDAAL, K. A. 1979. Cellulose digestion and volatile fatty acid production in the green turtle *Chelonia mydas*. *Comparative Biochemistry and Physiology* 63: 127-133.
- CARTER, G. R., AND M. M. CHENGAPPA. 1991. Essentials of veterinary bacteriology and mycology, 4th ed. Lea & Febiger, Philadelphia, Pennsylvania, p. 151.
- COOPER J. E., AND O. F. JACKSON (editors). 1981. Diseases of the Reptilia, Vol. 1. Academic Press, New York, New York, pp. 165-175.
- DAILEY, M. D. 1991. Background presentation on cardiovascular parasitism in Hawaiian green turtles and their possible role as potential etiologic agents of fibropapilloma disease. *In* Research plan for marine turtle fibropapilloma, G. H. Balazs and S. G. Pooley (eds.). NOAA Technical Memorandum NMFS-SWFSC-156, U.S. Department of Commerce, Honolulu, Hawaii, pp. 83-85.
- FENCHEL, T. M., C. P. MCROY, J. C. OGDEN, P. PARKER, AND W. E. RAINEY. 1979. Symbiotic cellulose degradation in green turtles, *Chelonia mydas* L. *Applied and Environmental Microbiology* 37: 348-350.
- FRYE, F. L. 1991. Biomedical and surgical aspects of captive reptile husbandry, Vol. 1, 2nd ed. Krieger Publishing Company, Malabar, Florida, pp. 136, 212-213.
- GLAZEBROOK, J. S., AND R. S. F. CAMPBELL. 1990a. A survey of the diseases of marine turtles in northern Australia. I. Farmed turtles. *Diseases of Aquatic Organisms* 9: 83-95.
- , AND ———. 1990b. A survey of the diseases of marine turtles in northern Australia. II. Oceanarium-reared and wild turtles. *Diseases of Aquatic Organisms* 9: 97-104.



- HAYAT, M. A. 1986. Basic techniques for transmission electron microscopy. Academic Press, Orlando, Florida, pp. 226–227.
- HOFF, G. L., F. L. FRYE, AND E. R. JACOBSON. 1984. Diseases of amphibians and reptiles. Plenum Press, New York, New York, pp. 37–39.
- JACOBSON, E. R. 1991. An update on green turtle fibropapilloma. In Research plan for marine turtle fibropapilloma. G. H. Balazs and S. G. Pooley (eds.). NOAA Technical Memorandum NMFS-SWFSC-156, U.S. Department of Commerce, Honolulu, Hawaii, pp. 71–73.
- , J. L. MANSELL, J. P. SUNDBERG, L. HAJJAR, M. E. REICHMANN, L. M. EHRHART, M. WALSH, AND F. MURRU. 1989. Cutaneous fibropapillomas of green turtles (*Chelonia mydas*). Journal of Comparative Pathology 101: 39–52.
- , C. BUERGELT, B. WILLIAMS, AND R. K. HARRIS. 1991. Herpesvirus in cutaneous fibropapillomas of the green turtle *Chelonia mydas*. Diseases of Aquatic Organisms 12: 1–6.
- LAUCKNER, G. 1985. Diseases of Reptilia. In Diseases of marine animals, Vol. IV, part 2, O. Kinne (ed.). Biologische Anstalt Helgoland, Hamburg, Germany, pp. 561–566.
- MANSELL, J. L., E. R. JACOBSON, AND J. M. GASKIN. 1989. Initiation and ultrastructure of a reptilian fibroblast cell line obtained from cutaneous fibropapillomas of the green turtle, *Chelonia mydas*. In Vitro Cellular and Developmental Biology 25: 1062–1064.
- MCDOWELL, E. M. 1978. Fixation and processing. In Techniques and applications in diagnostic electron microscopy, Vol. 1, B. Trump and R. Jones (eds.). John Wiley & Sons, New York, New York, pp. 117–122.
- NIGRELLI, R. F., AND G. M. SMITH. 1943. The occurrence of leeches, *Ozobranchus branchiatus* (Menzies), on fibro-epithelial tumors of marine turtles, *Chelonia mydas* (Linnaeus). Zoologica (New York) 28: 107–108.
- NORTON, T. M., E. R. JACOBSON, AND J. P. SUNDBERG. 1990. Cutaneous fibropapillomas and renal myxofibroma in a green turtle, *Chelonia mydas*. Journal of Wildlife Diseases 26: 265–270.
- OBENDORF, D. L., J. CARSON, AND T. J. MCMAHUS. 1987. *Vibrio damsela* infection in a stranded leatherback turtle (*Dermochelys coriacea*). Journal of Wildlife Diseases 23: 666–668.
- SCHLOTZHAUER, S. D., AND R. C. LITTELL. 1991. SAS system for elementary statistical analysis. SAS Institute, Inc., Cary, North Carolina, 416 pp.
- SMITH, G. M., AND C. W. COATES. 1939. The occurrence of trematode ova, *Haplotrema constrictum* (Leared), in fibro-epithelial tumors of the marine turtle, *Chelonia mydas* (Linnaeus). Zoologica (New York) 24: 379–382.
- SPENCER, W. N., AND F. W. A. JOHNSON. 1983. A simple transport media for the isolation of *Chlamydia psittaci* from clinical material. The Veterinary Record 113: 535–536.
- SUNDBERG, J. P., AND M. K. O'BANION. 1989. Animal papillomaviruses associated with malignant tumors. Advances in Viral Oncology 8: 55–71.

Received for publication 20 January 1993.