

## **Detection of Canine Distemper Viral Antigen in Foxes (*Vulpes vulpes*) in Northwestern Spain**

Authors: López-Peña, M., Quiroga, M. I., Vázquez, S., and Nieto, J. M.

Source: Journal of Wildlife Diseases, 30(1) : 95-98

Published By: Wildlife Disease Association

URL: <https://doi.org/10.7589/0090-3558-30.1.95>

---

BioOne Complete ([complete.BioOne.org](https://complete.BioOne.org)) is a full-text database of 200 subscribed and open-access titles in the biological, ecological, and environmental sciences published by nonprofit societies, associations, museums, institutions, and presses.

Your use of this PDF, the BioOne Complete website, and all posted and associated content indicates your acceptance of BioOne's Terms of Use, available at [www.bioone.org/terms-of-use](https://www.bioone.org/terms-of-use).

Usage of BioOne Complete content is strictly limited to personal, educational, and non - commercial use. Commercial inquiries or rights and permissions requests should be directed to the individual publisher as copyright holder.

---

BioOne sees sustainable scholarly publishing as an inherently collaborative enterprise connecting authors, nonprofit publishers, academic institutions, research libraries, and research funders in the common goal of maximizing access to critical research.

## Detection of Canine Distemper Viral Antigen in Foxes (*Vulpes vulpes*) in Northwestern Spain

M. López-Peña, M. I. Quiroga, S. Vázquez, and J. M. Nieto, Department of Pathology, Veterinary School, E27002-Lugo, Spain

**ABSTRACT:** We describe the lesions of natural distemper in red foxes (*Vulpes vulpes*) in Spain. The avidin-biotin-peroxidase complex (ABC) technique and a monoclonal antibody against the nucleocapsid protein of canine distemper virus were successfully used to confirm canine distemper diagnosis.

**Key words:** Canine distemper, red foxes, *Vulpes vulpes*, Spain, immunoperoxidase diagnosis.

Canine distemper virus (CDV) is one of the most important pathogens of carnivores. Following the infection, a systemic illness often develops, followed by neurological disease (Appel, 1987). Post-mortem diagnosis of canine distemper (CD) is based on typical gross and microscopic lesions, virus isolation in cell cultures (Appel, 1987) or in immunolabelling of viral antigens by means of immunofluorescence or immunohistochemistry (Ducatelle et al., 1980; Miry et al., 1983; Hewicker et al., 1990).

In Spain, canine distemper is frequently identified as a cause of death or disease in dogs (Nieto et al., 1987), ferrets (*Mustela putorius*), and mink (*Mustela vison*) (Nieto et al., 1992). Moreover, recently a morbillivirus resembling CDV and phocine morbillivirus have been identified in striped dolphins (*Stenella coeruleoalba*) which have died along the Spanish Mediterranean coast (Domingo et al., 1990, 1992).

Our objective was to report detection of CDV antigen in one wild and six captive red foxes (*Vulpes vulpes*) in Galicia, northwestern Spain (43°22'N, 8°23'W), using a monoclonal antibody against the viral nucleocapsid, and the avidin-biotin-peroxidase complex (ABC) technique. This is the first time immunohistochemistry has been used to demonstrate CDV antigen in tis-

sues of red foxes. There are no previous reports of canine distemper in red foxes in Spain. Foxes were received at the Department of Animal Pathology of the Veterinary Faculty of Lugo, Spain, in October 1989 (captive foxes) and in November 1989 (wild fox) with histories of respiratory distress; the ages of the animals were not determined.

Samples of brain, trachea, lung, third eyelid, kidney, urinary bladder, spleen, lymph nodes, small and large intestine, and stomach were taken at the necropsy, fixed in 10% buffered formalin and embedded in paraffin. Three  $\mu$ m sections were stained with hematoxylin and eosin for histopathology. Immunolabeling of CDV in sections was made by means of ABC technique (Hsu et al., 1981) using a monoclonal antibody against the nucleocapsid of CDV as the primary antibody; it was supplied by Dr. C. Örvell, National Bacteriological Laboratory and Karolinska Institute, Stockholm, Sweden. As positive controls we used sections of a dog with canine distemper; as negative controls we employed sections of a red fox with no clinical signs of disease.

On post-mortem examination, the foxes had collapsed lungs and an enlargement of the pulmonary lymph nodes. Mucopurulent discharge in the conjunctiva and hyperkeratosis of the foot pads also were present. Four captive foxes and the wild fox had exudative fibrinous pneumonia of varying severity. Interstitial pneumonia with infiltration of mononuclear cells into the interalveolar septae and macrophages, lymphocytes and desquamated alveolar cells filling alveoli were observed. Hyperplasia of alveolar epithelium and hyaline membranes in the lumina also were observed. Peribronchial, peribronchiolar and

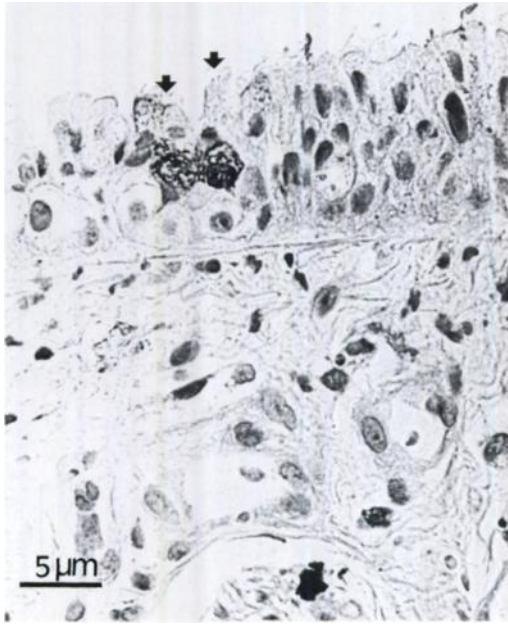


FIGURE 1. Canine distemper viral antigen in bronchiolar epithelial cells (arrows) of a fox. Anti-canine distemper virus-indirect avidin-biotin peroxidase complex.

perivascular mononuclear infiltrates were common findings in all cases.

Eosinophilic intracytoplasmic inclusion bodies (IB) were found in epithelial cells of the trachea, bronchi, and bronchioles, as well as in macrophages of the exudate in four animals. The size and amount of the IB were variable. A refringent area around inclusions was easily identified. The dominant lesion in the brain of all animals was demyelinating encephalitis, especially around the fourth ventricle. Meningeal vessels were congested but perivascular cuffing was not found. Lymphocyte depletion was seen in the spleen and lymph nodes.

Viral IB also were found in circulating macrophages (one animal), urinary bladder epithelium (two foxes), renal pelvic epithelium (two foxes), epithelia of the tubular system in kidney (one fox), and in epithelial cells of the biliary ducts (two foxes).

Peroxidase-positive material was brown, diffuse and mainly in the cytoplasm,

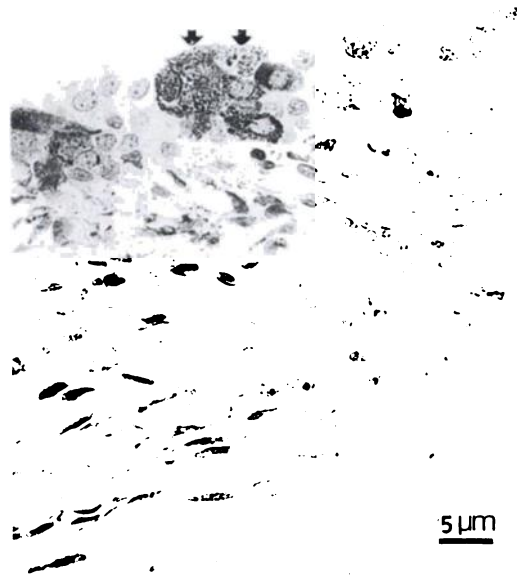


FIGURE 2. Peroxidase-positive material in epithelial cells of the kidney pelvis (arrows) of a fox. Anti-canine distemper virus-avidin biotin peroxidase complex.

whereas a few cells had the same pattern in the nuclei. Dark brown granules were found in the cytoplasm of cells where we identified IB.

Canine distemper viral antigen-positive material was observed by immunohistochemistry in several locations, mainly in epithelial cells of the respiratory system (seven foxes) (Fig. 1). In addition to labeling cells with IB, CDV antigen was identified in bronchial gland cells (three foxes), ependymal cells (four foxes), glial cells (two foxes), endothelial cells (five foxes), kidney pelvis (five foxes) (Fig. 2), epithelial cells of the stomach and intestine (six foxes) (Fig. 3), mesangial cells of glomeruli (one fox), epithelial cells of the third eyelid (four foxes), some hepatocytes (one fox), and circulating macrophages (two foxes).

Canine distemper frequently has been reported in free and captive carnivores (Budd, 1981). Distemper in *Vulpes vulpes* was first demonstrated by Green (1926, cited by Appel and Gillespie, 1972), and later reported by several authors (Rudolf,

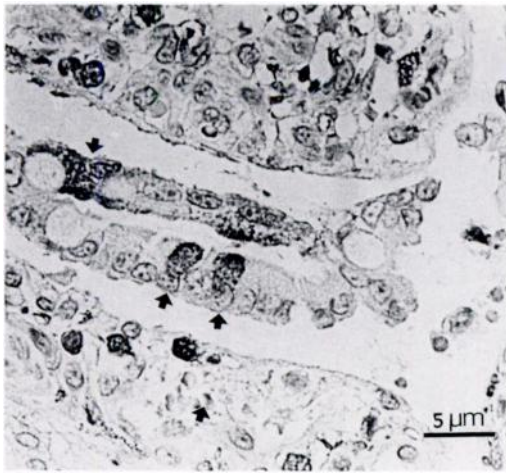

FIGURE 3. Canine distemper viral antigen in infected cells of the small intestine (arrows) of a fox. Anti-canine distemper virus-indirect avidin-biotin peroxidase complex.

1930; Dedié et al., 1957; cited by Appel and Gillespie, 1972). There are several reports of the infection in gray foxes (*Urocyon cinereoargenteus*) in North America (Hoff et al., 1974).

Microscopic lesions of CD are similar in all species affected (Appel, 1987). In our study, the interstitial pneumonia, demyelinating encephalitis, and identification of IB in epithelial cells and in macrophages were in accordance with several other descriptions of CD infection in other species such as dogs (Appel and Gillespie, 1972; Appel et al., 1981), mink (Nieto et al., 1992), and ferrets (Dunkin and Laidlaw, 1926; Hewicker et al., 1990). Perivascular cuffing in the brain was not identified in our cases.

Identification of IB is important for a diagnosis of CD but they are not pathognomonic. Since the publications of Ducatelle et al. (1980) and Miry et al. (1983), use of immunolabeling of CD antigens in paraffin section has been one of the most useful methods for definitive diagnosis (Hewicker et al., 1990). Canine distemper antigen was recognized in our foxes in several tissues. The respiratory system and the digestive epithelium proved to be the most favorable site of detection of CDV antigen.

The identification of CDV antigen in blood cells demonstrated viremia. The results of immunolabeling in red foxes were similar to those described in other species such as dogs (Appel, 1969; Ducatelle et al., 1980) or ferrets (Liu and Coffin, 1957).

This work was supported by XUNTA DE GALICIA (XUGA 26103B90).

#### LITERATURE CITED

- APPEL, M. J. G. 1969. Pathogenesis of canine distemper. *American Journal of Veterinary Research* 30: 1167-1182.
- . 1987. Canine distemper virus. In *Virus infections of carnivores*, M. J. Appel (ed.). Elsevier Science Publishers B. V., Amsterdam, Holland, pp. 133-159.
- , AND J. H. GILLESPIE. 1972. Canine distemper virus. *Virology Monographs*. Number 11. Springer Verlag, Vienna, Austria, pp. 3-96.
- , E. P. J. GIBBS, S. J. MARTIN, V. TER MEULEN, B. K. RIMA, J. R. STEPHENSON, AND W. P. TAYLOR. 1981. Morbillivirus disease of animals and man. In *Comparative diagnosis of viral diseases*, Number 11, E. Kurstak and C. Kurstak (eds.). Academic Press, New York, New York, pp. 235-297.
- BUDD, J. 1981. Distemper. In *Infectious diseases of wild mammals*, J. W. Davis, L. H. Karstad, and D. O. Trainer (eds.). The Iowa State University Press, Ames, Iowa, pp. 31-44.
- DOMINGO, M., L. FERRER, M. PUMAROLA, A. MARCO, J. PLANA, S. KENNEDY, M. MCALISKEY, AND B. K. RIMA. 1990. Morbillivirus in dolphins. *Nature* 348: 21.
- , J. VISA, M. PUMAROLA, A. J. MARCO, L. FERRER, R. RABANAL, AND S. KENNEDY. 1992. Pathologic and immunocytochemical studies of *Morbillivirus* infection in striped dolphins (*Stenella coeruleoalba*). *Veterinary Pathology* 29: 1-10.
- DUCATELLE, R. W., W. COUSSEMENT, AND J. HOORENS. 1980. Demonstration of canine distemper virus in paraffin sections, using an unlabelled antibody-enzyme method. *American Journal of Veterinary Research* 41: 1860-1862.
- DUNKIN, G. W., AND P. P. LAIDLAW. 1926. Studies in dog distemper: I. Dog distemper in the ferret. *Journal of Comparative Pathology Therapeutics* 39: 201-212.
- HEWICKER, M., S. DAMSCH, AND G. TRAUTWEIN. 1990. Detection of canine distemper viral antigen in formalin-fixed and paraffin-embedded tissue of a fitch (*Mustela putorius*), using an immunoperoxidase technique. *Deutsche Tierärztliche Wochenschrift* 97: 85-87.
- HOFF, G. L., W. J. BIGLER, S. J. PROCTOR, AND L. P. STALLINGS. 1974. Epizootic of canine distemper virus infection among urban raccoons

- and gray foxes. *Journal of Wildlife Diseases* 10: 423-428.
- HSU, S.-M., L. RAINE, AND H. FANGER. 1981. Use of avidin-biotin-peroxidase complex (ABC) in immunoperoxidase technique: A comparison between ABC and unlabeled antibody (PAP) procedures. *Journal of Histochemistry and Cytochemistry* 30: 1079-1086.
- LIU, C., AND D. L. COFFIN. 1957. Studies on canine distemper infection by means of fluorescein-labeled antibody. I. The pathogenesis, pathology and diagnosis of the disease in experimentally infected ferrets. *Virology* 3: 115-131.
- MIRY, C., R. DUCATELLE, H. THOONEN, AND J. HOORENS. 1983. Immunoperoxidase study of canine distemper virus pneumonia. *Research in Veterinary Science* 34: 145-148.
- NIETO, J. M., A. RUEDA, E. TORTUERO, AND M. PIZARRO. 1987. Aportaciones al diagnóstico del moquillo canino mediante demostración citológica del antígeno viral por medios histológicos e inmunohistoquímicos. *Medicina Veterinaria* 4: 29-33.
- , M. QUIROGA, M. LÓPEZ, AND R. F. ANTONIO. 1992. Distemper in mink in the NW of Spain. *Norwegian Journal of Agricultural Science Supplement* 9: 398-404.

*Received for publication 21 April 1993.*