

## **DIAGNOSTIC CRITERIA FOR SELENIUM TOXICOSIS IN AQUATIC BIRDS: DIETARY EXPOSURE, TISSUE CONCENTRATIONS, AND MACROSCOPIC EFFECTS**

Authors: Albers, Peter H., Green, D. Earl, and Sanderson, Caroline J.

Source: Journal of Wildlife Diseases, 32(3) : 468-485

Published By: Wildlife Disease Association

URL: <https://doi.org/10.7589/0090-3558-32.3.468>

---

BioOne Complete ([complete.BioOne.org](https://complete.BioOne.org)) is a full-text database of 200 subscribed and open-access titles in the biological, ecological, and environmental sciences published by nonprofit societies, associations, museums, institutions, and presses.

Your use of this PDF, the BioOne Complete website, and all posted and associated content indicates your acceptance of BioOne's Terms of Use, available at [www.bioone.org/terms-of-use](https://www.bioone.org/terms-of-use).

Usage of BioOne Complete content is strictly limited to personal, educational, and non - commercial use. Commercial inquiries or rights and permissions requests should be directed to the individual publisher as copyright holder.

---

BioOne sees sustainable scholarly publishing as an inherently collaborative enterprise connecting authors, nonprofit publishers, academic institutions, research libraries, and research funders in the common goal of maximizing access to critical research.

## DIAGNOSTIC CRITERIA FOR SELENIUM TOXICOSIS IN AQUATIC BIRDS: DIETARY EXPOSURE, TISSUE CONCENTRATIONS, AND MACROSCOPIC EFFECTS

Peter H. Albers,<sup>1</sup> D. Earl Green,<sup>2</sup> and Caroline J. Sanderson<sup>1,3</sup>

<sup>1</sup> National Biological Service, Patuxent Environmental Science Center, Stickel Laboratory, Environmental Contaminants Research, 12011 Beech Forest Road, Laurel, Maryland 20708-4041 USA

<sup>2</sup> State of Maryland, Department of Agriculture, Animal Health/Diagnostic Laboratory, 8077 Greenmead Drive, College Park, Maryland 20740 USA

<sup>3</sup> Present address: Mason Neck National Wildlife Refuge, 14344 Jefferson Davis Highway, Woodbridge, Virginia 22191-2890 USA

**ABSTRACT:** A feeding study with mallard ducks (*Anas platyrhynchos*) was conducted during March to July 1988 in Laurel, Maryland (USA), to identify diagnostic criteria for selenium toxicosis in birds. One-year-old male mallards in groups of 21 were fed diets containing 0, 10, 20, 40, or 80 parts per million (ppm) selenium, as seleno-DL-methionine, for 16 weeks. All ducks receiving 80 ppm died. Ducks receiving 40 or 80 ppm selenium consumed less feed than ducks in the other treatment groups. Body weights of ducks receiving 40 or 80 ppm selenium declined during the study. The post-breeding molt was delayed in ducks receiving 40 ppm; most ducks receiving 80 ppm selenium died prior to the onset of molt. At necropsy, numerous abnormalities were observed in ducks that died but only a small number of abnormalities were observed in ducks surviving to the end of the study in the 40 ppm group. Weights of the heart, spleen, and pancreas were mostly lower and weights of the kidney were higher for ducks dying during the study than for euthanized ducks. Liver weights were unaffected. Selenium accumulated in soft tissues approximately in proportion to dietary concentrations. Selenium concentrations in tissues of all ducks that died were different from those of surviving ducks in the 0, 10, and 20 ppm groups, but were not different from those of surviving ducks in the 40 ppm group. Proposed diagnostic criteria for fatal chronic selenosis were derived from body weight, macroscopic abnormalities, organ weights, and concentrations of selenium in the liver. Proposed diagnostic criteria for non-fatal chronic selenosis were derived from body weight, plumage condition, macroscopic abnormalities, concentrations of selenium in the liver, reproductive failure, and alterations of blood and tissue chemistries. Lead or dioxin poisoning have diagnostic criteria most similar to selenium toxicosis.

**Key words:** Selenium, feeding study, mallard (*Anas platyrhynchos*), diagnostic criteria, selenium toxicosis, liver disease, emaciation, feather abnormalities.

### INTRODUCTION

Selenium (Se) is a trace element essential for animal nutrition. Insufficient or excessive amounts of this metalloid in the diet can cause serious health problems for invertebrates and vertebrates (Eisler, 1985; Ohlendorf, 1989). Regions with high concentrations of Se in the soil, neutral to high soil pH, and high moisture have the greatest potential for Se toxicity (Eisler, 1985; Burau, 1989). Much of the arid western United States is characterized by seleniferous soils and high soil pH; some areas have a history of Se poisoning of livestock caused by consumption of highly seleniferous forage (Rosenfeld and Beath, 1964; National Academy of Sciences,

1976; National Research Council, 1983). Selenium is well known for its adverse effects on reproduction in domestic fowl (National Academy of Sciences, 1976; Eisler, 1985). Reproductive effects also have been demonstrated for game farm mallard ducks (*Anas platyrhynchos*) (Hoffman and Heinz, 1988; Heinz et al., 1989). For the past decade, public attention has been focused on the Central Valley of California (USA) where high concentrations of Se in irrigation drainwater and aquatic plants, invertebrates, and fish have adversely affected the health and reproduction of aquatic birds (Presser and Ohlendorf, 1987; Ohlendorf, 1989). Sites in western states of the USA likely to have irrigation-related drainwater problems have concen-

trations of Se in biota exceeding toxicity thresholds for fish and wildlife in California, Colorado, Kansas, Montana, Nevada, Oregon, South Dakota, Utah, and Wyoming and deformities in bird embryos in California, Montana, Nevada, Utah, and Wyoming (Presser et al., 1994).

Although the macro- and microscopic effects of Se on physiological systems and individual organs of domestic animals, particularly mammals, have been established, the pathological effects of Se toxicity in wild animals are not well known (National Academy of Sciences, 1976; National Research Council, 1983; Eisler, 1985). The most detailed evaluation of Se toxicosis in wild birds was performed on American coots (*Fulica americana*) and a few pied-billed grebes (*Podilymbus podiceps*) from the Kesterson National Wildlife Refuge in California (Ohlendorf et al., 1988). Adult birds found dead or collected from Kesterson were emaciated and had breast muscle atrophy, absence of body fat, and fluid in lungs; most birds also had excess gelatinous or serous fluid in the body cavity or subcutaneously. Some birds also had pale swollen livers, flaccid heart, congested and enlarged spleens, and feather loss on the head. Based on histopathological examination of tissues, there were pectoral muscle abnormalities, presumably related to the muscle atrophy, and several liver abnormalities. Body weight was inversely related to Se concentrations in the liver and kidney (Ohlendorf et al., 1988). Adult and young mallards fed dietary Se had emaciation, liver damage, flaccid heart, and excess fluid around some internal organs (Hoffman et al., 1991a; Heinz, 1993; Heinz and Fitzgerald, 1993a). Dietary Se also produced abnormalities in blood chemistries with indications of liver toxicity in mallard adults and ducklings (Hoffman et al., 1989, 1991a).

Diagnostic criteria for Se toxicosis are needed to determine if Se is responsible for the death, impaired reproduction, or poor body condition of aquatic birds in seleniferous areas (Ohlendorf, 1989). Exper-

iments designed to identify, as thoroughly as possible, the pathological effects on birds of ingested Se are necessary because many of the effects previously reported are not specific for Se (Wobeser, 1981). Also, the potential variability of species responses to Se challenge means that a combination of indicators will be necessary. Diagnostic criteria should be developed from clinical signs, macroscopic abnormalities, histological lesions, Se concentrations in tissues, blood and biochemical measures, and behavioral changes.

Our objective was to determine the relations between high dietary concentrations of organic Se, similar to those occurring in seleniferous areas, and physiological and behavioral functions of adult mallard ducks, and then use these findings to establish criteria for diagnosing Se toxicosis in aquatic birds.

#### MATERIALS AND METHODS

One-year-old male mallards were quarantined for 2 wk in partially enclosed, wooden buildings with concrete floors at the Patuxent Environmental Science Center, Laurel, Maryland USA (39°00'N, 76°45'W). The ducks then were banded with numbered leg bands and randomly assigned, in groups of three, to elevated outdoor pens. The pens measured approximately 1 × 1 × 0.7 m and were constructed of vinyl-coated wire and covered by a fiberglass roof. Each pen contained a large plastic food container and a large stainless steel pan to receive flowing water. Seven randomly selected pens (21 birds) were assigned to each of five experimental groups. After 4 days of acclimation to the elevated pens, the ducks were started on diets containing 0, 10, 20, 40, or 80 parts per million (ppm) (wet weight) Se in the form of seleno-DL-methionine (SeM) (98+% pure; Bachem, Inc., Torrance, California) in a mash diet. The initiation of treatments was phased in over a 4-day period (two, two, two, and one pen of ducks per experimental group per day). Seleno-DL-methionine was dissolved in distilled, deionized water. The treated water was mixed into duck developer mash (Beacon Feeds, Cayuga, New York, USA) so that 2% water had been added to the feed. Based on information provided on the feed company label, the developer mash had been supplemented with 0.1 ppm (wet weight) Se as sodium selenite, and contained 14.5% crude protein, 2.7% crude fat,

7% crude fiber, and about 10.5% water. Three samples of the untreated and treated diets were analyzed for Se content (Krynitsky, 1987); the developer mash also was analyzed for methionine (Association of Official Analytical Chemists, 1990) and vitamin E (Cort et al., 1983).

Ducks were fed treated diets for 16 wk (late March to mid-July 1988). Feed consumption was measured on days 1, 2, 3, 5, 7, 9, 12, and 15 by determining the amount of feed disappearing from the feed container in each pen. Rapid weight loss was expected for mallards receiving the high concentrations of SeM; consequently, we thought it most important to determine the role of food avoidance early in the study. All birds were weighed when the treatments began and at the end of weeks 1, 2, 3, 4, 5, 6, 8, 12, and 16. The pens were checked twice daily; dead birds were collected and the posture, alertness, and response of ducks to investigators during daily pen checks and a separate observation period was recorded. The post-breeding molt was evaluated on three occasions by classifying each surviving duck as either before molt, undergoing molt, or with completed molt (eclipse plumage). All dead birds were stored at 4 to 6 C. A necropsy was performed on dead birds within 24 hr of death.

After 16 wk on treatment, all surviving ducks were euthanized in an O<sub>2</sub>-CO<sub>2</sub> chamber built on site, and immediately necropsied; study termination was on the same staggered 4-day schedule as study initiation. Body weight and weights of liver, kidneys, heart, spleen, and testis were recorded. Pancreatic weights were determined after abnormalities were observed during necropsies of mallards that died. Fresh weights of formalin-fixed pancreases ( $n = 28$ ) were estimated by comparing the fresh and formalin-fixed weights of pancreases saved after the abnormalities were noticed ( $n = 13$ ). Ten to 20 ml of blood was removed from the heart of each euthanized duck for determination of packed cell volume (Thrall, 1985) and serological tests; antibodies against avian influenza viruses and Newcastle disease viruses were evaluated by hemagglutination-inhibition, and salmonellosis (pullorum-typhoid) by plate agglutination (Beard, 1980). Feces from the cecum, colon, or cloaca were collected for parasite examinations by the simple sugar flotation method (Wade and Gaafar, 1985). Portions of the liver, kidney, lung, and trachea of the ducks in each pen were pooled and frozen; two pooled tissue samples from each experimental group were selected at random for virus cultures in chicken eggs by inoculation of allantoic sacs (Hitchner, 1980). Cultures for the isolation of *Campylobacter* spp. and *Salmonella* spp. bacteria were performed on lung, liver, kidney, and

intestines of randomly selected ducks from each experimental group; we used Mueller Hinton medium with 5% bovine blood and *Campylobacter*-selective supplement (Skirrow SR69) (Oxoid, Unipath Limited, Basingstoke, Hampshire, England) for *Campylobacter* spp. and MacConkey agar and selenite broth (Difco Laboratories, Detroit, Michigan, USA) for *Salmonella* spp. All laboratory tests and cultures were performed at the Animal Health Diagnostic Laboratories, Maryland Department of Agriculture, College Park, Maryland.

Portions of the liver, kidneys, spleen, brain, and heart were frozen prior to Se analysis. Tissues from all ducks that died, all ducks from the 40 ppm group, and a subset of 10 randomly selected ducks from each of the 0, 10, and 20 ppm groups also were analyzed for Se. Portions of brain, spinal cord, liver, pancreas, kidney, heart, spleen, adrenal, testis, breast muscle, cheek skin, toes, mandible, vertebrae, bone marrow, esophagus, ventriculus (gizzard), proventriculus, duodenum, ileum, cecum, colon, sublumbar lymph nodes, thyroid, thymus, bursa of Fabricius, jejunum, cloaca, brachial plexus, and eyelids were fixed by immersion in neutral buffered formalin for histological examinations; results of histological examinations will be reported separately. The necropsy procedure for ducks that died during the study was the same as for euthanized ducks, except that collection of blood and feces was not attempted. One week prior to the start of the feeding study, health assessment studies were performed on four randomly selected ducks; ducks were euthanized and necropsied according to the procedures used on experimental ducks. An additional six non-experimental ducks were killed during the course of the study to monitor background health and tissue and organ appearance. All laboratory tests for viruses, bacteria, and parasites were performed. In addition, direct fluorescent antibody tests (FAT) (Liu, 1969) for duck viral enteritis using conjugated antisera (US Department of Agriculture, National Veterinary Services Laboratory, Ames, Iowa, USA) were performed on cryostat-prepared sections of esophagus and liver from the four mallards evaluated prior to study initiation.

Selenium analyses were conducted according to the method of Krynitsky (1987). A 0.5-g wet weight subsample of homogenized feed or tissue was placed in a 50-ml disposable polyethylene conical tube and digested for 2 hr in a concentrated nitric acid and 30% hydrogen peroxide solution. The sample tubes were partly immersed in a hot water bath at 95 C. Selenium concentrations in the digested samples then were quantified directly, using peak area integration, by graphite furnace atomic absorp-

tion spectrometry, in combination with Zeeman background correction (Slavin et al., 1983). The lower limit of detection was 0.05  $\mu\text{g/g}$  for a 0.5-g subsample. The average recovery for tissue and NBS standard reference material spiked with inorganic Se was 98%.

The analyses for methionine and vitamin E were performed by Hazelton Laboratories America, Inc., Madison, Wisconsin. Methionine was analyzed according to the Association of Official Analytical Chemists (1990). Vitamin E was analyzed according to Cort et al. (1983).

All concentrations of Se in tissue are reported as dry weight unless specifically noted as wet weight. Concentrations of Se in feed for this and other cited studies are wet weight; duck developer mash contains 10 to 12% moisture. Conversions from the wet weight values of other reports to dry weight were based on an assumption of 70% moisture for liver and egg and 75% moisture for kidney. All chemical analyses were performed under the Quality Assurance Program (QAP) of the U.S. Fish and Wildlife Service. Analyses performed under the QAP incorporated the use of procedural blanks, duplicate analyses, spikes, and standard reference materials as indicators of accuracy and precision.

Fisher's exact test (Siegel, 1956) was used to compare the survival of mallards receiving 10 to 80 ppm Se to the survival of mallards receiving 0 ppm Se. A one-way analysis of variance (ANOVA) and Tukey's Honestly Significant Difference (HSD) test for pairwise comparisons (SAS Institute, 1988) were used to compare food consumption, body weight, organ weight, packed cell volume, and concentrations of Se in tissue among experimental groups. A Kolmogorov-Smirnov test (Siegel, 1956) was used to compare the plumage condition of mallards receiving 10 to 80 ppm Se to the plumage condition of mallards receiving 0 ppm Se. Fisher's exact test (Siegel, 1956) was used to compare the frequency of abnormalities in mallards receiving 10 to 80 ppm Se to the frequency of abnormalities in mallards receiving 0 ppm Se. Abnormalities in ducks that died during the study were evaluated separately from those observed after euthanasia. The alpha level was 0.05 for parametric and non-parametric tests. All statements about differences between groups of birds given in the results are in reference to statistically significant differences.

## RESULTS

Ten ducks euthanized prior to and during the study appeared healthy at necropsy, and no pathogens or titers were de-

TABLE 1. Survival of mallard ducks fed diets supplemented with 0, 10, 20, 40, or 80 ppm selenium, as seleno-DL-methionine, for 16 wk, late March to mid-July, 1988.

Group (ppm selenium)	Survived	Died
0	21	0
10	20	0 <sup>a</sup>
20	20	1
40	17	3 <sup>a</sup>
80 <sup>b</sup>	0	21

<sup>a</sup> One mallard was excluded because it died from bacterial infections before the end of the study.

<sup>b</sup> Different from the 0 ppm group, Fisher's exact test,  $P \leq 0.05$ .

tected in microbial cultures, FAT, parasite tests, and serologic tests. All ducks had multiple calluses on their feet, but no internal abnormalities.

Selenium, as seleno-DL-methionine in the diet caused a reduction (100%) in survival at 80 ppm and a non-significant reduction (15%) at 40 ppm (Table 1). Two ducks that died during the study, one each in the 10 and 40 ppm groups, had bacterial infections. Consequently, they were included in the feed consumption analysis but not in body weight or survival calculations. Four additional ducks which survived the 16-wk study had serious health problems at the time of euthanasia (polycystic kidney disease, severe hepatosplenomegaly, and two cases of foreign body gizzard abscesses). The diseases of these four ducks were considered unrelated to dietary Se, therefore, they were deleted from all analyses except feed consumption and survival. Feed consumption by all six ducks could not be separated from that of other ducks because consumption was measured on a pen basis, with three ducks per pen.

Feed consumption, on all of the measured days, was lower for some of the groups that received mash containing supplemental Se than for ducks receiving 0 ppm (Fig. 1). Ducks in the 0 and 10 ppm groups consumed more feed per day on all measured days than ducks in the 80 ppm

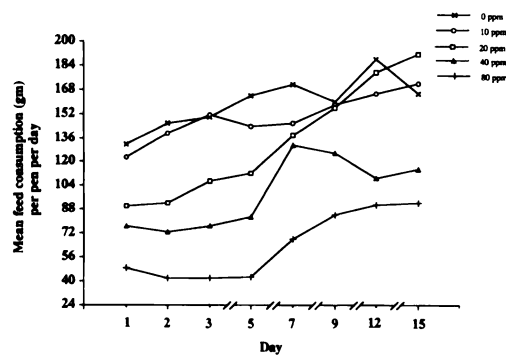


FIGURE 1. Feed consumption of mallard ducks during the first 15 days of a 16-wk, late March to mid-July, 1988, period of exposure to a mash diet supplemented with 0, 10, 20, 40, or 80 ppm selenium, as seleno-DL-methionine. Each value represents the mean of feed consumption in seven pens.

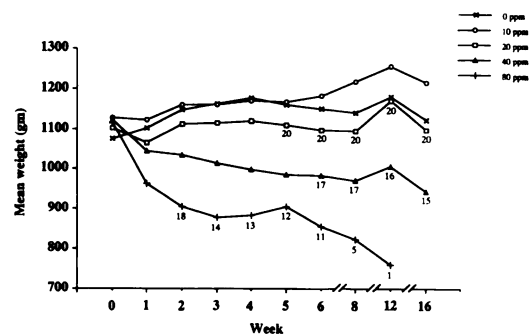


FIGURE 2. Mean body weight of mallard ducks fed a mash diet supplemented with 0, 10, 20, 40, or 80 ppm selenium, as seleno-DL-methionine, for 16 wk. Beginning sample sizes, minus six ducks deleted from the study because of serious health problems (two died), were 21 for 0, 20, and 80 ppm and 18 for 10 and 40 ppm. Changes in sample size caused by death are shown on the figure.

group. Ducks in the 20 ppm group consumed more feed per day from day 3 onward than ducks in the 80 ppm group. Feed consumption among the 0, 10, and 20 ppm groups was never different and at least one of these groups had higher feed consumption than the 40 ppm group on all measured days except days 7 and 9.

Mean body weight of ducks at the beginning of the study was not different among the experimental groups. However, mean body weight of some groups receiving mash containing supplemental Se was reduced throughout the 16-wk period (Fig. 2). Ducks in the 0, 10, and 20 ppm groups were heavier through week 12 than ducks in the 80 ppm group; all ducks in the 80 ppm group died before week 16. Ducks in the 40 ppm group were heavier than ducks in the 80 ppm group during weeks 1, 2, 3, and 6 of the study. Ducks in the 0 and 10 ppm groups were heavier than ducks in the 40 ppm group from week 2 onward. Ducks in the 20 ppm group were heavier than ducks in the 40 ppm from week 3 onward. Ducks in the 10 ppm group were heavier than ducks in the 20 ppm group during weeks 8 and 16 only.

The mean  $\pm$ SE body weight ( $636 \pm 11.6$  g) at death of ducks that died during the study (21 at 80 ppm, 3 at 40 ppm, and

1 at 20 ppm) was less than the mean body weights of euthanized ducks (week 16) in all the other groups. The mean body weight of ducks that died and the mean body weight of euthanized ducks in the 40 ppm group ( $944 \pm 40.1$  g) were 57% and 84%, respectively, of the mean body weight of euthanized ducks in the 0 ppm group ( $1122 \pm 26.6$  g). The mean body weight of euthanized ducks in the 20 ppm ( $1096 \pm 26.8$  g) and 10 ppm ( $1215 \pm 37.3$  g) groups were 98% and 108%, respectively, of the mean body weight of euthanized ducks in the 0 ppm group.

Ducks on the 40 and 80 ppm diets were anorexic, inattentive, lethargic, weak, and recumbent; all of which became progressively more severe as the study progressed. Simultaneously, feathers became dry, broken, and out of alignment on the body. Ducks receiving 40 ppm Se had retarded plumage change at both week 12 and at the termination of the study in mid-July (week 16) (Table 2). Ducks in the 80 ppm group died before the onset of post-breeding molt.

Mallards that died had an average of nine of the 13 listed abnormalities (Table 3); the range of abnormality frequency was six of 13 to 12 of 13. Three abnormalities were detected in euthanized mallards of

TABLE 2. The progression of post-breeding molt in surviving mallard ducks fed diet supplemented with 0, 10, 20, 40, or 80 ppm selenium, as seleno-DL-methionine, for 16 wk.

Week 7 (May 19)				Week 12 (June 21)				Week 16 (July 18–21)			
Group (ppm selenium)	Molt stage <sup>a</sup>			Group (ppm selenium)	Molt stage			Group (ppm selenium)	Molt stage		
	B	M	E		B	M	E		B	M	E
0	16	5	0	0	11	6	4	0	0	0	21
10	14	4	0	10	7	5	6	10	0	1	17
20	20	0	0	20	9	8	3	20	0	1	19
40	16	1	0	40 <sup>b</sup>	14	2	0	40 <sup>b</sup>	2	8	5
80	8	0	0	80	1	0	0	80	0	0	0

<sup>a</sup> B = before molt, M = during molt, E = molt complete (eclipse).<sup>b</sup> Different from the 0 ppm group, Kolmogorov-Smirnov test,  $P \leq 0.05$ .

the 40 ppm group (Table 4); muscle atrophy, sloughed or broken claws (onychop-tosis) (Fig. 3) and loss of feathers (deplum-ation) (Fig. 4a and 4b) occurred in the 40 ppm group. Packed cell volumes of eu-thanized ducks were not different among study groups and the 10 other ducks eu-thanized before and during the study.

Mean organ weights were lower for the heart, spleen, and pancreas of ducks dying during the study than for most of the groups of ducks that were euthanized after 16 wk (Table 5). Based on the paired com-parisons for the heart, lower weights oc-curred in the 40 ppm group than in the 10 ppm group. In addition, testis weights

TABLE 3. Macroscopic abnormalities detected during the necropsy of mallard ducks that died during the study. Only abnormalities with a frequency  $\geq 33\%$  and different ( $P \leq 0.05$ , Fisher's exact test) from that of euthanized ducks in the 0 ppm group are shown.

Abnormality	Died			0 ppm		
	Number of ducks	Frequency of detection	%	Number of ducks	Frequency of detection	%
Muscles: atrophy	25	25	100	21	0	0
Spleen: atrophy	25	23	92	21	0	0
Subcutaneous fat: absent	25	22	88	21	1	5
Thymus: absent	25	21	84	21	0	0
Liver: necrosis and, possibly, with prominent congested capsular ves-sels or reddish-black capsular hemorrhages	25	21	84	21	0	0
Feet & digits: enlarged foot pads, joint swellings, calluses	25	18	72	21	2	10
Pancreas: pallor and atrophy	25	18	72	21	0	0
Stomach & intestines: empty or nearly empty	25	17	68	21	0	0
Intestines and ceca: black (bloody) ingesta	25	15	60	21	0	0
Visceral fat: absent	25	15	60	21	0	0
Kidneys: enlarged	25	11	44	21	0	0
Gall bladder: enlarged with bile, $\geq 2$ ml	25	9	36	21	0	0
Mouth, pharynx, esophagus, proventriculus, gizzard, or duodenum: stained with bile	25	9	36	21	0	0

TABLE 4. Macroscopic abnormalities detected during the necropsy of mallard ducks that were euthanized at the end of the study. Only abnormalities with a frequency  $\geq 33\%$  and different ( $P \leq 0.05$ , Fisher's exact test) from that of ducks in the 0 ppm group are shown.

Abnormality	40 ppm			0 ppm		
	Number of ducks	Frequency of detection	%	Number of ducks	Frequency of detection	%
Muscles: atrophy	15	9	60	21	0	0
Claws: sloughed or broken at quick	15	8	53	21	3	14
Feathers: loss of feathers on head or neck	15	7	47	21	0	0

for ducks that died and ducks in the 40 ppm and 20 ppm groups were lower than for ducks in the 10 ppm group. Kidney weights were higher for ducks that died than for the groups of ducks that were euthanized. Liver weights were not different among groups.

Untreated developer mash contained an average of 0.6 ppm selenium on a wet-weight basis; three samples of each of the treated mash diets averaged 95% recovery of selenium. Methionine and vitamin E were found at 122% (2.87 g/kg) and 128% (20.5 IU/kg), respectively, of the supplement added by the feed company.

One spleen, one brain, and two kidney samples were lost in storage prior to analysis. Selenium accumulated in soft tissues (Table 6) approximately in proportion to dietary concentrations, except for the ducks that died before the end of the experiment; these were mostly 80 ppm ducks. Most of the ducks in the 80 ppm

group died during the first half of the study. Mean tissue concentrations, in descending order, were in liver, kidney, heart, brain, and spleen. Selenium concentrations in all tissues of ducks that died were different from those of the 0, 10, and 20 ppm groups but were not from those of the 40 ppm group. Selenium concentrations in the kidney and heart of ducks in the 40 ppm group were greater than Se concentrations in the 0, 10, and 20 ppm groups. Selenium concentrations in the liver and brain of ducks in the 40 ppm group were greater than Se concentrations in the 0 and 10 ppm groups. Selenium concen-



FIGURE 3. Mallard duck with sloughed or broken claws typical of eight of 15 ducks consuming diets supplemented with 40 ppm of selenium, as seleno-DL-methionine, for 16 wk.




FIGURE 4. Mallard duck with feather loss, (side and ventral views) typical of seven of 15 ducks consuming diets supplemented with 40 ppm of selenium, as seleno-DL-methionine, for 16 wk. Note the absence of feathers from eyelids, chin, and ventral and lateral mid-cervical (neck) regions.



TABLE 5. Organ weights (grams) of ducks fed diets supplemented with 0, 10, 20, 40, or 80 ppm selenium, as seleno-DL-methionine. All of the ducks in the 80 ppm group died before the end of the 16-wk experiment. A one-way analysis of variance and Tukey's Honestly Significant Difference test for pairwise comparisons were used to compare experimental groups. Sample size, the mean  $\pm$  one standard error, and results of the statistical analysis are shown.

Group (ppm selenium)	Sample size <sup>c</sup>	Liver			Kidney		
		Mean $\pm$ SE	P	Tukey's	Mean $\pm$ SE	P	Tukey's
0	21	19.57 $\pm$ 0.62	0.11		6.28 $\pm$ 0.20	<0.01	A <sup>a</sup>
10	18	21.09 $\pm$ 0.90			6.97 $\pm$ 0.23		A
20	20	21.69 $\pm$ 0.96			6.68 $\pm$ 0.24		A
40	15	20.66 $\pm$ 0.96			6.27 $\pm$ 0.23		A
Died <sup>b</sup>	25	18.99 $\pm$ 0.75			9.07 $\pm$ 0.27		B
		Heart			Spleen		
0	21	8.49 $\pm$ 0.29	<0.01	AB	0.59 $\pm$ 0.06	<0.01	A
10	18	9.32 $\pm$ 0.31		A	0.69 $\pm$ 0.07		A
20	20	8.68 $\pm$ 0.20		AB	0.57 $\pm$ 0.06		A
40	15	7.66 $\pm$ 0.23		BC	0.50 $\pm$ 0.06		A
Died	25	7.10 $\pm$ 0.23		C	0.25 $\pm$ 0.03		B
		Testis			Pancreas <sup>c</sup>		
0	21	3.94 $\pm$ 0.78	<0.01	AB	2.17 $\pm$ 0.08	<0.01	A
10	18	6.81 $\pm$ 1.65		A	2.68 $\pm$ 0.19		A
20	20	1.13 $\pm$ 0.28		B	2.66 $\pm$ 0.12		A
40	15	0.94 $\pm$ 0.46		B	2.05 $\pm$ 0.23		AB
Died	25	1.44 $\pm$ 0.27		B	1.01 $\pm$ 0.50		B

<sup>a</sup> Means that do not share a letter in common are different,  $P \leq 0.05$ .

<sup>b</sup> Includes three ducks from the 40 ppm group and one duck from the 20 ppm group.

<sup>c</sup> Sample size for pancreas was 0 ppm = 10, 10 ppm = 10, 20 ppm = 11, 40 ppm = 8, and Died = 2.

trations in the heart of ducks in the 20 ppm group were greater than Se concentrations in the 0 ppm group. High variance within groups was responsible for the general absence of differences among the 0, 10, and 20 ppm groups.

#### DISCUSSION

The death of 100% and 15% of ducks in the 80 and 40 ppm groups of this study, and the death of 100%, 95%, and 25% of ducks in 80, 40, and 20 ppm groups of a similar study (Heinz and Fitzgerald, 1993a), are evidence that dietary concentrations of Se, as SeM, similar to concentrations found in natural food items from seleniferous areas (Saiki and Lowe, 1987; Hothem and Ohlendorf, 1989) can cause death in adult water birds. The stress of winter temperatures in the Heinz and Fitzgerald (1993a) study, compared to spring and summer temperatures in our study and the study of Hoffman et al.

(1991a) (10% died at 32 ppm), probably was responsible for the lower dietary threshold for reduced survival (20 ppm versus 40 to 80 ppm). Similarly, elevated Se in the water and diet of bluegills (*Lepomis macrochirus*) causes a greater reduction in survival at winter water temperature than at summer water temperature (Lemly, 1993). The dietary threshold for reduced survival for mallard ducklings is between 15 and 60 ppm Se, as SeM, in duck mash (Hoffman et al., 1991a, 1992a).

The dietary exposure to Se for a wild bird can be compared to experimental exposure if the composition and quantity of ingested material, and its metal and metalloid concentrations and interactions are known. However, accurate qualitative and quantitative information on diets is difficult to acquire, and metal and metalloid analyses will have to be performed on food samples. Consequently, determination of dietary exposure to Se by wild birds is a

TABLE 6. Concentrations of selenium (dry weight) in liver, kidney, heart, spleen, and brain of mallard ducks fed diets supplemented with 0, 10, 20, 40, or 80 ppm selenium, as seleno-DL-methionine, for 16 wk. A one-way analysis of variance and Tukey's HSD test for pairwise comparisons were used to compare experimental groups. Sample size, the mean  $\pm$  one standard error, and results of the statistical analysis are shown.

Group (ppm selenium)	Liver				Kidney			
	Sample size	Mean $\pm$ SE	P	Tukey's	Sample size	Mean $\pm$ SE	P	Tukey's
0	10	5.1 $\pm$ 0.3	<0.01	A <sup>a</sup>	10	3.6 $\pm$ 0.1	<0.01	A
10	10	33 $\pm$ 7		A	10	18 $\pm$ 2		A
20	10	49 $\pm$ 9		AB	8	35 $\pm$ 1		A
40	15	87 $\pm$ 11		BC	15	70 $\pm$ 8		B
Died <sup>b</sup>	25	99 $\pm$ 9		C	25	90 $\pm$ 7		B
	Heart				Spleen			
	Sample size	Mean $\pm$ SE	P	Tukey's	Sample size	Mean $\pm$ SE	P	Tukey's
0	10	1.0 $\pm$ 0.1	<0.01	A	10	1.0 $\pm$ 0.2	<0.01	A
10	10	18 $\pm$ 2		AB	10	5 $\pm$ 1		A
20	10	33 $\pm$ 2		B	10	9 $\pm$ 1		A
40	15	77 $\pm$ 8		C	15	21 $\pm$ 3		AB
Died	25	65 $\pm$ 6		C	24	36 $\pm$ 6		B
	Brain							
	Sample size	Mean $\pm$ SE	P	Tukey's				
0	10	1.3 $\pm$ 0.1	<0.01	A				
10	10	13 $\pm$ 1		A				
20	10	25 $\pm$ 3		AB				
40	14	46 $\pm$ 8		BC				
Died	25	53 $\pm$ 5		C				

<sup>a</sup> Means that do not share a letter in common are different,  $P \leq 0.05$ .

<sup>b</sup> Includes three ducks from the 40 ppm group and one duck from the 20 ppm group.

possible, but impractical, indicator of fatal selenosis.

The clinical signs of selenosis observed in ducks consuming dietary concentrations of 40 and 80 ppm Se, as SeM, including anorexia, inattentiveness, lethargy, weakness, and recumbency, were similar to those reported for adult male mallards fed diets high in SeM (Heinz and Fitzgerald, 1993a) and for mallard ducklings fed diets high in SeM or sodium selenite (Heinz et al., 1988). Comparable clinical signs have been reported for selenosis of poultry (Echevarria et al., 1988), livestock (Eisler, 1985), and humans (Jensen et al., 1984). Reduced feed consumption in the present study could have been caused by selenosis or a sufficiently offensive taste which caused avoidance of feed. Immediate decreases in feed consumption by the 40 and 80 ppm groups is evidence that offensive taste was a contributing factor at the beginning of the study.

Although observable in captive birds, clinical signs will be difficult to detect in wild birds; hence, they have limited usefulness as field indicators of selenosis. Also, the clinical signs exhibited by our mallards, singly or in combination, were nonspecific and could be associated with many diseases of birds.

Body weights were reduced by 40 and 80 ppm Se, as SeM, in the diet. The stress of cold (winter) temperatures seems to increase weight loss; adult male mallards consuming 20, 40, and 80 ppm Se had more weight loss during the winter (Heinz and Fitzgerald, 1993a) than during the spring and summer of the present study. The 16% weight loss of adult male mallards receiving 40 ppm Se in this study was similar to the 14% weight loss reported for adult male mallards receiving 32 ppm Se for 14 wk during the spring and summer in another study (Hoffman et al., 1991b). Decreases in body weight for adult female

mallards (Heinz and Fitzgerald, 1993b) and retarded growth of mallard ducklings (Heinz et al., 1988; Hoffman et al., 1991b) also have been reported. The body weight of adult coots found dead or collected by shooting at the Kesterson National Wildlife Refuge in California averaged 25% less than coots from a reference area in 1984 (Ohlendorf et al., 1988) and about 15% less in 1985 (Ohlendorf et al., 1990).

Although loss of weight is a nonspecific change, it is a consistent finding in selenosis of birds and mammals (Harr and Muth, 1972; National Research Council, 1983; Ohlendorf et al., 1988). Mallards that died in the 40 and 80 ppm groups were emaciated, based on knife-edge keels and absence of body fat. Emaciation usually is due to lack of calories or deficiency of one or more essential nutrients (malnutrition), or weight loss secondary to a serious disease, in the presence of adequate nutrition (cachexia). Because ducks that died had high residues of Se in all analyzed organs, emaciation of dead mallards in this study was partially attributed to cachexia secondary to selenosis. The low feed consumption of ducks in the 40 and 80 ppm groups is evidence that malnutrition (food refusal) also contributed to the emaciation. Total starvation in the spring would be expected to kill about 80% of male mallards in less than 4 wk (Jordan, 1953) compared to a 4-wk loss of 38% in the 80 ppm group. The retarded molt and poor condition of old feathers in the 40 ppm ducks were probably due to a combination of inadequate nutrition and reduced preening. Although loss of body weight or unusual feather condition can be readily detected by manual and close visual examination, they could be difficult to assess when distant from the observer.

Effects of nonfatal chronic selenosis appeared limited to a loss of muscle mass and abnormalities of epidermal structures (claws and feathers) (Table 4). We saw no evidence of the anemia, as measured by hematocrit, reported in survivors of 32 ppm Se (Hoffman et al., 1991a). The on-

ychoptosis observed in 53% of surviving mallards in the 40 ppm group was a conservative measure of the incidence of this claw lesion. It was evident during necropsies that intact claws of ducks in the 40 ppm group were easily fractured and detached by mild finger pressure. The loss of claws and feathers is analogous to losses of hair, nails, and hooves reported in humans (Jensen et al., 1984) and livestock (Eisler, 1985; Jubbs et al., 1992) suffering from chronic selenosis. Claw abnormalities have not previously been reported for spontaneous or experimental selenosis in birds, but feather loss from the head was observed in dead and killed coots from the Kesterson National Wildlife Refuge in California (Ohlendorf et al., 1988). The feather loss in coots appeared as a general thinning of feathers over the entire head, whereas mallards in the present study had distinct patterns of loss (Fig. 4a and 4b). Also, chicks from hens (*Gallus gallus*) receiving a grain diet containing 10 ppm Se had a 74% incidence of wry down (Poley and Moxon, 1937).

In contrast to euthanized ducks, ducks that died from fatal selenosis had numerous abnormalities (Table 3). Emaciation (muscle atrophy, severe depletion of fat), empty stomach and intestines, intestinal hemorrhage, bile retention and bile-staining from the mouth to the duodenum, liver necrosis, and atrophy and pallor of the pancreas are all nonspecific changes, either singly or in combinations. As a collective group, these abnormalities imply inadequate food consumption and disease affecting the liver. The empty gastro-intestinal tract, intestinal hemorrhage, and bile retention or staining probably are secondary to inappetence. Absence of the thymus and atrophy of the spleen imply possible difficulties with the immune system. Abnormalities of the extremities were limited to swollen foot pads and digit joints. Abnormalities found in this study have been reported previously in mallards (Heinz, 1993; Heinz and Fitzgerald, 1993a); however, we did not observe the flaccid heart

and yellowish fluid around organs reported by Heinz (1993) and Heinz and Fitzgerald (1993a). Neither did we see the pulmonary edema, pale and swollen livers with rough texture, or excess gelatinous or serofibrous fluids in the body cavity reported in coots and grebes at Kesterson National Wildlife Refuge (Ohlendorf et al., 1988). Abnormalities common to spontaneous selenosis of coots and grebes and experimental selenosis of mallards in this study were severe atrophy of breast muscles, pallor or necrosis of the liver, severe depletion of body fat reserves (dead mallards), and loss of feathers on the head (euthanized mallards).

The absence of claw and feather abnormalities in the high dose group was puzzling. Because only two of 18 mallards on 40 ppm Se but 20 of 21 mallards on 80 ppm Se were dead by week 12, it is possible that selenosis for  $\geq 12$  wk is necessary for the development of claw and feather abnormalities, or that claw and feather abnormalities are more likely to develop during the post-breeding molt. All mallards in this study were in cages with wire bottoms, whereas wild aquatic birds in suspected cases of selenosis will inhabit aquatic and wet soil environments; hence, observations of claw loss could be reduced. Nevertheless, careful examination and manipulation of claws and feathers of dead or sick birds from seleniferous areas is warranted because claw and feather abnormalities might be biomarkers of chronic selenosis in field situations.

Ducks that die from selenosis are likely to exhibit changes in organ weights. Organ weight changes, in general, are nonspecific and can be caused by many diseases. However, the combination of weight loss in the heart, spleen, and pancreas, a weight increase of over 40% for the kidney, and unchanged liver weight might be a characteristic of fatal selenosis in aquatic birds. Mean kidney to body weight percentages ranged from 0.56% to 0.66% for the 0, 10, 20, and 40 ppm groups, whereas ducks that died had a mean of 1.43%, two to

two-and-a-half times greater than surviving ducks. Ohlendorf et al. (1988) reported a 33% incidence of swollen livers in coots and grebes. In comparison, two male mallards that died in a starvation experiment (Jordan, 1953) lost an estimated 69% of their liver weight and 29% of their kidney weight; four starved females lost an average of 57% of their liver weight and 15% of their kidney weight. Sublethal exposure to SeM, even at 40 ppm for 16 wk, probably will not cause sufficient change in organ weights for this criterion to be useful as an indicator of nonfatal selenosis.

The extensive abnormalities, weight loss, and organ weight changes were evidence that high concentrations of ingested SeM affected physiological functions and morphology of major organs. However, physiological functions were not directly measured. The large number and greater severity of abnormalities in ducks that died, compared to the small number and lesser severity of abnormalities in ducks that survived, is evidence that a critical threshold of SeM assimilation exists and, when exceeded, is followed by rapid physiological deterioration and death.

Excess methionine will reduce the effects of Se in SeM and a deficiency of vitamin E will reduce the uptake of Se from the diet (Combs and Combs, 1986; Hoffman et al., 1992b). Because analyzed concentrations of methionine and vitamin E were close to expected concentrations for developer mash, we believe that the effects and uptake of Se in our diets were not reduced.

Selenium in tissues increased with the dietary concentration of Se in this study and with the dietary concentration of organic and inorganic Se in other studies (Moksnes and Norheim, 1982; Heinz et al., 1989; Hoffman et al., 1991a). However, the absence of differences between Se concentrations in tissues of ducks that died and those of euthanized ducks in the 40 ppm group (Table 6) precludes the use of Se concentrations in tissue as the sole indicator of death due to Se toxicosis. Heinz

(1996) also concluded that Se concentrations in soft tissues and blood were too variable to be used as the sole indicator of death. Additionally, concentrations of Se in tissues of females might be reduced by egg laying (Heinz et al., 1989).

In a review of experimental selenosis in mallard ducks, Heinz (1996) concluded that liver concentrations in excess of 20 ppm wet weight (66 ppm dry weight) could cause death, and liver concentrations in excess of 10 ppm wet weight (33 ppm dry weight) could cause some sublethal biochemical effects or microscopic lesions of the liver and spleen. The mean  $\pm$  two standard errors for liver in the 40 ppm group (15% died) and the 80 ppm group (100% died) of this study represented a range of 65 to 109 ppm and 81 to 117 ppm, respectively. Birds inhabiting freshwater environments usually have Se concentrations in the liver and kidney of less than 10 ppm (Ohlendorf, 1989). Birds inhabiting marine environments can have Se concentrations in the liver and kidney in excess of 20 ppm (Ohlendorf et al., 1986; Custer and Myers, 1990). Selenium in birds using agricultural wastewater lakes in Egypt averaged 40 ppm for liver and 38 ppm for kidney (Saleh et al., 1988), whereas American coots collected at the Kesterson National Wildlife Refuge had a mean of 94 ppm in the liver and 97 ppm in the kidney (Ohlendorf et al., 1988). Although considerable variation occurs for tissue concentrations of Se under experimental conditions, the proposed concentration of 66 ppm is appropriate as an indicator of possible macroscopic effects. Selenium concentrations in wild birds should be interpreted cautiously when concentrations of elements that are antagonists of Se (arsenic, cadmium, copper, lead, mercury, silver) are elevated in tissues or in the local environment (Ohlendorf, 1989; Heinz, 1996).

High concentrations of SeM in the diet of experimental and wild female mallards causes developmental abnormalities and death of embryos (Hoffman et al., 1988;

Heinz et al., 1989; Ohlendorf, 1989). Heinz (1996) proposed that a concentration of Se in eggs greater than 3 ppm wet weight (10 ppm dry weight) was likely to be associated with impaired reproduction. In addition, elevated Se concentrations (10 to 200+ ppm) in the liver of mallard adults and ducklings can be associated with significant alterations of glutathione metabolism, increases in lipid peroxidation, plasma protein concentration, and plasma aspartate aminotransferase, and decreases in hepatocellular protein concentration (Hoffman et al., 1989, 1991a, b, 1992a, b).

#### Diagnosing selenium toxicosis

Fatal spontaneous and experimental selenosis can be caused by acute or chronic exposure. Our dead mallards did not have all the gross abnormalities of spontaneous selenosis as reported in wild aquatic birds (Ohlendorf et al., 1988, 1990) because some wild birds die of acute selenosis, amounts of Se ingested by wild birds varies at each feeding, and some wild birds are likely to have concurrent infectious diseases. We propose that abnormalities in coots and grebes (Ohlendorf et al., 1988) and experimental mallards (Heinz and Fitzgerald, 1993a) that were not detected in our mallards, such as extensive serofibrinous coelomic and subcutaneous fluids, pulmonary edema, flaccid heart, and congestive splenomegaly, were abnormalities of acute selenosis. In acute Se poisoning of laboratory and domestic animals, subcutaneous and coelomic fluids, widespread congestion and petechiation of organs, and heart lesions are consistently reported (National Research Council, 1980; Ahmed et al., 1990). Harr and Muth (1972) reported that increased capillary permeability and bradycardia occur in acute selenosis. Cardiovascular effects of acute selenosis are the most probable cause of fluid accumulations, petechiation, and visceral congestion reported in wild coots and grebes. A few coots with selenosis had nodular livers; this abnormality was not encountered in our experimental mallards,

TABLE 7. Comparison of macroscopic characteristics of fatal or non-fatal selenosis in mallards and American coots to characteristics of a variety of other bird diseases.

Disease	Characteristics of selenosis in mallards and American coots								Reference <sup>c</sup>
	Emaci- ation	Feather loss	Claw loss	Lymphoid organ atrophy <sup>a</sup>	Liver necrosis	En- larged kidneys	Subcu- taneous edema or ascites <sup>b</sup>	Flaccid heart	
Intoxications									
Selenium—mallard	++ <sup>d</sup>	+	+	++	++	+	0	0	A
Selenium—mallard	++	0	0	0	++	0	0	+	B
Selenium—coot	++	+	0	0	+	0	++	++	C
Lead	++	0	0	+	±	0	+	+	D, E
Mercury	++	0	0	0	±	±	+	0	F
White phosphorus	0	0	0	0	+	0	0	0	G
Salt	0	0	0	±	0	+	0	0	H, I
Ethylene glycol	0	0	0	0	0	+	0	0	J
Petroleum	0	0	0	0	0	0	0	0	K
Chlorinated pesticides	±	0	0	0	0	0	0	0	D
PCB's	0	0	0	±	+	±	0	0	D, L
Dioxins	++	0	0	0	++	0	++	0	M
Aflatoxin	0	0	0	+	+	0	0	0	N
Poisonous plants									
Castor bean <sup>e</sup>	0	0	0	0	+	0	±	0	O
Crotalaria <sup>f</sup>	0	0	0	0	?	0	+	0	P
Bishop's weed <sup>g</sup>	0	+	0	0	+	0	0	0	Q
Algae <sup>h</sup>	0	0	0	0	?	0	0	0	R
Nutritional deficiencies									
Vitamin A	+	?	0	0	0	0	0	+	S
Selenium	±	?	0	0	0	0	+	0	T, U
Parasites									
Feather mites	0	+	0	0	0	0	0	0	V
Blood, liver flukes	+	0	0	0	+	0	0	0	W, X, Y
<i>Leucocytozoon</i> spp.	±	0	0	0	+	0	0	0	Z
Fungi, bacteria									
<i>Aspergillus</i> spp.	+	0	0	0	+	0	0	0	D
Avian cholera <sup>i</sup>	0	0	0	0	+	0	±	±	AA

and could represent concurrent infectious diseases or reparative and regenerative hepatic processes between bouts of nonlethal selenosis. Variation in length of residence at sites with toxic levels of Se in food items makes it likely that acute, chronic, and reparative stages of selenosis will be present simultaneously in populations of wild aquatic birds.

Emaciation is a non-specific abnormality associated with many infectious diseases, intoxications, neoplasms, and nutritional deficiencies (for references, see Table 7), but it is a consistent finding in chronic selenosis of birds and mammals. Birds that

die of starvation (Jordan, 1953) or deficiency of essential nutrients generally lack the liver necrosis, enlarged kidneys, coelomic fluids, feather and claw abnormalities, and flaccid heart found in mallards, coots, and grebes with fatal and non-fatal selenosis. Plumbism can resemble selenosis grossly; however, presence of dilatation and impaction of the proventriculus, and lack of large foci of liver necrosis, enlarged kidneys, and feather and claw abnormalities in plumbism are key distinguishing features. Emaciation due to infectious diseases and neoplasms (cachexia) is distinguishable from uncomplicated selenosis by

TABLE 7. Continued.

Disease	Characteristics of selenosis in mallards and American coots								Reference <sup>c</sup>
	Emaciation	Feather loss	Claw loss	Lymphoid organ atrophy <sup>a</sup>	Liver necrosis	Enlarged kidneys	Subcutaneous edema or ascites <sup>b</sup>	Flaccid heart	
<i>Mycobacterium</i> spp.	++	0	0	0	+	±	0	0	BB
<i>Salmonella</i> spp.	+	0	0	0	+	±	+	0	D
<i>Campylobacter</i> spp. <sup>j</sup>	±	0	0	0	+	0	0	0	CC, DD
<i>Listeria</i> spp.	±	0	0	0	+	0	±	0	EE
Chlamydiae	+	0	0	0	+	0	+	0	FF
<b>Viruses</b>									
DVE <sup>k</sup>	0	0	0	0	+	0	+	0	D
DVH <sup>l</sup>	0	0	0	0	++	+	0	0	GG
GVH <sup>m</sup>	0	0	0	0	+	0	++	±	HH
Reovirus	?	?	0	+	+	0	0	0	II
Poxvirus	±	±	0	0	±	0	0	0	D

<sup>a</sup> Primarily thymus and spleen.<sup>b</sup> Gelatinous or serofibrinous coelomic and subcutaneous fluids or yellow translucent fluids around some organs.<sup>c</sup> References: A: This study; B: Heinz and Fitzgerald, 1993a; C: Ohlendorf et al., 1988; D: Wobeser, 1981; E: Pokras and Chafel, 1992; F: Pass et al., 1975; G: P. Klein, pers. comm., 1994; H: Mitcham and Wobeser, 1988a; I: Mitcham and Wobeser, 1988b; J: Riddell et al., 1967; K: Leighton, 1991; L: Eisler, 1986a; M: Eisler, 1986b; N: Robinson et al., 1982; O: Jensen and Allen, 1981; P: Alfonso et al., 1993; Q: Eged et al., 1974; R: Short and Edwards, 1990; S: Wobeser and Kost, 1992; T: National Research Council, 1983; U: Van Vleet, 1982; V: Arends, 1991; W: Pence and Rhodes, 1982; X: Wojcinski et al., 1987; Y: Pence and Childs, 1972; Z: Newberne, 1957; AA: Hunter and Wobeser, 1980; BB: Montali et al., 1978; CC: Shane, 1991; DD: Kapperud et al., 1983; EE: Gray, 1958; FF: Franson and Pearson, 1995; GG: Woolcott and Fabricant, 1991; HH: Gough, 1991; II: Rosenberger and Olsen, 1991.<sup>d</sup> 0: Characteristic not associated with the disease; ±: Characteristic occasionally or inconsistently reported; +: Characteristic mild and commonly associated with the disease; ++: Characteristic marked and consistently found in the disease; ?: Characteristic probably present but inadequately described in the literature.<sup>e</sup> *Ricinus communis*.<sup>f</sup> *Crotalaria retusa* and *C. spectabilis*.<sup>g</sup> Bishops's weed, *Ammi majus*.<sup>h</sup> *Microcystis aeruginosa*.<sup>i</sup> *Pasteurella multocida*, avian cholera.<sup>j</sup> *Campylobacter* spp., including avian vibronic hepatitis.<sup>k</sup> DVE, duck viral enteritis, duck plague.<sup>l</sup> DVH, duck viral hepatitis, including parvoviruses and astrovirus.<sup>m</sup> GVH, goose viral hepatitis, a picornavirus.

the presence of abscesses, large numbers of parasites (or their eggs), or neoplastic nodules. Most reported viral infections of water birds either kill the birds before emaciation occurs, as in the case of duck (herpes-) viral enteritis, or cause emaciation and death only in very young waterfowl in captivity, as with duck picornaviral hepatitis and gosling parvoviral hepatitis.

The marked patches of yellowish-tan liver necrosis in mallards with chronic fatal selenosis resembles few other diseases. Most bacterial, viral and protozoan infections produce swollen livers with abscesses, granulomas, or small foci of necrosis.

Other intoxications, such as lead, phosphorus, dioxins, and aflatoxins (Table 7) can cause liver necrosis, but the other abnormalities associated with selenosis are not present.

The claw and feather abnormalities of selenosis could be unique. Onychoptosis apparently has not been associated with any spontaneous diseases of wild aquatic birds, although it is reasonable to expect it in cases of trauma. Deptylation is uncommon in wild aquatic birds and likely to be of undetermined cause (Roy et al., 1986). Several viral, mycotic and ectoparasitic infections can cause feather loss in birds (Ta-

ble 7) but not in the patterns observed on the head and neck of mallards and coots.

Concurrent infectious diseases and selenosis are to be expected in wild birds. In many infectious diseases, such as mycobacteriosis, avian cholera, and aspergillosis, macroscopic abnormalities could overwhelm the abnormalities of selenosis. In these situations, careful attention should be directed to the thymus, spleen, feathers, claws, and weight of kidneys. Ultimately, histological examinations, microbial cultures, and chemical analyses may be necessary, especially if only a few birds are examined. Because concurrent metal and Se intoxications are possible, careful examinations of the kidneys, liver, feathers, and claws might be helpful.

#### **Proposed diagnostic criteria for Se toxicosis**

We propose criteria for diagnosis of Se toxicosis derived from macroscopic abnormalities, biochemical changes, and concentrations of Se in tissues from this study, other pen studies on mallards, and two field studies of American coots and pied-billed grebes. Additional diagnostic criteria based on histologic lesions are being prepared (D. E. Green and P. H. Albers, unpubl.).

Key diagnostic features of fatal chronic selenosis in aquatic birds are low body weight or emaciation (25 to 50% below normal) to include severe atrophy of fat and breast muscles, severe atrophy or absence of immune system organs (spleen and thymus, respectively), liver necrosis (this study) or an enlarged nodular liver (Ohlendorf et al., 1988), pale atrophied pancreas, enlarged kidneys (up to 40% heavier than normal), and a concentration of Se in the liver that exceeds 66 ppm dry weight (Heinz, 1996). The presence of flaccid heart and extensive coelomic and subcutaneous fluids (Ohlendorf et al., 1988; Heinz and Fitzgerald, 1993a) would be evidence for acute selenosis.

Nonfatal chronic selenosis is characterized by low body weight (10 to 15% below

normal) due mostly to loss of breast muscle mass, poor plumage, delayed molt or depterylation on the head or neck, onychoptosis, a concentration of Se in the liver that exceeds 66 ppm dry weight, reduced hatching success or an increased number of musculoskeletal abnormalities in embryos, and eggs that have a concentration of Se exceeding 10 ppm dry weight (Heinz, 1996). Biochemical indicators include alterations in glutathione metabolism, lipid peroxidation, hepatocellular protein concentration, plasma protein concentration, and plasma aspartate aminotransferase (Hoffman et al., 1989, 1991a, b, 1992a, b).

Mallards in our study were presented with nutritionally-balanced commercial food containing concentrations of Se that remained constant throughout a 16-wk period, whereas wild aquatic birds ingest foods of varying nutritional quality that contain differing concentrations of Se and other naturally-occurring metals, metalloids, and plant phytotoxins (Deason, 1989; James et al., 1983; Short and Edwards, 1990). Interactions between Se and other elements, especially boron, arsenic, or mercury, could alter the effects of Se alone (Ohlendorf, 1989; Hoffman et al., 1991b; Stanley et al., 1994). Consequently, we recommend that at least three birds per species be examined and at least three of the above listed diagnostic criteria be present in order to establish a probable diagnosis of fatal or nonfatal selenosis.

#### **ACKNOWLEDGMENTS**

We thank Gary H. Heinz, David J. Hoffman, Patrice Klein, Glenn Olsen, Grey W. Pendleton, Harry M. Ohlendorf, and an anonymous reviewer for their helpful comments. Use of trade names or names of suppliers does not imply endorsement by the federal government. Funding was provided under the U.S. Bureau of Reclamation-U.S. Fish and Wildlife Service Intra-agency Agreement No. 6-AA-20-04170.

#### **LITERATURE CITED**

- AHMED, K. E., S. E. I. ADAM, O. F. IDRILL, AND A. A. WAHBI. 1990. Experimental selenium poison-



- ing in Nubian goats. *Veterinary and Human Toxicology* 32: 249–251.
- ALFONSO, H. A., L. M. SANCHEZ, M. A. FIGUERO, AND B. C. GOMEZ. 1993. Intoxication due to *Crotalaria retusa* and *C. spectabilis* in chickens and geese. *Veterinary and Human Toxicology* 35: 539.
- ARENDS, J. J. 1991. External parasites and poultry pests. In *Diseases of poultry*, 9th ed. B. W. Calnek (ed.). Iowa State University Press, Ames, Iowa, pp. 702–730.
- ASSOCIATION OF OFFICIAL ANALYTICAL CHEMISTS. 1990. Method 982.30. In *Official methods of analysis*, 15th ed. K. Helrich (ed.). Association of Official Analytical Chemists, Arlington, Virginia, pp. 1096–1098.
- BEARD, C. W. 1980. Serologic procedures. In *Isolation and identification of avian pathogens*, 2nd ed. S. B. Hitchner, C. H. Domeruth, H. G. Purchase, and J. E. Williams (eds.). Creative Publishing Company, New York, New York, pp. 129–135.
- BURAU, R. G. 1989. Selenium in arid and semiarid soils. *Journal of Irrigation Drainage Engineering* 115: 42–47.
- COMBS, G. F., JR., AND S. B. COMBS. 1986. The role of selenium in nutrition. Academic Press, Orlando, Florida, 532 pp.
- CORT, W. M., T. S. VINCENTE, E. H. WAYSEK, AND B. D. WILLIAMS. 1983. Vitamin E content of feedstuffs determined by high-performance liquid chromatographic fluorescence. *Journal of Agricultural Food Chemistry* 31: 1330–1333.
- CUSTER, T. W., AND J. P. MYERS. 1990. Organochlorines, mercury, and selenium in wintering shorebirds from Washington and California. *California Fish and Game* 76: 118–125.
- DEASON, J. P. 1989. Irrigation-induced contamination: How real a problem? *Journal of Irrigation Drainage Engineering* 115: 9–20.
- ECHEVARRIA, M. G., P. R. HENRY, C. B. AMMERMAN, P. V. RAO, AND R. D. MILES. 1988. Estimation of the relative bioavailability of inorganic selenium sources for poultry. I. Effect of time and high dietary selenium on tissue selenium uptake. *Poultry Science* 67: 1295–1301.
- EGYED, M. N., M. MALKINSON, AND A. SHLOSBERG. 1974. Observations on the experimental poisoning of young geese with *Ammi majus*. *Avian Pathology* 3: 79–87.
- EISLER, R. 1985. Selenium hazards to fish, wildlife, and invertebrates: A synoptic review. *Biological Report* 85(1.5), U.S. Fish and Wildlife Service, Washington, D.C., 57 pp.
- . 1986a. Polychlorinated biphenyl hazards to fish, wildlife, and invertebrates: A synoptic review. *Biological Report* 85(1.7), U.S. Fish and Wildlife Service, Washington, D.C., 72 pp.
- . 1986b. Dioxin hazards to fish, wildlife, and invertebrates: A synoptic review. *Biological Report* 85(1.8), U.S. Fish and Wildlife Service, Washington, D.C., 37 pp.
- FRANSON, J. C., AND J. E. PEARSON. 1995. Probable epizootic chlamydiosis in wild California (*Larus californicus*) and ring-billed (*L. delawarensis*) gulls in North Dakota. *Journal of Wildlife Diseases* 31: 424–427.
- GOUGH, R. E. 1991. Goose parvovirus infection. In *Diseases of poultry*, 9th ed. B. W. Calnek (ed.). Iowa State University Press, Ames, Iowa, pp. 684–690.
- GRAY, M. L. 1958. Listeriosis in fowls—A review. *Avian Diseases* 2: 296–314.
- HARR, J. R., AND O. H. MUTH. 1972. Selenium poisoning in domestic animals and its relationship to man. *Clinical Toxicology* 5: 175–186.
- HEINZ, G. H. 1993. Re-exposure of mallards to selenium after chronic exposure. *Environmental Toxicology and Chemistry* 12: 1691–1694.
- . 1996. Selenium in birds. In *Environmental contaminants in wildlife. Interpreting tissue concentrations*, W. N. Beyer, G. H. Heinz, and A. W. Redmond-Norwood (eds.). Society of Environmental Toxicology and Chemistry Special Publication. CRC Press, Inc., Boca Raton, Florida, pp. 447–458.
- , AND M. A. FITZGERALD. 1993a. Overwinter survival of mallards fed selenium. *Archives of Environmental Contamination and Toxicology* 25: 90–94.
- , AND ———. 1993b. Reproduction of mallards following overwinter exposure to selenium. *Environmental Pollution* 81: 117–122.
- , D. J. HOFFMAN, AND L. G. GOLD. 1988. Toxicity of organic and inorganic selenium to mallard ducklings. *Archives of Environmental Contamination and Toxicology* 17: 561–568.
- , ———, AND ———. 1989. Impaired reproduction of mallards fed an organic form of selenium. *The Journal of Wildlife Management* 53: 418–428.
- HITCHNER, S. B. 1980. Virus propagation in embryonating eggs. In *Isolation and identification of avian pathogens*, 2nd ed. S. B. Hitchner, C. H. Domeruth, H. G. Purchase, and J. E. Williams (eds.). Creative Publishing Company, New York, New York, pp. 120–121.
- HOFFMAN, D. J., AND G. H. HEINZ. 1988. Embryotoxic and teratogenic effects of selenium in the diet of mallards. *Journal of Toxicology and Environmental Health* 24: 263–271.
- , H. M. OHLENDORF, AND T. W. ALDRICH. 1988. Selenium teratogenesis in natural populations of aquatic birds in central California. *Archives of Environmental Contamination and Toxicology* 17: 519–525.
- , G. H. HEINZ, AND A. J. KRYNITSKY. 1989. Hepatic glutathione metabolism and lipid peroxidation in response to excess dietary selenomethionine and selenite in mallard ducklings.

- Journal of Toxicology and Environmental Health 27: 263–271.
- , L. J. LECAPTAIN, C. M. BUNCK, AND D. E. GREEN. 1991a. Subchronic hepatotoxicity of selenomethionine ingestion in mallard ducks. Journal of Toxicology and Environmental Health 32: 449–464.
- , C. J. SANDERSON, L. J. LECAPTAIN, E. CROMARTIE, AND G. W. PENDLETON. 1991b. Interactive effects of boron, selenium, and dietary protein on survival, growth, and physiology in mallard ducklings. Archives of Environmental Contamination and Toxicology 20: 288–294.
- , ———, ———, ———, AND ———. 1992a. Interactive effects of arsenate, selenium, and dietary protein on survival, growth, and physiology in mallard ducklings. Archives of Environmental Contamination and Toxicology 22: 55–62.
- , ———, ———, ———, AND ———. 1992b. Interactive effects of selenium, methionine, and dietary protein on survival, growth, and physiology in mallard ducklings. Archives of Environmental Contamination and Toxicology 23: 163–171.
- HOTHEM, R. L., AND H. M. OHLENDORF. 1989. Contaminants in foods of aquatic birds at Kesterson Reservoir, California, 1985. Archives of Environmental Contamination and Toxicology 18: 773–786.
- HUNTER, B., AND G. WOBESER. 1980. Pathology of experimental avian cholera in mallard ducks. Avian Diseases 24: 403–414.
- JAMES, L. F., K. V. VAN KAMPEN, AND W. J. HARTLEY. 1983. *Astragalus bisulcatus*—a cause of selenium or locoweed poisoning? Veterinary and Human Toxicology 25: 86–89.
- JENSEN, R., W. CLOSSON, AND R. ROTHENBERG. 1984. Selenium intoxication—New York. Morbidity and Mortality Weekly Report 33: 157–158.
- JENSEN, W. I., AND J. P. ALLEN. 1981. Naturally occurring and experimentally induced castor bean (*Ricinus communis*) poisoning in ducks. Avian Diseases 25: 184–194.
- JORDAN, J. S. 1953. Effects of starvation on wild mallards. The Journal of Wildlife Management 17: 304–311.
- JUBB, K. V. F., P. C. KENNEDY, AND N. PALMER. 1992. Pathology of domestic animals. 4th ed. Academic Press, Inc., San Diego, California, 780 pp.
- KAPPERUD, G. O., O. ROSEF, O. W. ROSTAD, AND G. LID. 1983. Isolation of *Campylobacter fetus* subsp. *jejuni* from the common puffin (*Fratercula arctica*) in Norway. Journal of Wildlife Diseases 19: 64–65.
- KRYNITSKY, A. J. 1987. Preparation of biological tissue for determination of arsenic and selenium by graphite furnace atomic absorption spectrometry. Analytical Chemistry 59: 1884–1886.
- LEIGHTON, F. A. 1991. The toxicity of petroleum oils to birds: An overview. In The effects of oil on wildlife, J. White, L. Frink, T. M. Williams, and R. W. Davis (eds.). The Sheridan Press, Hanover Pennsylvania, pp. 43–57.
- LEMELY, A. D. 1993. Metabolic stress during winter increases the toxicity of selenium to fish. Aquatic Toxicology 27: 133–158.
- LIU, C. 1969. Fluorescent antibody technics. In Diagnostic procedures for viral and rickettsial infections. 4th ed. E. H. Lennette and N. J. Schmidt (eds.). American Public Health Association, New York, New York, pp. 179–204.
- MITCHAM, S. A., AND G. WOBESER. 1988a. Effects of sodium and magnesium sulfate in drinking water on mallard ducklings. Journal of Wildlife Diseases 24: 30–44.
- , AND ———. 1988b. Toxic effects of natural saline waters on mallard ducklings. Journal of Wildlife Diseases 24: 45–50.
- MOKSNES, K., AND G. NORHEIM. 1982. Selenium concentrations in tissues and eggs of growing and laying chickens fed sodium selenite at different levels. Acta Veterinaria Scandinavica 23: 368–379.
- MONTALI, R. J., M. BUSH, AND E. E. SMITH. 1978. Pathology of tuberculosis in captive exotic birds. In Mycobacterial infections of zoo animals, R. J. Montali (ed.). Smithsonian Institution Press, Washington, D.C., pp. 209–215.
- NATIONAL ACADEMY OF SCIENCES. 1976. Selenium. Committee on Medical and Biological Effects of Environmental Pollutants, Division of Medical Sciences, National Research Council. National Academy of Sciences, Washington, D.C., 203 pp.
- . 1980. Selenium. In Mineral tolerance of domestic animals. National Academy Press, Washington, D.C., pp. 392–420.
- NATIONAL RESEARCH COUNCIL. 1983. Selenium in nutrition. Subcommittee on Selenium, Committee on Animal Nutrition, Board on Agriculture. National Academy Press, Washington, D.C., 174 pp.
- NEWBERNE, J. W. 1957. Studies on the histopathology of *Leucocytozoon simondi* infection. American Journal of Veterinary Research 18: 191–197.
- OHLENDORF, H. M. 1989. Bioaccumulation and effects of selenium in wildlife. In Selenium in agriculture and the environment, Special Publication Number 23, Soil Science Society of America, Madison, Wisconsin, pp. 133–177.
- , R. W. LOWE, P. R. KELLY, AND T. E. HARVEY. 1986. Selenium and heavy metals in San Francisco Bay diving ducks. The Journal of Wildlife Management 50: 64–71.
- , A. W. KILNESS, J. L. SIMMONS, R. K. STROUD, D. J. HOFFMAN, AND J. F. MOORE. 1988. Selenium toxicosis in wild aquatic birds. Journal of Toxicology and Environmental Health 24: 67–92.

- , R. L. HOTHEM, C. M. BUNCK, AND K. C. MAROIS. 1990. Bioaccumulation of selenium in birds at Kesterson Reservoir, California. *Archives of Environmental Contamination and Toxicology* 19: 495–507.
- PASS, D. A., P. B. LITTLE, AND L. H. KARSTAD. 1975. The pathology of subacute and chronic methyl mercury poisoning of the mallard duck (*Anas platyrhynchos*). *Journal of Comparative Pathology* 85: 7–21.
- PENCE, D. B., AND G. E. CHILDS. 1972. Pathology of *Amphimerus elongatus* (Digena: Opisthorchiidae) in the liver of the double-crested cormorant. *Journal of Wildlife Diseases* 8: 221–224.
- , AND M. J. RHODES. 1982. *Trichobilharzia physellae* (Digena: Schistosomatidae) from endemic waterfowl on the High Plains of Texas. *Journal of Wildlife Diseases* 18: 69–74.
- POKRAS, M. A., AND R. CHAFEL. 1992. Lead toxicosis from ingested fishing sinkers in adult loons (*Gavia immer*) in New England. *Journal of Zoo and Wildlife Medicine* 23: 92–97.
- POLEY, W. E., AND A. L. MOXON. 1937. Tolerance levels of seleniferous grains in laying rations. *Poultry Science* 17: 72–76.
- PRESSER, T. S., AND H. M. OHLENDORF. 1987. Biogeochemical cycling of selenium in the San Joaquin Valley, California, USA. *Environmental Management* 11: 805–821.
- , M. A. SYLVESTER, AND W. H. LOW. 1994. Bioaccumulation of selenium from natural geologic sources in western states and its potential consequences. *Environmental Management* 18: 423–436.
- RIDDELL, C., S. W. NIELSEN, AND E. J. KERSTING. 1967. Ethylene glycol poisoning in poultry. *Journal of the American Veterinary Medical Association* 150: 1531–1535.
- ROBINSON, R. M., A. C. RAY, J. C. REAGOR, AND L. A. HOLLAND. 1982. Waterfowl mortality caused by aflatoxicosis in Texas. *Journal of Wildlife Diseases* 18: 311–313.
- ROSENBERGER, J. K., AND N. O. OLSON. 1991. Reovirus infections. In *Diseases of poultry*, 9th ed. B. W. Calnek (ed.). Iowa State University Press, Ames, Iowa, pp. 639–647.
- ROSENFELD, I., AND O. A. BEATH. 1964. Selenium. Geobotany, biochemistry, toxicity, and nutrition. Academic Press, New York, 411 pp.
- ROY, N. A., W. THRELFALL, AND T. A. WHEELER. 1986. Feather loss of unknown etiology in a gull colony in Newfoundland, Canada. *Journal of Wildlife Diseases* 22: 591–594.
- SAIKI, M. K., AND T. P. LOWE. 1987. Selenium in aquatic organisms from subsurface agricultural drainage water, San Joaquin Valley, California. *Archives of Environmental Contamination and Toxicology* 16: 657–670.
- SALEH, M. A., M. A. SALEH, M. M. FOUHA, M. A. SALEH, M. S. A. LATTIF, AND B. L. WILSON. 1988. Inorganic pollution of the man-made lakes of Wadi El-Raiyan and its impact on aquaculture and wildlife of the surrounding Egyptian desert. *Archives of Environmental Contamination and Toxicology* 17: 391–403.
- SAS INSTITUTE. 1988. SAS/STAT user's guide, release 6.03 edition. SAS Institute, Inc., Cary, North Carolina, 1028 pp.
- SHANE, S. M. 1991. Campylobacteriosis. In *Diseases of poultry*, 9th ed. B. W. Calnek (ed.). Iowa State University Press, Ames, Iowa, pp. 236–246.
- SHORT, S. B., AND W. C. EDWARDS. 1990. Blue-green algae toxicosis in Oklahoma. *Veterinary and Human Toxicology* 32: 558–560.
- SIEGEL, S. 1956. Nonparametric statistics for the behavioral sciences. McGraw-Hill Book Company, New York, New York, 312 pp.
- SLAVIN, W., G. R. CARNICK, D. C. MANNING, AND E. PRUSZKOWSKA. 1983. Recent experiences with stabilized temperature platform furnace and Zeeman background correction. *Atomic Spectroscopy* 4: 69–86.
- STANLEY, T. R., JR., J. W. SPANN, G. J. SMITH, AND R. ROSSCOE. 1994. Main and interactive effects of arsenic and selenium on mallard reproduction and duckling growth and survival. *Archives of Environmental Contamination and Toxicology* 26: 444–451.
- THRALL, M. A. 1985. Hematology. In *Laboratory procedures for animal health technicians*, P. W. Pratt (ed.). American Veterinary Publications, Santa Barbara, California, pp. 39–88.
- VAN VLEET, J. F. 1982. Amounts of eight combined elements required to induce selenium-vitamin E deficiency in ducklings and protection by supplements of selenium and vitamin E. *American Journal of Veterinary Research* 43: 1049–1055.
- WADE, W. F., AND S. M. GAFAF. 1985. Internal parasites. In *Laboratory procedures for animal health technicians*, P. W. Pratt (ed.). American Veterinary Publications, Santa Barbara, California, pp. 271–331.
- WOBESER, G. A. 1981. *Diseases of wild waterfowl*. Plenum Press, New York, New York, 300 pp.
- , AND W. KOST. 1992. Starvation, staphylococcosis, and vitamin A deficiency among mallards overwintering in Saskatchewan. *Journal of Wildlife Diseases* 28: 215–222.
- WOJCINSKI, Z. W., I. K. BARKER, D. B. HUNTER, AND H. LUMSDEN. 1987. An outbreak of schistosomiasis in Atlantic brant geese, *Branta bernicla hrota*. *Journal of Wildlife Diseases* 23: 248–255.
- WOOLCOTT, P. R., AND J. FABRICANT. 1991. Duck virus hepatitis. In *Diseases of poultry*, 9th ed. B. W. Calnek (ed.). Iowa State University Press, Ames, Iowa, pp. 597–608.

Received for publication 31 March 1995.