



Baseline Coagulation Assay Values for Northern Elephant Seals (*Mirounga angustirostris*), and Disseminated Intravascular Coagulation in This Species

Authors: Gulland, F. M. D., Werner, L., O'Neill, S., Lowenstine, L. J., Trupkiewitz, J., et al.

Source: Journal of Wildlife Diseases, 32(3) : 536-540

Published By: Wildlife Disease Association

URL: <https://doi.org/10.7589/0090-3558-32.3.536>

BioOne Complete (complete.BioOne.org) is a full-text database of 200 subscribed and open-access titles in the biological, ecological, and environmental sciences published by nonprofit societies, associations, museums, institutions, and presses.

Your use of this PDF, the BioOne Complete website, and all posted and associated content indicates your acceptance of BioOne's Terms of Use, available at www.bioone.org/terms-of-use.

Usage of BioOne Complete content is strictly limited to personal, educational, and non - commercial use. Commercial inquiries or rights and permissions requests should be directed to the individual publisher as copyright holder.

BioOne sees sustainable scholarly publishing as an inherently collaborative enterprise connecting authors, nonprofit publishers, academic institutions, research libraries, and research funders in the common goal of maximizing access to critical research.

Baseline Coagulation Assay Values for Northern Elephant Seals (*Mirounga angustirostris*), and Disseminated Intravascular Coagulation in This Species

F. M. D. Gulland,¹ L. Werner,² S. O'Neill,² L. J. Lowenstine,^{2,3} J. Trupkiewitz,² D. Smith,² B. Royal,¹ and I. Strubel,¹ ¹The Marine Mammal Center, Golden Gate National Recreation Area, Marin Headlands, Sausalito, California 94965, USA; ²Department of Pathology, Microbiology and Immunology, University of California, Davis, California 95616, USA; ³Pathology Department, Center for Reproduction of Endangered Species, Zoological Society of San Diego, California 92112-0551, USA

ABSTRACT: Coagulation assays, including platelet counts, antithrombin III, fibrinogen, fibrinogen degradation product levels, prothrombin (PT), activated partial thromboplastin (APTT) and activated clotting times (ACT), were performed on 20 healthy juvenile northern elephant seals (*Mirounga angustirostris*) stranded along the central California coastline from 15 March to 15 April 1994, to establish baseline parameters for this species. Elephant seals appear to have relatively short ACT, PT, and APTT times, while fibrinogen, platelet and antithrombin III levels are similar to domestic species. Based on these mean values in healthy animals, disseminated intravascular coagulation (DIC) was diagnosed in an elephant seal with low plasma fibrinogen and extended ACT, PT and APTT times; this animal had hemorrhages, mixed bacterial suppurative interstitial pneumonia with verminous arteritis, epicarditis, hepatitis and enterocolitis.

Key words: Elephant seal, *Mirounga angustirostris*, phocid, disseminated intravascular coagulation, fibrinogen, clotting, hematology.

Between 1 March and 30 July 1993, post mortem examinations were performed on 52 northern elephant seals (*Mirounga angustirostris*) that died during rehabilitation following live stranding along the central California (USA) coastline (32°59' to 37°42'N, 121°30' to 123°05'W); 22 (42%) of these had severe pulmonary arteritis often accompanied by septicemia. Microthrombi were often present in multiple organs. We believe that disseminated intravascular coagulation (DIC) was an important process associated with mortality.

Disseminated intravascular coagulation is a pathological state induced by many types of disease, which itself can cause severe pathology (Feldman et al., 1986). It is a hypercoagulable state resulting from simultaneous activation of platelets, the in-

trinsic and extrinsic blood coagulation pathways and the fibrinolytic system, with loss of the ability to re-establish a hemostatic equilibrium (Bick, 1994). Progression of hypercoagulability leads to microvascular occlusion, organ failure, consumptive depletion of both platelets and clotting factors, and the development of a hypocoagulable state expressed as clinical bleeding (Coles, 1986). Systemic accumulation of soluble fibrin and fibrinogen degradation products (FDPs) occurs, these exacerbating the bleeding tendency due to their potent anticoagulant effects (Bick, 1994).

There is no single or specific laboratory test for identifying a state of DIC. Diagnosis in the live animal depends upon detection of a bleeding tendency and multiple abnormalities in a coagulogram (Bick, 1994). A database for diagnosis ideally consists of clotting times (prothrombin time, PT, and partial thromboplastin time, PTT), platelet count, plasma fibrinogen and FDP levels. Typically, not all of these results will be abnormal at any one time, due to fluctuations in disease progression and compensatory mechanisms to re-establish hemostatic homeostasis. Our purpose was to document baseline coagulation assay values in the northern elephant seal, and to describe a case where DIC was diagnosed in a living animal using these data.

Blood was collected aseptically from 20 apparently healthy, stranded northern elephant seals as part of routine monitoring during their rehabilitation. All animals stranded between 15 March and 15 April

1994 along the northern California coast (32°59' to 37°42'N, 121°30' to 123°05'W) and were sampled between 15 May and 15 June 1994. All animals were between 4 and 6 mo old (Le Boeuf et al., 1972) and were acclimatized to the rehabilitation center (The Marine Mammal Center, Sausalito, California). Samples were collected from the extradural intravertebral sinus 5 cm cranial to the pelvis using an 18 gauge × 38 mm needle (Bossart and Dierauf, 1990). Two ml were placed immediately into a pre-warmed Vacutainer tube (Becton-Dickinson and Company, Franklin Lakes, New Jersey, USA) containing purified inert silica. The tube was held at 37 C for 60 sec and then inverted every 5 to 10 sec until a clot was detected. The period between blood first entering the tube and initial signs of clot formation was recorded as the activated clotting time (ACT) (Feldman et al., 1986). The remaining blood was distributed among four Vacutainers containing either ethylenediamine-tetra-acetic acid (EDTA), citrate, thrombin soya trypsin or serum separation gel (Becton-Dickinson and Company). Citrated samples had a 10:1 ratio of blood to citrate. Plasma and serum were harvested following immediate centrifugation at $2,000 \times G$ for 30 min. Complete blood counts were done on blood collected into EDTA using the Nova Cell-Trak 2 (Nova Biomedical, Boston, Massachusetts, USA). Platelet counts were performed manually using a hemocytometer and the Unopette system (Unopette No. 5855, Becton-Dickinson, Rutherford, New Jersey). Blood smears were stained with a modified Wright's stain (Hema Tek, Miles, Inc., Elkhart, Indiana, USA) and differential white cell counts were performed manually. One stage PTs were performed by adding tissue thromboplastin and calcium to citrated plasma (Thromboplastin, Dade, Puerto Rico) (Hougie, 1972a). Activated partial thromboplastin times (APTT) were measured using phospholipid and a factor XII activator (Actin, Dade, Puerto Rico) (Hougie, 1972b). Antithrombin III was

TABLE 1. Baseline coagulation assay values from 20 northern elephant seals (*Mirounga angustirostris*).

Coagulation assay	Sample size	Mean (SD)	Range
Prothrombin time (sec)	19	12 (0.85)	10.3–13.7
Activated partial thromboplastin time (sec)	19	22.8 (2.6)	17.6–28
Citrated fibrinogen (mg/dl)	19	106 (28)	50–162
56 C fibrinogen (mg/dl)	19	179 (87)	100–300
Fibrinogen degradation products (monoclonal)	20	0	0
Fibrinogen degradation products (polyclonal)	6	0	0
Antithrombin III (%)	19	95 (14)	70–120
Platelets ($\times 10^5$ /ml)	20	513 (173)	167–859
Total protein (g/dl)	14	7.5 (0.3)	6.9–8.1
Activated clotting time (sec)	8	67 (6)	55–70

evaluated using thrombin-specific substrate (S-2238), a synthetic peptide (KabiVitrum, Stockholm, Sweden). Prothrombin time, APTT and Antithrombin III assays were all performed on citrated plasma. Fibrinogen degradation products were evaluated by latex agglutination of antibody coated particles (ThromboWellcotest, Murex Diagnostics, Norcross, Georgia, USA) and by a monoclonal latex agglutination method on citrated plasma (Fibrinosticon, Organon-Teknika, Durham, North Carolina, USA). Total protein was determined refractometrically (Foster et al., 1959). Fibrinogen was determined both by 56 C precipitation (Foster et al., 1959) and by modified thrombin clotting time (Morse et al., 1971). For some parameters, the sample size was less than 20, as samples that were clotted or severely hemolyzed were discarded. The ranges for fibrinogen, antithrombin III and activated clotting time (ACT) were established using the method of Solberg (1981).

Based on these results (Table 1), we believe elephant seals have relatively short

ACT, PT and APTT times compared to domestic animal species, while fibrinogen, platelet and antithrombin III levels are similar (Coles, 1986).

On 3 July 1994, a 6-mo-old, 60-kg female northern elephant seal stranded on Pismo Dunes, central California (32°08'N; 121°39'W). Dehydration was the only clinical abnormality detected. Blood was collected for routine hematology and serum biochemical analysis, and results were within published normal ranges for this species (Bossart and Dierauf, 1990). Her appetite was good until 26 July, when she became anorexic and passed loose feces containing flecks of necrotic mucosa. We observed congested mucous membranes and conjunctiva, blepharospasm, and reduced air movement over all lung fields. She had a severe neutrophilia with a left shift (102,000 white blood cells/mm³, 78% neutrophils, 10% immature band neutrophils), hypersegmented neutrophils, as well as elevated sodium (162 meq/l), chloride (114 meq/l), blood urea nitrogen (BUN) (65 mg/dl), gamma glutamyl transpeptidase (355 m/l), aspartate transaminase (AST) (562 m/l) and alanine transaminase (ALT) (397 m/l) levels. Despite treatment with 2500mg ceftriazone (Rocephin, Hoffmann-LaRoche Inc., Nutley, New Jersey) intramuscularly every 12 hr, 1g sucralfate (Carafate, Marion Merrell Dow, Kansas City, Missouri, USA) orally every 12 hr she had deteriorated by the following day when she was observed bleeding from the mouth and injection sites. Blood collected for coagulation assays had a low fibrinogen level (<15 mg/dl), prolonged ACT (90 sec), PT (>60 sec) and APTT (>120 sec), as well as the presence of FDP's (none on monoclonal test, positive at dilution 1:5 on polyclonal test); her platelet count was 585,000 per ml and antithrombin III value was 76%. A diagnosis of DIC was made. Heparin (Elkins-Sinn, Inc., Cheray Hill, New Jersey treatment of 15,000 I U intravenously in 5% dextrose plus 15,000 I.U. subcutaneously) was started. After 18 hr the animal had

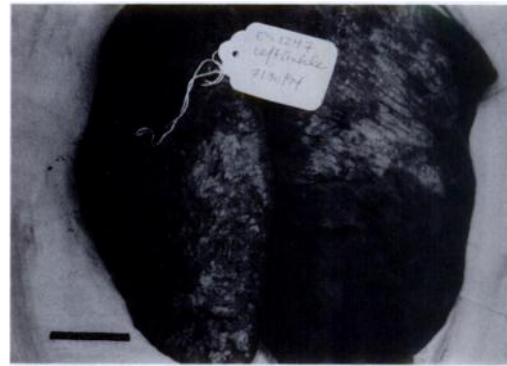


FIGURE 1. Hemorrhage into caudal half of right lung of an elephant seal. Bar = 10 cm.

further deteriorated, was comatose and bleeding persistently from the venipuncture site. She was then euthanized by intravenous administration of 20 ml pentobarbitone (Pentobarbital solution, Anthony Products, Arcadia, California) into the extradural intravertebral sinus.

On post mortem examination, free blood was observed in the nasopharynx, esophagus and gastrointestinal tract, and urine was red. A massive hemorrhage occupied the caudal half of the right lung (Fig. 1). Small sub-endocardial and subcutaneous hemorrhages were also present. Samples of lung, liver, kidney and intestine were cultured on blood agar with 5% added citrated sheep blood, and on MacConkey agar, incubated at 35 C then examined after 24 hr (Carter, 1973). Bacteria were identified using the API 20E System (Sherwood Medical, Plainview, New York, USA) and colony and biochemical characteristics (MacFaddin, 1980). *Pseudomonas aeruginosa* and *Corynebacterium* sp. were isolated from kidney, intestine, liver and lung. From the lung, *Escherichia coli*, *Enterococcus* sp. and a coagulase negative *Staphylococcus* were also isolated. Sections of all organs were fixed in 10% formalin, paraffin-embedded, cut into 4 to 6 μ m sections and stained with hematoxylin and eosin. Based on histologic examination, we observed suppurative interstitial pneumonia associated with severe

acute suppurative arteritis, diffuse alveolar hemorrhage and intra-alveolar and intra-arterial nematode larvae and adults. Morphology of intra-arterial nematodes resembled *Otostrongylus circumlitus*, that of intra-alveolar nematodes resembled *Parafilaroides* sp. (Delyamure, 1968). There was also suppurative epicarditis and myocarditis, with diffuse myocardial degeneration. Multifocal portal venous thrombosis was seen in the liver, with random hepatocellular necrosis and suppurative hepatitis. Multiple fibrin thrombi were recognizable within the liver and occasionally within alveolar capillaries. There was also enterocolitis, which, in the colon, was focally pyogranulomatous.

In this case, clinical signs, several laboratory values, necropsy and histologic findings of intravascular thrombosis and multifocal hemorrhages were consistent with DIC. The hemorrhagic diathesis, prolongation of PT and PTT and extremely low fibrinogen were evidence that a consumptive hypocoagulable state had been reached. Although a platelet count well within the normal range is inconsistent with DIC (Bick, 1994), little is known about the kinetics of platelets in pinnipeds. It is unusual for AT III levels to be within normal range during progression of fulminant DIC (Bick, 1994). This result, in combination with the platelet count, may be evidence that this animal was in a partially compensated state of DIC. The high AST and ALT are of note, as these liver enzymes are considered important non-specific indicators of DIC in man (Bick, 1994). The FDP's were only detected at 1:5 dilution, a level considered within the normal range for man and dog (Slappendel, 1988). Although elevated FDP's are not always found in DIC, poor cross-reactivity of the polyclonal antibody is another possible explanation for failure to detect higher levels of FDP's in this animal. Lack of cross-reactivity probably explains the inability to detect normal levels of FDP using the monoclonal antibody, which detects more restricted, often species specific,

protein sequences than polyclonal reagents.

Arteritis is a common finding in elephant seals stranded in central California, and, with sepsis, probably plays an important role in triggering DIC in this species. Intensive care of elephant seals is difficult, stressful to the animal, and expensive. The antemortem detection of DIC may help the clinician decide whether such treatment is warranted. This case exemplifies such detection in a northern elephant seal, and provides base-line coagulation values for this species which may prove to be useful diagnostic and prognostic tools.

LITERATURE CITED

- BICK, L. R. 1994. Disseminated intravascular coagulation. Objective criteria for diagnosis and management. *The Medical Clinics of North America* 78: 511-543.
- BOSSART, G. D., AND L. A. DIERAUF. 1990. Marine mammal clinical laboratory medicine, *In* Handbook of marine mammal medicine: Health, disease, and rehabilitation, L. A. Dierauf (ed.). CRC Press Inc. Boca Raton, Florida, pp. 1-52.
- CARTER, G. R. 1973. Diagnostic procedures in veterinary microbiology, 2nd ed. Charles C. Thomas, Springfield, Illinois, 362 pp.
- COLES, E. H. 1986. Veterinary clinical pathology. W.B. Saunders Company, Philadelphia, Pennsylvania, pp. 98-108.
- DELYAMURE, S. 1968. Helminthofauna of marine mammals (Ecology and phylogeny). Academy of Sciences of the USSR Laboratory of Helminthology. Israel program for scientific translations, U.S. Department of the Interior and the National Science Foundation, Washington D.C., Israel Program for Scientific Translation Information Services, Catalogue 1886 TT 67-51202, pp. 260-262.
- FELDMAN, B. F., E. J. CARROLL, AND N. C. JAIN. 1986. Coagulation and its disorders. *In* Schalm's veterinary hematology, 4th ed., N. C. Jain (ed.) Lea and Febiger, Philadelphia, Pennsylvania, pp. 388-430.
- FOSTER, J. B. T., A. DE NATALE, AND L. B. DOTTL. 1959. Determination of plasma fibrinogen by means of centrifugation after heating. *American Journal of Clinical Pathology* 31: 42.
- HOUGIE C. 1972a. The one-stage prothrombin time. *In* Hematology, W. J. Williams (ed.). McGraw-Hill, New York, New York, pp. 1403-1405.
- . 1972b. Recalcification time test and its modifications. *In* Hematology, W. J. Williams

- (ed.). McGraw-Hill, New York, New York, pp. 1400–1403.
- LE BOEUF, B. J., R. J. WHITING, AND R. F. GANTT. 1972. Perinatal behaviour of northern elephant seal females and their young. *Behaviour* 43: 121–156.
- MACFADDIN, J. F. 1980. Biochemical tests for the identification of medical bacteria. Williams and Wilkins, Baltimore, Maryland, 527 pp.
- MORSE, E. E., S. PANEK, AND R. MENGA. 1971. Automated fibrinogen determination. Modified clotting time. *American Journal of Clinical Pathology* 55: 671–676.
- SLAPPEDEL, R. J. 1988. Disseminated intravascular coagulation. *Veterinary Clinics of North America*, 18: 169–184.
- SOLBERG, H. E. 1981. Statistical treatment of collected reference values and determination of reference limits. *In* Reference values in laboratory medicine, R. Grosbeck and T. Glaston (eds.). John Wiley and Sons, New York, New York, pp. 93–205.

Received for publication 9 March 1995.