



Baylisascaris sp. Found in a Wild Northern Bobwhite (Colinus virginianus)

Authors: Williams, Christopher K., McKown, Richard D., Veatch, Johna K., and Applegate, Roger D.

Source: Journal of Wildlife Diseases, 33(1) : 158-160

Published By: Wildlife Disease Association

URL: <https://doi.org/10.7589/0090-3558-33.1.158>

BioOne Complete (complete.BioOne.org) is a full-text database of 200 subscribed and open-access titles in the biological, ecological, and environmental sciences published by nonprofit societies, associations, museums, institutions, and presses.

Your use of this PDF, the BioOne Complete website, and all posted and associated content indicates your acceptance of BioOne's Terms of Use, available at www.bioone.org/terms-of-use.

Usage of BioOne Complete content is strictly limited to personal, educational, and non - commercial use. Commercial inquiries or rights and permissions requests should be directed to the individual publisher as copyright holder.

BioOne sees sustainable scholarly publishing as an inherently collaborative enterprise connecting authors, nonprofit publishers, academic institutions, research libraries, and research funders in the common goal of maximizing access to critical research.

***Baylisascaris* sp. Found in a Wild Northern Bobwhite (*Colinus virginianus*)**

Christopher K. Williams,¹ Richard D. McKown,² Johna K. Veatch,³ and Roger D. Applegate,⁴ ¹ Department of Wildlife Ecology, University of Wisconsin, Russell Labs, 1630 Linden Drive, Madison, Wisconsin 53706-1598, USA; ² Department of Veterinary Pathobiology, The Texas Veterinary Medical Center, Texas A&M University, College Station, Texas 77843-4467, USA; ³ Central States Veterinary Pathology Service, 407 Westview Drive, Manhattan, Kansas 66502, USA; ⁴ Department of Wildlife and Parks, Research and Survey Section, P.O. Box 1525, Emporia, Kansas 66801-1525, USA

ABSTRACT: During a telemetry study conducted between 1993 and 1995 in east-central Kansas (USA) on northern bobwhite (*Colinus virginianus*) populations, a wild adult male quail was found with signs of disorientation and torticollis in August 1994 in Lyon County, Kansas. Based on histological and parasitological examination, it was determined that the bird was infected with larval nematodes of the genus *Baylisascaris* spp. This is the first known recorded case of *Baylisascaris* sp. in a wild game bird species.

Key words: Northern Bobwhite, *Colinus virginianus*, *Baylisascaris* sp., Kansas, histopathology, cerebrospinal nematodiasis.

Long-term population trends of the northern bobwhite (*Colinus virginianus*) have been declining over the last 30 yr (Church and Taylor, 1992). Based on breeding bird surveys (Droege and Sauer, 1990) and Christmas bird counts (Brennan and Jacobsen, 1992), there have been significant population declines of bobwhite (77%) in 31 states of the U.S. Declines have been most pronounced in the southeastern United States, the center of bobwhite geographic distribution (Brennan and Jacobsen, 1992). While indirect factors such as habitat alteration, land use changes, and succession most dramatically affect quail abundance (Roseberry and Klimstra, 1984), direct factors such as predation, hunting, environmental conditions, and disease also play a vital role in quail mortality.

On 12 August 1994, an adult male northern bobwhite was observed acting in an uncharacteristic manner on a county gravel road in southern Lyon County, Kansas, USA (38°17'N, 96°15'W). The bird was ataxic, had torticollis, and when disturbed its flight was erratic. The bird was

captured and kept at the Kansas Department of Wildlife and Parks, Research and Survey Section, Emporia, Kansas (KDWP). After 12 hrs an almost total loss of motor functions was observed.

The bird was subsequently transported to the Department of Veterinary Diagnostic Investigations at Kansas State University College of Veterinary Medicine, Manhattan, Kansas, where it was examined and necropsied. Grossly, no significant lesions were present. Portions of lung, liver, kidney, spleen, intestine, pancreas, proventriculus, ventriculus, skeletal muscle, heart, and one-half of the brain were collected and placed in 10% neutral buffered formalin. The other half of the brain was frozen. After fixation, the tissues were embedded in paraffin, sectioned at 5 µm, and stained with hematoxylin and eosin. A single linear area of malacia characterized by loss of normal architecture and moderate vacuolation of the parenchyma was present in the brainstem. Except for a mild infiltrate of gutter cells, there were no signs of inflammation in the brain sections examined. Lung sections had a focal granulomatous response centered around sections of a larval nematode. (Figs. 1, 2).

Since the area of malacia in the brain appeared to be a possible nematode migration track, further examination of the remaining portion of the brain was performed at the College of Veterinary Medicine, Department of Veterinary Pathobiology at The Texas A&M Veterinary Medical Center, College Station, Texas (USA). The remainder of the brain was teased apart in 0.85% saline, with the larger pieces further broken apart by agitation.

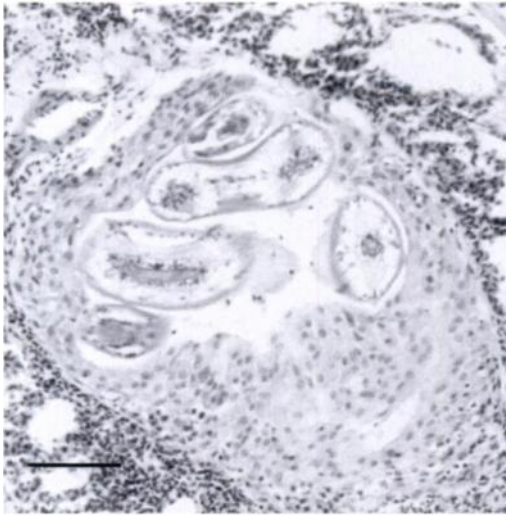


FIGURE 1. Focal granuloma in response to a *Baylisascaris* larva—lung, H&E stain. Bar = 100 μ m.

Using a dissecting microscope, the resulting sediment was then examined at 30 \times magnification. Any remaining pieces of tissue were examined as squash preparations at 100 \times magnification. This resulted in the recovery of a single nematode larvae. The larvae measured 1,595 μ m in length with a width at the base of the esophagus of 69.7 μ m. Other characteristics noted included a smoothly rounded anterior end and a capped and kinked appearance to the tail. Additionally, larval characteristics seen in the section of affected lung were also used for purpose of identification. The characters visible in this particular cut were prominent lateral alae as well as large triangular shaped excretory columns. When both gross morphological and histological characteristics were compared to those given by Bowman (1987), and identification of *Baylisascaris* sp. was made. The larva was deposited as an alcohol specimen in the United States National Helminthological Collection (Beltsville, Maryland 20705, USA) under Accession No. 85873.

With the exception of *Baylisascaris devosi*, the identification larvae beyond the generic level is impossible (Bowman, 1987). However in this case, with species

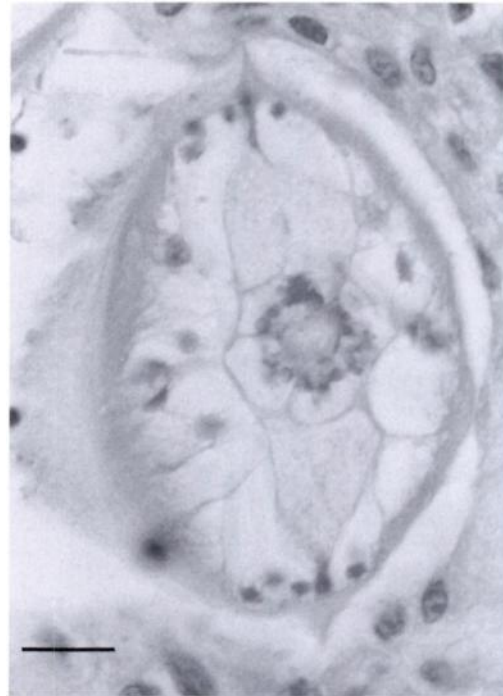


FIGURE 2. Higher magnification of *Baylisascaris* sp. larva showing characteristic large lateral alae and triangular shaped excretory columns. H&E stain. Bar = 25 μ m.

and habitat considerations taken into account (Bee et al., 1981), the most likely possibilities in this case would include *Baylisascaris procyonis* from the raccoon (*Procyon lotor*) or *Baylisascaris columnaris* from the striped skunk (*Mephitis mephitis*) or badger (*Taxidea taxus*).

Cerebrospinal nematodiasis has been documented in at least 13 game and non-game bird species (Kazacos and Boyce, 1989), including captive-reared northern bobwhite (Reed et al., 1981). However, *Baylisascaris* sp. infection has never been reported in wild northern bobwhite. In free-ranging birds it has been observed that ground feeders, such as mourning doves (*Zenaidura macroura*), rock doves (*Columba livia*), and American robins (*Turdus migratorius*), may feed on the undigested seeds found within raccoon feces, and in so doing could inadvertently ingest viable *Baylisascaris* spp. eggs (Evans and Tangredi, 1985). Though *Baylisascaris*

spp. infection has never been reported in wild northern bobwhite, it is understandable that as weather conditions become more adverse and food supplies dwindle, utilizing such seeds as a food source could possibly occur.

Raccoon and striped skunk population trends have been on the increase in Kansas for the last 20 yr, which may be due to decreased trapping pressure (Fox, 1995). With the subsequent increase in these fur-bearer populations, it is possible that there are increasing chances for northern bobwhite to become exposed to the eggs of *Baylisascaris* spp. Though we are reporting the death of a single wild bobwhite, it is possible that *Baylisascaris* spp. may be contributing to a much greater death loss. Rosene and Lay (1963) found that as most predators or scavengers quickly consume dead or dying quail, their remains are rarely seen in the field. Consequently, finding and identifying the cause of even a small number of dead or dying quail is reason to suspect a higher rate of mortality than may have been assumed. As northern bobwhite populations continue to decline, *Baylisascaris* spp. infection needs to be considered as one of the potential threats to population viability.

We thank M. Paradise, B. Ast, and K. Church. This research was funded by Kansas Department of Wildlife and Parks Federal Aid to Wildlife Restoration Project W39R.

LITERATURE CITED

- BEE, J. W., G. E. GLASS, R. S. HOFFMAN, AND R. R. PATTERSON. 1981. Mammals of Kansas: Museum of Natural History Public Education Series No. 7. University of Kansas, Lawrence, Kansas, 300 p.
- BOWMAN, D. D. 1987. Diagnostic morphology of four larval ascaridoid nematodes that may cause visceral larva migrans: *Toxascaris leonina*, *Baylisascaris procyonis*, *Lagochilascaris sprenti*, and *Hexametra leidyi*. The Journal of Parasitology 73: 1198–1215.
- BRENNAN, L. A., AND H. A. JACOBSEN. 1992. Northern bobwhite (*Colinus virginianus*) hunter use of public wildlife areas: The need for proactive management. Gibier Faune Sauvage 9: 847–858.
- CHURCH, K. E., AND J. S. TAYLOR. 1992. Management and research of northern bobwhite in North America: A review. Gibier Faune Sauvage 9: 787–796.
- DROEGE, S., AND J. R. SAUER. 1990. Northern bobwhite, gray partridge, and ring-necked pheasant population trends (1966–88) from the North American Breeding Bird Survey. In K. E. Church, R. E. Warner, and S. J. Brady (editors). Perdix V: Gray partridge and ring-necked pheasant workshop. Kansas Department of Wildlife and Parks, Emporia, Kansas, pp. 2–20.
- EVANS, R. H., AND B. TANGREDI. 1985. Cerebrospinal nematodiasis in free-ranging birds. Journal of the American Veterinary Medical Association 183: 1089–1090.
- FOX, L. B. 1995. Kansas Department of Wildlife and Parks 1995 fur-bearer report. Unpublished. Kansas Department of Wildlife and Parks, Emporia, Kansas, 5 pp.
- KAZACOS, K. R., AND W. M. BOYCE. 1989. *Baylisascaris* larva migrans. Journal of the American Veterinary Medical Association 195: 894–903.
- REED, W. M., K. R. KAZACOS, A. S. DHILLON, R. W. WINTERFIELD, AND H. L. THACKER. 1981. Cerebrospinal nematodiasis in bobwhite quail. Avian Diseases 25: 1039–1046.
- ROSEBERRY, J. L., AND W. D. KLIMSTRA. 1984. Population ecology of the bobwhite. Southern Illinois University Press, Carbondale, Illinois, 259 pp.
- ROSENE, W., AND D. W. LAY. 1963. Disappearance and visibility of quail remains. The Journal of Wildlife Management 27: 139–142.

Received for Publication 10 January 1996.