



EXPERIMENTAL ADENOVIRUS HEMORRHAGIC DISEASE IN YEARLING BLACK-TAILED DEER

Authors: Woods, Leslie W., Hanley, Richard S., Chiu, Philip H. W., Burd, Matthew, Nordhausen, Robert W., et al.

Source: Journal of Wildlife Diseases, 33(4) : 801-811

Published By: Wildlife Disease Association

URL: <https://doi.org/10.7589/0090-3558-33.4.801>

BioOne Complete (complete.BioOne.org) is a full-text database of 200 subscribed and open-access titles in the biological, ecological, and environmental sciences published by nonprofit societies, associations, museums, institutions, and presses.

Your use of this PDF, the BioOne Complete website, and all posted and associated content indicates your acceptance of BioOne's Terms of Use, available at www.bioone.org/terms-of-use.

Usage of BioOne Complete content is strictly limited to personal, educational, and non - commercial use. Commercial inquiries or rights and permissions requests should be directed to the individual publisher as copyright holder.

BioOne sees sustainable scholarly publishing as an inherently collaborative enterprise connecting authors, nonprofit publishers, academic institutions, research libraries, and research funders in the common goal of maximizing access to critical research.

EXPERIMENTAL ADENOVIRUS HEMORRHAGIC DISEASE IN YEARLING BLACK-TAILED DEER

Leslie W. Woods,¹ Richard S. Hanley,¹ Philip H. W. Chiu,¹ Matthew Burd,¹
Robert W. Nordhausen,¹ Michelle H. Stillian,¹ and Pamela K. Swift²

¹ California Veterinary Diagnostic Laboratory System, School of Veterinary Medicine,
University of California, Davis, California 95617, USA

² The Wildlife Investigations Laboratory, California Department of Fish and Game,
Rancho Cordova, California 95670, USA

ABSTRACT: An apparently novel adenovirus was associated with an epizootic of hemorrhagic disease that is believed to have killed thousands of mule deer (*Odocoileus hemionus*) in California (USA) during 1993–1994. A systemic vasculitis with pulmonary edema and hemorrhagic enteropathy or a localized vasculitis associated with necrotizing stomatitis/pharyngitis/glossitis or osteomyelitis of the jaw were common necropsy findings in animals that died during this epizootic. Six black-tailed yearling deer (*O. hemionus columbianus*) were inoculated with purified adenovirus isolated from a black-tailed fawn that died of acute adenovirus hemorrhagic disease during the epizootic. Three of six inoculated deer also received intramuscular injections of dexamethasone sodium phosphate every 3 days during the study. Eight days post-inoculation, one deer (without dexamethasone) developed bloody diarrhea and died. Necropsy and histopathologic findings were identical to lesions in free-ranging animals that died of the natural disease. Hemorrhagic enteropathy and pulmonary edema were the significant necropsy findings and there was microscopic vascular damage and endothelial intranuclear inclusion bodies in the vessels of the intestines and lungs. Adenovirus was identified in necrotic endothelial cells in the lungs by fluorescent antibody staining, immunohistochemistry and by transmission electron microscopy. Adenovirus was reisolated from tissues of the animal that died of experimental adenovirus hemorrhagic disease. Similar gross and microscopic lesions were absent in four of six adenovirus-inoculated deer and in the negative control animal which were necropsied at variable intervals during the 14 wk study. One deer was inoculated with purified adenovirus a second time, 12 wk after the first inoculation. Fifteen days after the second inoculation, this deer developed severe ulceration of the tongue, pharynx and rumen and necrotizing osteomyelitis of the mandible which was associated with vasculitis and thrombosis of adjacent large vessels and endothelial intranuclear inclusions. Transmission electron microscopy demonstrated adenovirus within the nuclei of vascular cells and immunohistochemistry demonstrated adenovirus antigen within tonsillar epithelium and in rare vessels.

Key words: Adenovirus, experimental study, hemorrhagic disease, vasculitis, mule deer, *Odocoileus hemionus*.

INTRODUCTION

We previously described an epizootic of hemorrhagic disease in two subspecies of mule deer (*Odocoileus hemionus columbianus* and *O. hemionus hemionus*) that was associated with a newly recognized adenovirus (ADV; Woods et al., 1996). Thousands of deer in over 17 counties of California (USA) were believed to have died between August 1993 and April 1994. Pulmonary edema and hemorrhagic enteropathy were significant necropsy findings in animals which died of acute systemic disease. Vasculitis associated with endothelial intranuclear inclusion bodies was present in numerous organs but was most con-

sistently present in the lungs and alimentary tract. Abscesses and ulceration in the mouth and in the forestomachs associated with localized vasculitis were seen in other deer without systemic vasculitis. These animals were emaciated with severe depletion and serous atrophy of fat consistent with death due to starvation.

Adenovirus was demonstrated in necrotic endothelial cells in the lungs, esophagus and ileum by fluorescent antibody staining, immunohistochemistry and/or transmission electron microscopy in 11 deer that died during the epizootic. Adenovirus was isolated in cell culture from the lungs of a fawn (121°00'N, 39°20'W) with systemic vasculitis that died during

the epizootic. In this same report, ADV was identified in endothelial cells by immunohistochemistry and transmission electron microscopy in archived tissues of two fawns from two separate herds which experienced heavy mortality in 1987 attributed to a hemorrhagic disease. At the time, the etiologies suggested in both cases were presumptive bluetongue (BT) virus or epizootic hemorrhagic disease (EHD) virus even though neither virus was isolated in embryonated chicken eggs or cell cultures. Necropsy changes seen in animals which die of adenovirus hemorrhagic disease (AHD) are similar to those described in deer infected with BT or EHD viruses, and these diseases must be differentiated (Karstad and Trainer, 1967; Hoff and Trainer, 1981; Jessup et al., 1984; Woods et al., 1996).

The purpose of this study was (1) to determine if purified ADV isolated from tissues of a deer that died of ADH during the California epizootic would produce clinical signs, gross lesions, and microscopic changes similar to those that were seen in the free-ranging animals that died of natural AHD, and (2) to subsequently re-isolate ADV. Experimental inoculation studies with purified ADV are necessary to establish that this newly recognized ADV is a cause of hemorrhagic disease in black-tailed deer.

MATERIALS AND METHODS

Fawns

Seven neonatal black-tailed deer orphaned fawns were collected from counties without rehabilitation centers and raised until they were yearlings. These fawns would have otherwise been euthanatized under new regulations set forth by the California Department of Fish and Game (Rancho Cordova, California, USA) that restricts transport of fawns between counties in an effort to prevent the spread of disease. Fawns were raised on goat milk with kid replacer (Purina Mills, Inc., St. Louis, Missouri, USA). Calf manna (Farmers Warehouse Co., Keys, California, USA) and alfalfa hay were available ad libitum. Fawns were weaned at 6 mo of age and fed oat and alfalfa hay and live-

stock pelleted ration with decreasing quantities of calf manna. Water was available free choice.

Viral inoculum

Adenovirus was isolated in black-tailed deer pulmonary artery endothelial cells (BTDPAE; Woods, Davis, California, USA) from lung homogenates from a fawn (Yuba county, California, USA) that died during the 1993 epizootic of AHD (Woods et al., 1996). Adenovirus was identified in cell culture by electron microscopic examination of negatively stained preparations after incubating for 2 wk. Virions were icosahedral, 77.6 to 79.6 nm in diameter and had triangular facets consistent with members of the Adenoviridae (Horwitz, 1990; Fenner et al., 1993). Cytopathologic effects were not evident in BTDPAE cells. Flasks were freeze/thawed and centrifuged at low speed to remove cellular debris and the supernatant was centrifuged for 60 min at $248,000 \times G$. Sediment was diluted in Dulbecco's minimum essential medium (MEM; Gibco, Life Technologies, Inc., Grand Island, New York, USA) and placed over a linear cesium chloride (CsCl) gradient, 1.3–1.46 mg/cm³, in phosphate buffered saline (PBS), pH 7.4, and centrifuged for 18 hr at $290,000 \times G$. A single band consistent with the buoyant density of Adenoviridae in CsCl (1.34 mg/cm³; Horwitz, 1990) was collected, diluted in PBS (pH 7.4) and dialyzed overnight in cold PBS (pH 7.4). Inoculum was diluted 1:10, 1:100 and 1:1000 and inoculated onto a monolayer of BTDPAE cells grown to confluence on coverslips in 24-well plates. Inoculated cells were incubated in Dulbecco's MEM with 10% fetal bovine serum (FBS; Sigma Chemical Co., St. Louis, Missouri, USA) for 14 days at 37 C. Coverslips were stained with fluorescein-isothiocyanate-labeled antibody to bovine adenovirus type 5 (BAV-5; American BioResearch, Seymour, Tennessee, USA) and examined using an ultraviolet microscope. Fluorescein-labeled cells were counted and the infectious titer was determined (1×10^2 TCID₅₀/ml). This preparation was used as inoculum for the experimental inoculation study.

Inoculation study

Six yearling deer (three males and three females) were randomly divided into two groups of three animals and housed in separate isolation rooms. Both groups (group A and B) were inoculated intravenously, intratracheally and through the mucous membranes of the eyes and nose with 2×10^2 TCID₅₀/ml purified ADV diluted in PBS (pH 7.4). Three days prior to inoculation with virus, and every 3 days for 4 wk, deer in group A received intramuscular

injections of dexamethasone sodium phosphate (Vedco, Inc., St. Joseph, Missouri, USA; 0.5 mg/kg). The seventh deer (male, negative control) was housed in a separate isolation room and was inoculated by similar routes with 2 ml of PBS. Pre- and post-inoculation serum samples (2.5 wk apart) were tested for antibodies to EHD virus and BT virus using the agar gel immunodiffusion (AGID) test (Veterinary Diagnostic Technology, Wheat Ridge, Colorado, USA) and the competitive ELISA (Veterinary Diagnostic Technology, Wheat Ridge, Colorado, USA), respectively (Patton et al., 1994). Animals were immobilized with xylazine (Miles Laboratory, Shawnee, Kansas, USA; 1 mg/kg) and bled every 3 days for 4 wk for serum collection and complete blood counts. Yohimbine (Lloyd Laboratory, Shenandoah, Iowa, USA; 0.25 mg/kg) was used as a reversal agent. At 12 wk post-inoculation, one asymptomatic male deer from group A was reinoculated with purified ADV through the nose, eyes, mouth and trachea. All animals were euthanatized with euthanasia solution (Schering-Plough Animal Health Corp., Kenilworth, New Jersey, USA) when clinical signs appeared or blood values indicated a systemic inflammatory response or at variable intervals during the period 14 wk post-inoculation (PI; one deer 8 days PI, two at 3 wk PI, two at 4 wk PI, one at 11 wk PI and one reinoculated deer at 14 wk PI). Complete necropsies were performed on all animals. Fifty-five identical tissue sections of major organ systems were taken from each animal during necropsy, immersed in 10% buffered neutral formalin and processed routinely for histologic examination. Large and small intestinal contents from all animals were suspended in distilled water, sedimented by centrifugation, negatively stained with 2% phosphotungstate and examined with a Zeiss 10 C electron microscope (Oberkochen, Germany). Specimens of lung, ileum and oral lesions (2×2 mm) from affected deer, unaffected inoculated deer and the negative control deer were immersion-fixed in modified Karnovsky's solution (Nowell et al., 1972), postfixed in 1% osmium tetroxide in 0.1 M sodium cacodylate and embedded in Med-cast resin (Ted Pella, Redding, California, USA). Ultrathin sections (70–90 nm) were stained with uranyl acetate and lead citrate and examined with a Zeiss 10 C electron microscope.

Cryostat sections of lung (5 μ m) from affected deer were fixed in acetone/methanol (3:1) for 20 min and stained with bovine anti-BAV-5 fluorescein-isothiocyanate-labeled antibody. In addition, conventional virus isolation in specific-pathogen-free embryonated chicken eggs and BT virus-specific polymerase chain re-

action (PCR; Akita et al., 1993) were performed on spleen, bone marrow, lung, and blood from animals that developed acute AHD.

Immunohistochemistry

A streptavidin-biotin-peroxidase method was used for immunohistochemical staining (Cartun and Pedersen, 1989). Tissues examined from the animals with systemic disease included sections from all levels of the alimentary and respiratory tracts, sections from the nervous system, endocrine system, hemolymphatic system, cardiovascular system, urogenital system and muscular system. The upper alimentary tract (oral pharynx, esophagus), cranial lymph nodes (retropharyngeal, mandibular, cranial and caudal cervical lymph nodes) and lungs were examined from the negative control and four inoculated unaffected animals. Several sections of upper alimentary tract (including lip and tongue lesions) and lungs were examined from the animal with localized infection. Paraffin-embedded tissue sections (2 to 3 μ m) were applied to Probe-on-Plus microscope slides (Fisher Scientific, Pittsburgh, Pennsylvania, USA) and further processed using a MicroProbe Staining System (Fisher Scientific, Pittsburgh, Pennsylvania, USA). The sections were deparaffinized in xylene, dehydrated to absolute ethanol and incubated with 3% hydrogen peroxide in absolute methanol for 10 min at room temperature to quench endogenous peroxidase activity. Sections were enzyme-digested for 15 min at 37 C with prewarmed 0.4% pepsin (Sigma Chemical Co., St. Louis, Missouri, USA) in 0.01 N HCl. Nonspecific background staining was blocked by incubating the sections for 30 min at room temperature with 10% heat-inactivated normal goat serum, diluted in PBS-BRIJ 35 (Fisher Scientific, Pittsburgh, Pennsylvania, USA), a detergent solution containing 0.075% BRIJ diluted in PBS (pH 7.4). Polyclonal antisera against BAV-5 (American BioResearch, Seymour, Tennessee, USA) was applied at a 1:4000 dilution overnight at 4 C. Following this incubation and each subsequent incubation, the sections were rinsed 10 times in PBS-BRIJ 35. The sections were then incubated for 60 min at room temperature with biotinylated goat anti-bovine IgG (Kirkegaard and Perry, Gaithersburg, Maryland, USA) diluted 1:500 in PBS-BRIJ, followed by incubation for 60 min at room temperature with the peroxidase-conjugated streptavidin (Jackson ImmunoResearch, West Grove, Pennsylvania, USA) diluted 1:1000 in PBS (pH 7.4). Finally, the sections were developed with aminoethylcarbazole (Dako, Carpinteria, California, USA), rinsed in tap water, counterstained with Mayer's hematox-

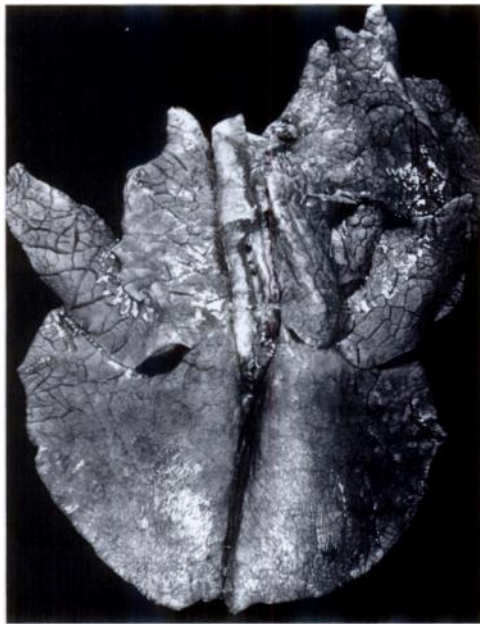

FIGURE 1. Lungs of a black-tailed deer (yearling) with experimental systemic adenovirus infection. Pulmonary edema is most prominent in the cranial, middle and anterior portion of the caudal lung lobes. Note the wide separation of lobules by interlobular septal edema.

mlin. and mounted using Crystal/mount (Bio-medex, Foster City, California, USA). Formalin-fixed lung sections from a deer infected with ADV were used as positive controls; normal bovine serum (Jackson ImmunoResearch, West Grove, Pennsylvania, USA) diluted 1:4000 in PBS-BRIJ 35 was substituted for the primary antibody as a negative control.

Virus isolation

Lung homogenates (10% suspension in MEM with antibiotics) from an affected deer, that died 8 days after inoculation with ADV, were inoculated onto BTDPAE cells in Dulbecco's MEM with 10% FBS. Cultures were examined daily for cytopathic effect. Tissue culture flasks were frozen at -70°C 2 wk PI, thawed at room temperature and filtered through a series of syringe filters (5.0 to 0.2 μm), and the ultrafiltrate was centrifuged at $248,000 \times G$. The pellet was resuspended in distilled water, applied to polyvinyl formal coated copper grids and stained with 2% phosphotungstate. Preparations were examined with a Zeiss 10 C transmission electron microscope.

RESULTS

Clinical signs

One female yearling deer in group B (without dexamethasone) died within 9 hr of developing clinical signs of hemorrhagic disease (8 days PI with purified ADV). The animal appeared normal the previous night at 10:00 P.M. By 6:00 A.M. the next morning, the animal was lethargic, in sternal recumbency and died 1 hr later. The perineum of this animal was stained with dark red/black feces and there was bloody fecal material on the floor of the room.

A male deer in group A (dexamethasone) that was reinoculated with purified ADV 12 wk after the first inoculation with ADV, became lethargic and developed a swollen muzzle 15 days after the second inoculation. This deer was asymptomatic during the period between the first and second inoculation and this was the only deer in this study to be inoculated with virus twice.

Necropsy

Pulmonary edema and intestinal luminal blood were seen during necropsy of the first animal that developed acute AHD in group B. Lobules in the cranial, middle, cranial portion of the caudal lung lobes and hilus of the accessory lung lobe were separated by severe interlobular septal edema (Fig. 1). The small and large intestines contained frank blood (Fig. 2). The left ventricle of the heart had suffusion hemorrhages on the endocardium. Caudal cervical lymph nodes were enlarged, purple and wet. This yearling had twin fetuses which were 18 cm long with tactile hairs on the muzzles but no torso hairs.

In the animal that was inoculated twice with ADV, there was a well-delineated zone of necrosis characterized by pale, friable soft tissue at the tip of the mandible that extended into the bone (Fig. 3). Teeth in this necrotic region were loose or absent. There were bilateral abscesses (1.5 to 3 cm in diameter) in the pharynx. The abscess on the right side extended into the deep retropharyngeal tissue. The middle

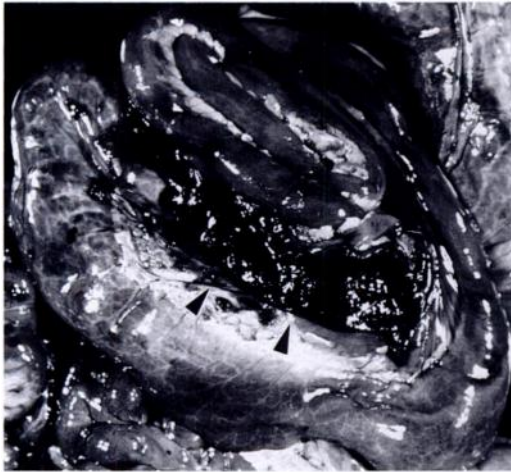


FIGURE 2. Spiral colon of a black-tailed deer with experimental systemic adenovirus infection. The lumen of the spiral colon has been opened and hemorrhagic contents are exposed (arrows).

portion of the dorsal aspect of the tongue had a large round (1.5 cm in diameter) deep ulcer. Cranial lymph nodes (retropharyngeal, mandibular, parotid and cranial cervical lymph nodes) were swollen, wet and purple. The rumenal mucosa had two large round (2 cm in diameter) necrotic foci with crateriform centers. The remaining gastrointestinal tract and all other organ systems examined were unremarkable.

None of the other inoculated deer or the control deer had changes consistent with systemic AHD or ulceration/abscesses in the upper alimentary tract. With the exception of one deer with aspiration pneumonia, there were no significant necropsy findings in the remaining deer.

Histopathology

Microscopic changes in the animal from group B with systemic AHD were similar in the cranial, middle, caudal and accessory lung lobes. There was marked expansion of the interlobular septa and pleura by edema and multifocal hemorrhage. Endothelial cells of the veins, venules, capillaries, arteries, and arterioles of the lungs were hypertrophic and sometimes had indistinct eosinophilic or amphophilic intra-

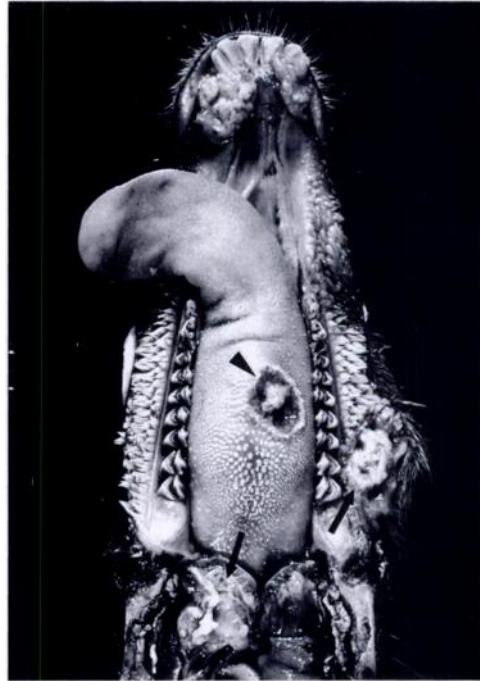


FIGURE 3. Mandible of a black-tailed deer with experimental adenovirus infection. The dorsal surface of the tongue has a large, deep ulcer (black arrowhead). There is necrosis at the tip of the mandible (open arrow) which extends into the bone and there is necrosis of the buccal mucosa and pharynx (solid black arrows).

nuclear inclusion bodies. There was vascular margination of leukocytes, disruption of the tunica intima by leukocytes (Fig. 4) and fibrinoid necrosis in the tunica media of some vessels. Sections of small and large intestine had dense luminal erythrocytes and moderate diffuse hemorrhage in the lamina propria of the mucosa (Fig. 5). Vascular changes in sections of intestine were similar to those described in the lungs (Fig. 5, Inset). Lymphoid patches in the small intestines showed marked depletion of lymphocytes. Follicular lymphocyte necrosis and depletion were seen in the cranial and caudal cervical, retropharyngeal and mandibular lymph nodes. Endothelial intranuclear inclusions and degenerative vascular changes were seen less frequently in the nasal mucosa, oral pharynx, nasal pharynx, cranial lymph nodes (retropharyngeal, mandibular, cranial and caudal

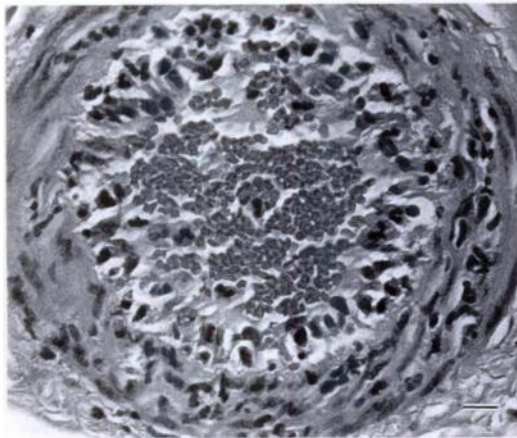


FIGURE 4. A pulmonary vessel of a black-tailed deer with experimental adenovirus infection. Endothelial cells are hypertrophic and there are inflammatory cell infiltrates in the tunica intima extending into the tunica media. H&E. Bar = 50 μ m.

cervical lymph nodes), esophagus, forestomachs, pulmonary artery, thymus, pancreas, brain, uterus, kidneys, spleen, urinary bladder, skeletal muscle, and trachea. There were no microscopic changes in the fetuses.

Necrotic lesions of the rumen, tongue, lip and pharynx from the reinoculated animal from group A had distinct well-delineated ulcers extending deep into the submucosa. Diffuse dense accumulations of inflammatory cells consisting of macrophages and neutrophils (many degenerated) separated viable from nonviable tissue. Decreasing numbers of mixed mononuclear inflammatory cells admixed with fibroblasts extended peripherally from the ulcers. Some veins and variably-sized arteries and arterioles in the adjacent viable tissue had neutrophilic inflammatory cell infiltrates in the tunica media and tunica intima and endothelial cells were hypertrophic. Other vessels had fibrinoid necrosis in the tunica media. Vascular lumina had margined neutrophils and fibrin and some vessels had fibrinocellular luminal thrombi. Indistinct endothelial intranuclear inclusions were rarely seen in vessels adjacent to the necrotic regions in the lip, pharynx and tongue. Cranial lymph nodes

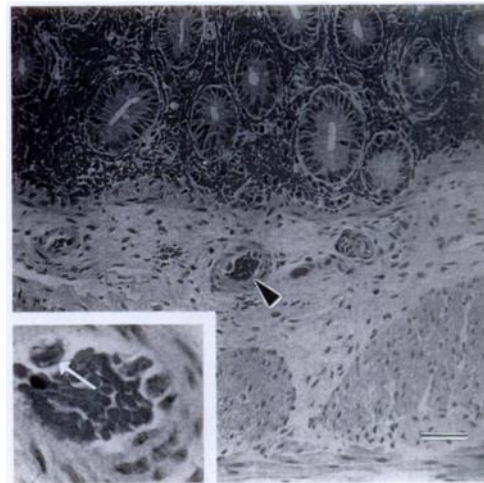


FIGURE 5. Small intestines of a black-tailed deer with experimental adenovirus infection. Note diffuse hemorrhage in the lamina propria of the mucosa. Endothelial cell in submucosal vessel (black arrowhead) is hypertrophic. H&E. Bar = 100 μ m. Inset. Higher magnification of vessel shown by arrowhead. Hypertrophic endothelial cell has intranuclear inclusion (white arrow). H&E. Bar = 20 μ m.

were hypercellular with neutrophils, macrophages and plasma cells filling the subcapsular, cortical and medullary sinuses. The vascular network of the lungs had luminal neutrophils and a few vessels had fibrin thrombi, but vasculitis, endothelial hypertrophy, endothelial necrosis and intranuclear inclusion bodies were not present in the lungs or other organs examined, aside from those mentioned previously.

In the remaining deer, one deer had microscopic changes in the lungs consistent with aspiration pneumonia and another had a mild, diffuse superficial rumenitis. There were no vascular changes in tissues of these two deer or in tissues of the other asymptomatic deer examined in which there were no significant necropsy findings.

Electron microscopy

Viruses were not identified in negatively-stained preparations of small and large intestinal contents from the seven animals that were examined using an electron microscope. Transmission electron micro-

scopic examination of Karnovsky's-immersed sections of ileum and lung from the deer with acute AHD demonstrated variable degenerative changes in endothelial cells ranging from swelling of endoplasmic reticulum and mitochondria to more severe changes such as fragmentation of the nuclei. Some endothelial cell nuclei had paracrystalline arrays or loosely dispersed viral nucleocapsids (68 to 72 nm in diameter) with central electron-dense cores (Fig. 6). Needle-like crystalline lattices of variable length were present within nuclei. In the deer with localized infection, rare adenoviral nucleocapsids were seen in vascular cells (smooth muscle cells) in the lip. Neither ADV nor endothelial changes were detected in lungs and ileum from the unaffected deer.

Immunohistochemistry

Adenovirus was demonstrated by immunohistochemical staining in the nuclei of endothelial cells lining arteries, arterioles, veins, venules and less often, capillaries in the deer with systemic AHD from group B. Organs in which endothelium was most heavily infected with ADV, as demonstrated by large numbers of vessels with heavy staining of the endothelium included the lungs, thymus, alimentary tract, cranial lymph nodes (retropharyngeal, mandibular, parotid, cranial and caudal cervical lymph nodes), trachea, pulmonary artery, placenta, and uterus. In the lungs, endothelial cells lining large- and medium-sized vessels, and small vessels (including capillaries) surrounding bronchi were most frequently stained. Endothelium lining capillaries in the interalveolar septa rarely stained. Endothelium in vessels of the kidneys, brain, urinary bladder, liver, spleen, and remaining lymph nodes less frequently stained. Fetal liver, lungs, kidneys, brain, thymus, and heart did not stain.

Immunohistochemistry of the lip and tonsil of the deer with oral and forestomach lesions demonstrated staining in the tonsillar epithelium, rare leukocytes and rare endothelial cells. Vessels in the lungs,

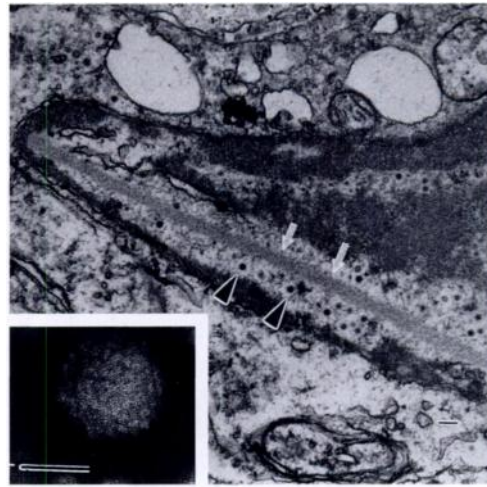


FIGURE 6. Lung of a black-tailed deer with systemic adenovirus infection. Transmission electron photomicrograph shows degenerated endothelial cell with adenovirus (black arrowheads) in the nucleus. Note needle-like array (white arrows). Endoplasmic reticulum and mitochondria in the cytoplasm are dilated and swollen. Lead citrate and uranyl acetate. Bar = 200 nm. Inset: Negatively-stained preparation of adenovirus isolated in black-tailed deer pulmonary artery endothelial cells from lung homogenates of deer with experimental systemic adenovirus infection. Phosphotungstate. Bar = 50 nm.

oral pharynx, and cranial lymph nodes did not stain in four of the inoculated unaffected animals.

In the deer from group B with systemic AHD, staining with the fluorescein-isothiocyanate-labeled antibody directed against BAV-5 was most concentrated in endothelial cells lining large and medium arteries and veins and less frequent, the endothelium lining smaller vessels (Fig. 7). Staining was not apparent in fetal tissues.

Bacteriology and complete blood counts

Blood values of the deer that died of systemic AHD were within normal ranges. Just prior to euthanasia, the white blood cell count of the deer with localized ADV infection was greater than 26,000/ μ l with 96% neutrophils. Blood cell counts in this same deer were unremarkable during the 4 wk after the first inoculation except for dexamethasone-induced lymphopenia. Except for one animal which developed as-

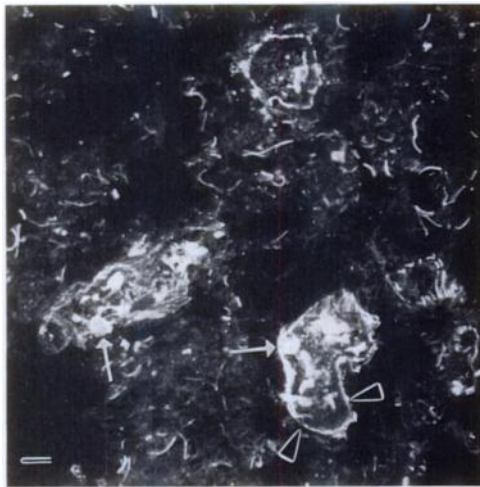


FIGURE 7. Lung of a black-tailed deer with experimental systemic adenovirus infection. In this black and white photomicrograph, endothelial nuclei reacting positively with BAV-5 fluorescein-labeled antibody appear white (white arrows). The color of the positive reaction was actually apple green. Black arrowheads show fine, white elastic fibers which have nonspecifically reacted with Evan's Blue counterstain and were actually orange in color. Ultraviolet light. Bar = 50 μ m.

piration pneumonia, none of the other animals had abnormal blood differential counts (except for the dexamethasone-induced lymphopenia). *Actinomyces pyogenes*, *Prevotella* sp., and *Peptostreptococcus anaerobius* were isolated from the necrotic lesion in the lip from the animal in group A with localized ADV infection.

Pre- and post-inoculation serum samples from all seven deer were negative for antibody to BT virus and EHD virus. Bluetongue virus was not isolated from tissues of the animal with systemic AHD, nor was BT virus detected in blood, spleen, bone marrow and lung from the affected animal in group B by PCR.

Virus isolation

Cytopathic effects were not seen in cell culture examined daily. Adenovirus was reisolated from lung homogenates of the deer with experimental systemic AHD in BTDPAE cells after incubation for 2 wk. Transmission electron microscopic exami-

nation of negatively-stained cell culture preparations demonstrated virions that were icosahedral, 77 to 80 nm in diameter and had triangular facets (Fig. 6, Inset).

DISCUSSION

Results of this study clearly demonstrate that, in black-tailed deer, ADV can cause a systemic vasculitis with gross changes similar to hemorrhagic disease caused by BT and EHD viruses. Gradient purification of the ADV showed that this adenovirus is solely capable of reproducing the gross and microscopic lesions seen in free-ranging animals that died of apparent natural AHD. The ADV was identified, using transmission electron microscopy, in the nuclei of endothelial cells that were intimately associated with the lesions. In addition, ADV antigen was detected in vascular endothelium by both immunofluorescent antibody staining and immunoperoxidase staining. Finally, ADV was reisolated in cell culture from tissues of the deer that died of the experimentally-induced systemic AHD, thus fulfilling Koch's postulates.

Mortality was high during the epizootic of AHD in 1993, and it was speculated that lack of a competent immune system, either due to immunosuppression or age-related underdeveloped humoral and cellular immunity, may have been important in the outcome of infection in deer. Immunosuppression is a significant factor in fatal infections due to ADV in many species (Fenner et al., 1993). Natural immunosuppression has been associated with environmental stresses (Trindle et al., 1978) or infection with some infectious agents. Environmental stress attributed to drought was not determined to be a significant factor affecting deer during the 1993 epizootic. Precipitation was above average the previous winter and ended a 6 yr drought in California. Animals necropsied and diagnosed with systemic AHD were well-fleshed. In addition, animals came from different counties with different environmental conditions. Coinfection

of the ADV with an immunosuppressive agent, which could have been highly prevalent during the epizootic, is another potential explanation for the high mortality that occurred in ADV-infected deer. To simulate natural immunosuppression, half of the ADV-inoculated animals received intramuscular injections of dexamethasone. Adenovirus hemorrhagic disease developed in an animal that did not receive dexamethasone. This animal was pregnant, however and this may have affected susceptibility to disease. Blood profiles and blood smears were normal in the affected animal and in the other two animals which did not receive the dexamethasone, whereas lymphopenia developed in animals which received the dexamethasone.

Age-related underdeveloped humoral and cellular immunity may be a significant factor in susceptibility to AHD. Thirteen mule deer were confirmed to have systemic AHD during the epizootic and were representative of numerous herds throughout California experiencing high mortality. All were fawns less than 6-mo-old except for one juvenile and one adult. This experimental inoculation study was delayed several times. Animals were yearlings by the time the experimental study commenced. Two of six animals inoculated with ADV developed clinical disease. One animal was pregnant and the other received dexamethasone. Information obtained from this study and the natural outbreak suggest that fawns may be more susceptible to infection than yearlings or adults.

The animal that developed lesions localized to the upper alimentary tract after a second inoculation with ADV received dexamethasone 3 days prior to, and every 3 days for 4 wk after the first inoculation with ADV. Lymphopenia was the only abnormal blood parameter during the 4 wk after inoculation. Fifteen days after the second virus inoculation the animal developed severe oral ulcers that were similar to those that occurred in a subgroup of animals that died of natural disease during the 1993 epizootic in California. Adenovi-

ruses are typically potent antigens and antibodies provide protection against homologous strains of ADV (Belak, 1990). Dexamethasone may have interfered with antibody production in this deer after the first inoculation with ADV. Humoral immunity is inhibited by glucocorticoid suppression of corticoid sensitive B and T lymphocytes (Trindle et al., 1978). This animal may have responded to the second inoculation as if its immune system was naive to this strain of ADV. The initial ADV inoculation may have, on the other hand, stimulated production of low levels of antibody. Adenovirus-specific antibody may have restricting localization of the virus to the upper alimentary tract in the animal inoculated twice. Future development of an ELISA test will help to determine the importance of antibody with regard to systemic and localized infections.

The endotheliotropic nature of this strain of adenovirus is similar to BAV-10 (Smyth et al., 1996), infectious canine hepatitis virus (Kelly, 1993) and a recently reported porcine adenovirus (Tang et al., 1995). Antibody against BAV-5 was used successfully for both immunofluorescence and immunoperoxidase staining to detect virus in the tissues of infected deer, indicating the deer ADV is antigenically related to BAV-5. Further serologic and molecular studies will be needed to determine the precise relationship of the deer ADV to BAV-5.

With the hemorrhagic form of this adenoviral disease, the virus most consistently infects endothelial cells in the lungs and intestines causing vascular damage with resulting pulmonary edema and hemorrhagic enteropathy. Disseminated intravascular coagulopathy (DIC) has been shown to contribute to the pathophysiology of hemorrhagic disease in white-tailed deer infected with BT virus (Howerth et al., 1988) and EHD virus (Fletcher and Karstad, 1971). Endothelial necrosis facilitates leakage of fluid, as occurs in the lungs of adenovirus-infected deer. Additionally, endothelial necrosis triggers platelet adhe-

sion and agglutination culminating in DIC. It is of interest that hemorrhage in the adenovirus-infected deer was confined to the small and large intestines, whereas, hemorrhage is reportedly more widespread in white-tailed deer (*Odocoileus virginianus*) infected with EHD or BT viruses (Fletcher and Karstad, 1971; Howerth et al., 1988).

Immunohistochemical staining demonstrated ADV antigen in endothelial cells in several organ systems, yet microscopic evidence of vascular damage was infrequently apparent in organs other than the lungs and alimentary tract of the animal that died of acute hemorrhagic disease. It is unclear why the virus appears to have varying effects on the endothelium of different organs, but results suggest possible functional or structural differences in endothelial cells from different organ systems.

Adenovirus was localized to the oral cavity and rumen in the deer inoculated twice with ADV. Vasculitis and thrombosis in large vessels adjacent to necrotic regions suggest the pathogenesis of the ulceration is ischemia with resulting necrosis of the region supplied by occluded vessels. Infection with several aerobic and anaerobic bacteria ensues with invasion of deep soft tissues and bone.

Histologic examination, as well as immunohistochemical staining did not demonstrate the presence of ADV in tissues from the fetuses in the affected animal. Therefore, it does not appear that virus crossed the placental barrier in this deer. Fetal infection may not occur or may only occur during a specific window of time during fetal development.

Further studies are in progress to determine if fawns are more susceptible to fatal ADV infection than yearlings. In addition, transmission studies will determine if virus is transmitted directly from animal-to-animal via secretions, more typical of ADV infections, or if a vector is required for transmission of the virus between animals as is the case with BT virus and EHD virus infections.

ACKNOWLEDGMENTS

We thank L. M. Shih for performing the BT PCR analysis, J. Karlunas for FA testing and J. Koobs and J. Barbano for histological support. This project was funded by the California Veterinary Diagnostic Laboratory System, the California Department of Fish and Game and the Mule Deer Association.

LITERATURE CITED

- AKITA, G. Y., J. GLENN, A. E. CASTRO, AND A. E. OSBURN. 1993. Detection of bluetongue virus in clinical samples by polymerase chain reaction. *Journal of Veterinary Diagnostic Investigation* 5: 154–158.
- BELAK, S. 1990. Ovine Adenoviruses. In *Virus infections of ruminants*, Z. Dinter and B. Morein (eds.). Elsevier Science Publishers, Amsterdam, Netherlands, pp. 171–185.
- CARTUN, R. W., AND C. A. PEDERSEN. 1989. An immunocytochemical technique offering increased sensitivity and lowered cost with a streptavidin-horseradish peroxidase conjugate. *Journal of Histochemistry* 4: 273–277.
- FENNER, F. J., E. P. J. GIBBS, F. A. MURPHY, R. ROTT, M. J. STUDDERT, AND D. O. WHITE. 1993. *Veterinary virology*, 2nd ed. Academic Press, New York, New York, pp. 329–336.
- FLETCH, A. L., AND L. H. KARSTAD. 1971. Studies on the pathogenesis of experimental epizootic hemorrhagic disease of white-tailed deer. *Canadian Journal of Comparative Medicine* 35: 224–229.
- HOFF, G., AND D. O. TRAINER. 1981. Hemorrhagic diseases, in wild ruminants. In *Infectious diseases of wild mammals*, 2nd ed., J. W. Davis and L. H. Karstad (eds.). The Iowa State University Press, Ames, Iowa, pp. 45–53.
- HORWITZ, M. S. 1990. Adenoviridae and their replication. In *Virology*, Vol. 2, B. N. Fields and D. M. Knipe (eds.). Raven Press, New York, New York, pp. 1,679–1,682.
- HOWERTH, E. W., C. E. GREENE, AND A. K. PRESTWOOD. 1988. Experimentally induced bluetongue virus infection in white-tailed deer: Coagulation, clinical pathologic, and gross pathologic changes. *American Journal of Veterinary Research* 49: 1,906–1,913.
- JESSUP, D. A., B. I. OSBURN, AND W. P. HEUSCHELE. 1984. Bluetongue in California's wild ruminants: distribution and pathology. *Proceedings of the Annual Meeting of United States Animal Health Association* 88: 616–630.
- KARSTAD, L., AND D. O. TRAINER. 1967. Histopathology of experimental bluetongue disease of white-tailed deer. *Canadian Veterinary Journal* 8: 247–254.
- KELLY, W. R. 1993. The liver and biliary system. In *Pathology of domestic animals*, 4th ed., K. V. F.

- Jubb, P. C. Kennedy, and N. Palmer (eds.). Academic Press, Inc., San Diego, California, pp. 319–406.
- NOWELL J. A., J. PANGBORN, AND W. S. TYLER. 1972. Stabilization and replication of soft tubular and alveolar systems. A scanning electron microscope study of the lungs. *In* Scanning electron microscopy, O. Johari and I. Cowin (eds.). Research Institute, Chicago, Illinois, pp. 305–313.
- PATTON, J., T. M. WORK, D. A. JESSUP, S. K. HIE-TALA, M. N. OLIVER, AND N. J. MACLACHLAN. 1994. Serologic detection of bluetongue virus infection of black-tailed deer: Comparison of serum neutralization, agar gel immunodiffusion, and competitive ELISA assays. *Journal of Wildlife Diseases* 30: 99–102.
- SMYTH, J. A., M. BENKO, D. A. MOFFETT, AND B. HARRACH. 1996. Bovine adenovirus type 10 identified in fatal cases of adenovirus-associated enteric disease in cattle by in situ hybridization. *Journal of Clinical Microbiology* 34: 1,270–1,274.
- TANG, K. N., C. A. BALDWIN, J. L. MANSELL, AND E. L. STYER. 1995. Disseminated adenovirus infection associated with cutaneous and visceral hemorrhages in a nursing piglet. *Veterinary Pathology* 32: 433–437.
- TRINDLE, B. D., L. D. LEWIS, AND L. H. LAUERMAN. 1978. Evaluation of stress and its effects on the immune system of hand-reared mule deer fawns. *Journal of Wildlife Diseases* 14: 523–537.
- WOODS, L. W., P. K. SWIFT, B. C. BARR, M. C. HORIZNEK, R. W. NORDHAUSEN, M. H. STILLIAN, J. F. PATTON, M. N. OLIVER, K. R. JONES, AND N. J. MACLACHLAN. 1996. Systemic adenovirus infection associated with high mortality in mule deer (*Odocoileus hemionus*) in California. *Veterinary Pathology* 33: 125–132.

Received for Publication 25 November 1996.