



Acute Filariasis in a Springhaas

Authors: Anderson, R.C., Gustafson, B.W., and Williams, E.S.

Source: Journal of Wildlife Diseases, 34(1) : 145-149

Published By: Wildlife Disease Association

URL: <https://doi.org/10.7589/0090-3558-34.1.145>

BioOne Complete (complete.BioOne.org) is a full-text database of 200 subscribed and open-access titles in the biological, ecological, and environmental sciences published by nonprofit societies, associations, museums, institutions, and presses.

Your use of this PDF, the BioOne Complete website, and all posted and associated content indicates your acceptance of BioOne's Terms of Use, available at www.bioone.org/terms-of-use.

Usage of BioOne Complete content is strictly limited to personal, educational, and non - commercial use. Commercial inquiries or rights and permissions requests should be directed to the individual publisher as copyright holder.

BioOne sees sustainable scholarly publishing as an inherently collaborative enterprise connecting authors, nonprofit publishers, academic institutions, research libraries, and research funders in the common goal of maximizing access to critical research.

SHORT COMMUNICATIONS

Journal of Wildlife Diseases, 34(1), 1998, pp. 145–149
© Wildlife Disease Association 1998

Acute Filariasis in a Springhaas

R. C. Anderson,¹ B. W. Gustafson,² and E. S. Williams,^{3,1} Department of Zoology, University of Guelph, Guelph, Ontario N1G 2W1, Canada; ² Big Horn Animal Clinic, 2417 Coffeen Avenue, Sheridan, Wyoming, 82801, USA; ³ Department of Veterinary Sciences, University of Wyoming, 1174 Snowy Range Road, Laramie, Wyoming, 82070, USA

ABSTRACT: A 2-yr old Springhaas (*Pedetes capensis*; Pedetidae, Rodentia) imported into the USA from the Republic of South Africa was severely debilitated as the result of aberrant migrations of adult *Filaria versterae* (Filarioidea: Filariidae) normally confined to the subcutaneous tissues of this host in Africa. Some nematodes invaded the peritoneal and thoracic cavities, the pericardial sac and the lungs. Invasion of the lungs resulted in life-threatening respiratory distress necessitating euthanasia. *Filaria versterae* is redescribed.

Key words: Case report, *Filaria versterae*, *Pedetes capensis*, springhaas, verminous pneumonia, translocations.

A 2-yr-old female springhaas (*Pedetes capensis*) was presented to the Big Horn Animal Clinic (Sheridan, Wyoming, USA) with a history of progressive weight loss of 3 wk duration. It had been purchased from an exotic animal dealer in Texas (USA) 4.5 mo earlier who had imported the animal from the Republic of South Africa when it was 9 to 12-mo-old.

On presentation, the springhaas was alert and responsive, but it also was emaciated and febrile. Tachypnea with shallow thoracic excursions were noted and mildly increased bronchovesicular sounds were apparent on thoracic auscultation. A dry harsh non-productive cough was heard three times. The left tarsal joint was warm, swollen and painful to palpation and an ulcer was present on the plantar surface of the left tuber calcaneus. The results of hematologic examination, serum chemistry panel and urinalysis were unremarkable with the exception of leukocytosis comprised mainly of mature neutrophils. Treatment consisted of enrofloxacin (Baytril, Bayer Corporation, Myerstown, Pennsylvania, USA), praziquantel (Droncit,

Bayer Corporation), and topical chlorhexidine (Nolvasan Solution, Fort Dodge Laboratories, Inc., Fort Dodge, Kansas, USA) flushes of the ulcerated tarsal area.

The springhaas' fever resolved within 48 hr and over the next 8 days she became more active and gained 0.25 kg of body weight. Tarsal swelling diminished and pain was not elicited on palpations of the joint. However, during the following 72 hr the springhaas became inappetent, lost 0.25 kg of body weight and became increasingly dyspneic and depressed; increased bronchovesicular sounds were ausculted in the peripheral pulmonary fields and infrequent coughing was noted. She seemed uncomfortable and ground her teeth at irregular intervals. The springhaas was euthanized at the request of the owner.

At necropsy numerous adult nematodes, subsequently identified as *Filaria versterae*, were found in subcutaneous tissues and in the peritoneal, thoracic and pericardial cavities. Some nematodes were found in bronchi and tips of several protruded from dense, yellow brown, triangular, mildly hemorrhagic lesions in the periphery of some lung lobes.

Various tissues, including lung and skin, were preserved in 10% phosphate-buffered formalin, embedded in paraffin, sectioned at 6 μ m and stained with hematoxylin and eosin. Microscopically, the main finding was cross-sections of nematodes in arteries of the lungs. One lung lobe had large irregular areas of necrosis, hemorrhage, mineralization, and thrombosed vessels containing sections of nematodes. The vascular intima was often unidentifi-

able and thrombi adhered to the vascular wall. Some vessels were infiltrated by neutrophils which often surrounded the nematode cross-sections. Eggs of *F. versterae* occurred in lumens of some vessels and occasionally in the arterial muscularis. Many perivascular spaces were infiltrated by neutrophils, macrophages, lymphocytes and some plasma cells. Lung parenchyma was often atelectic or alveoli and bronchi were filled with frothy or hemosiderin-bearing macrophages and a few neutrophils. Eggs of *F. versterae* occurred in some vessels and occasionally in the arterial muscularis.

Cross-sections of adult *F. versterae* containing eggs were present in the subcutis and dermis. Adults in the subcutis often were surrounded by lymphocytes, plasma cells, macrophages, and neutrophils. Those in the dermis seldom elicited an inflammatory response. Scattered single as well as aggregates of eggs were found in the middle and superficial dermis surrounded by light mononuclear infiltrates.

The cause of the illness in the springhaas was apparently the abnormal migration of adult *Filaria versterae* from their normal site under the skin to other regions of the body including the lungs. In the latter, the nematodes caused pulmonary thrombosis and bronchopneumonia.

Anderson (1960) described briefly specimens from *Pedetes caffer* in the collection of the British Natural History Museum (London, U.K. Accession number 1.28.39–40) which he incorrectly identified as *Filaria martis*, a parasite of Mustelidae. Chabaud and Mohammad (1989) described a female nematode from *Pedetes capensis* and proposed the name *Filaria versterae* to distinguish it from the species in carnivores. Except for the brief description of the female worm given by Chabaud and Mohammad (1989), the main description of the species is in Anderson (1960). The new material allows us to expand considerably and confirm the morphology of this rodent filariid.

Filaria versterae Chabaud and Mohammad, 1989

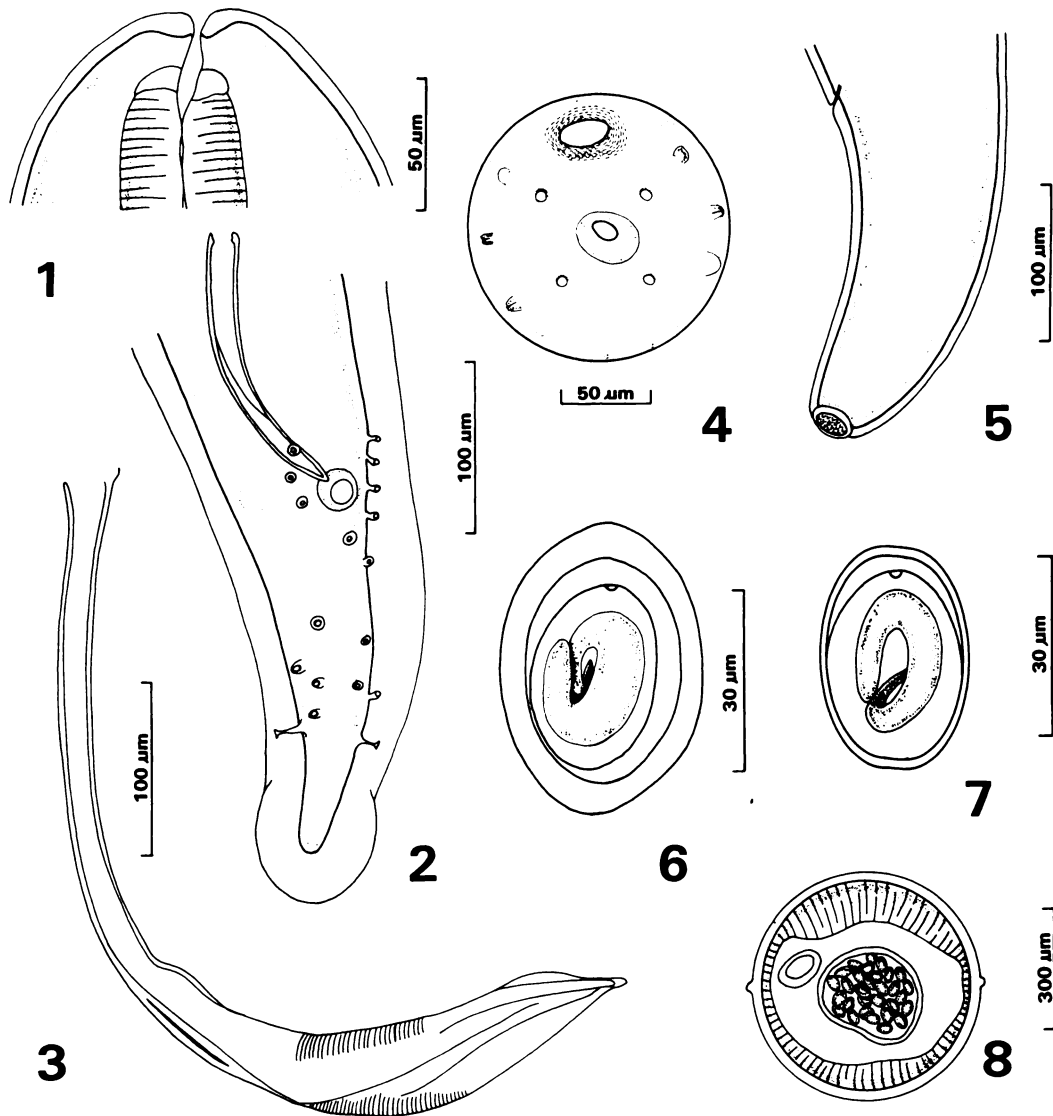
Synonym: *Filaria martis* Anderson, 1960 (not Gmelin, 1790) in *Pedestes caffer*

Description (Figs. 1–8)

General: Filarioidea, Filariidae, Filariinae, *Filaria* Mueller, 1787. Unusually long and slender with markedly tapered extremities. Cuticle, thick, with fine longitudinal striations in surface view and with inconspicuous lateral alae extending from region of deirids to caudal region. Cephalic end with four pairs submedian papillae and inconspicuous amphids. Buccal cavity tubular with thin walls, surrounded at base by refractory ring. Esophagus extremely long, division between muscular and glandular parts obscure.

Male: (2 specimens). Length 73, 80 mm. Maximum width near middle of body 326, 326 μm . Esophagus, 7.7, 8.3 mm in length. Nerve ring 115, 139 μm and deirids 186, 230 μm from cephalic extremity. Caudal end with 2 to 3 coils and thick lateral alae, extending around terminal end of tail. Ventral surface of coils with fine wavy transverse striations. Caudal papillae asymmetrically arranged. Phasmids well defined, about 80 μm from tip of tail. Tail 244, 260 μm in length. Right spicule simple, bow-like, 180, 172 μm in length. Left spicule 556, 585 μm in length, divided into tubular calomus and broad, complex lamina with membranous alae best observed in specimens cleared in beechwood creosote.

Female: (5 specimens). Extremely long, 279 (265–330) mm in length. Maximum width 543 (520–555) μm , near middle of body. Body cuticle 50–55 μm thick. Nerve ring 148 (140–155) μm and deirids 205 (191–215) μm from cephalic extremity. Length of esophagus not determined. Vulva beside oral opening with prominent cuticular ring. Vagina 8.0 (6.4–8.6) mm in length. Didelphic, opisthodelphic. Two types of eggs present in vagina and anterior part of uteri, both containing larvae. Thin-shelled eggs 32 (33–39) \times 24 (22–27) μm in size. Thick-shelled eggs 47 (41–54)



FIGURES 1–8. *Filaria versterae* from *Pedetes capensis*. 1. Cephalic end female, lateral view. 2. Caudal end, male, ventral view. 3. Left spicule. 4. Cephalic end female, apical view. 5. Caudal end female, lateral view. 6. Thick-shelled egg. 7. Thin-shelled egg. 8. Cross-section female showing lateral alae.

× 35 (31–39) µm in size. Tail 556 (490–620) µm in length. Terminal end rounded with oval cuticular plaque with numerous tubercles. Phasmids 229 (143–259) µm from caudal extremity.

Host: Springhaas, *Pedetes capensis* (Rodentia: Pedetidae).

Locality: Imported into Texas, USA from the Republic of South Africa.

Location: Subcutaneous, peritoneal

and thoracic cavities, pericardial sac and bronchi.

Specimens: United States National Parasite Collection, Beltsville, Maryland, USA. Accession No. 87066.

Filaria versterae apparently can be distinguished by the shape of the pre-esophageal ring combined with the presence on the female tail of a plaque with tubercles. Anderson (1960) and Chabaud and Mo-

hammad (1989) describe the eggs as "eggs without protein coats" and "souple et lisse." The present study shows there are two types of eggs, namely a thin-shelled egg described earlier and others with extremely thick shells. Both types of eggs contain larvae. The significance of the presence of the two kinds of eggs is unknown since transmission has not been documented for any species in the genus.

Species of *Filaria* are normally found in subcutaneous tissues only (Anderson 1960, 1992). The significance of the presence of worms in other regions of the body in the present case is unknown but is presumably aberrant.

Although it is unlikely that *F. versterae* could be transmitted to North American hosts, the present case shows how easy it is for exotic parasites to be introduced to the United States by importation of wild animals from other parts of the world.

Skin lesions which might be associated with *Filaria vesterae* were not noted in the springhaas. Keppner (1969, 1971), O'Toole et al. (1993, 1994) and Saito and Little (1997) described skin lesions in badgers (*Taxidea taxus*) and a skunk (*Mephitis mephitis*) infected with *Filaria taxideae*. According to O'Toole et al. (1993) eggs were apparently deposited between the epidermis and the cutaneous basement membrane. Dermoepidermal separation resulted in fibrin-rich blisters containing the eggs. Necrosis of the separated epidermis resulted in exposure of eggs onto the surface of the skin where they might be available to intermediate hosts (perhaps muscid dipterans attracted to lesions would be the most likely vectors—R.C.A.).

Anderson (1957) hypothesized that the typical life cycles of the advanced filarioids (i.e., microfilariae in skin or blood ingested by hematophagous vectors) may have had their origins in orbital nematodes like *Thelazia* spp. which release eggs with first-stage larvae into orbital secretions and are transmitted by muscid intermediate hosts. Some thelaziid-like nematodes may have left the orbit and adapted to the subcuta-

neous tissues of the host. To get eggs with first-stage larvae outside the host they had to pierce the skin and release eggs into blood attractive to dipteran intermediate hosts (e.g., *Parafilaria* spp. of horses and cattle; for review see Anderson 1992). In an advance on *Parafilaria* spp. eggs with first-stage larvae hatched in subcutaneous tissue and their presence and that of adults provoked a skin lesion attractive to intermediate hosts (e.g., *Stephanofilaria* spp.). The final step occurred with the appearance of microfilariae capable of living indefinitely in the skin or blood where they would be available to a wide range of biting arthropods. This final step allowed filarioids to become independent of skin lesions for transmission (except for the puncture wound made by the vector) and allowed them to radiate throughout the tissues of the higher vertebrates. The theoretical interest of *Filaria* spp. is that their methods of depositing eggs seems to bridge the gap between *Parafilaria* spp. and *Stephanofilaria* spp. Therefore, *Filaria* spp. are, along with *Parafilaria* spp., exceptionally primitive filarioid nematodes.

LITERATURE CITED

- ANDERSON, R. C. 1957. The life cycles of dipetalonematid nematodes (Filarioidea, Dipetalonematidae): the problem of their evolution. *Journal of Helminthology* 31: 203–224.
- . 1960. A study of *Filaria martis* Gmelin, 1790, from *Martes foina* and *Pedetes caffer*. *Canadian Journal of Zoology* 38: 157–167.
- . 1992. Nematode parasites of vertebrates, their development and transmission. CAB International, Wallingford, United Kingdom, 578 pp.
- CHABAUD, A. G., AND K. MOHAMMAD. 1989. Le genre *Filaria* Gmelin, 1790. Description de quatre espèces nouvelle. *Bulletin du Muséum d'Histoire Naturelle, Section A Zoologie, Biologie et Ecologie Animales* (1989) 11: 47–59.
- KEPPNER, E. J. 1969. *Filaria taxideae* n.sp. (Filarioidea: Filariidae) from the badger *Taxidea taxus* from Wyoming. *Transactions of the American Microscopic Society* 88: 581–588.
- . 1971. The pathology of *Filaria taxideae* (Filarioidea, Filariidae) infections in the badger. *Journal of Wildlife Diseases* 7: 317–323.
- O'TOOLE, D., V. WELCH, AND E. S. WILLIAMS. 1994. Immunohistochemistry of parasitic subepidermal vesiculobullous disease in American badgers

- (*Taxidea taxus*). Journal of Veterinary Diagnostic Investigation 6: 72–76.
- , E. S. WILLIAMS, V. WELCH, AND C. NUNAMAKER. 1993. Vesiculobullous skin disease in free-ranging badgers (*Taxidea taxus*). Veterinary Pathology 30: 343–351.
- SAITO, E. K., AND S. E. LITTLE. 1997. *Filaria taxideae*-induced dermatitis in a striped skunk (*Mephitis mephitis*). Journal of Wildlife Diseases 34: 873–876.

Received for publication 31 March 1997.