

VIREMIA AND VIRUS SHEDDING IN ELK INFECTED WITH TYPE 1 AND VIRULENT TYPE 2 BOVINE VIRAL DIARRHEA VIRUS

Authors: Tessaro, Stacy V., Carman, P. Suzanne, and Deregt, Dirk

Source: Journal of Wildlife Diseases, 35(4) : 671-677

Published By: Wildlife Disease Association

URL: <https://doi.org/10.7589/0090-3558-35.4.671>

BioOne Complete (complete.BioOne.org) is a full-text database of 200 subscribed and open-access titles in the biological, ecological, and environmental sciences published by nonprofit societies, associations, museums, institutions, and presses.

Your use of this PDF, the BioOne Complete website, and all posted and associated content indicates your acceptance of BioOne's Terms of Use, available at www.bioone.org/terms-of-use.

Usage of BioOne Complete content is strictly limited to personal, educational, and non - commercial use. Commercial inquiries or rights and permissions requests should be directed to the individual publisher as copyright holder.

BioOne sees sustainable scholarly publishing as an inherently collaborative enterprise connecting authors, nonprofit publishers, academic institutions, research libraries, and research funders in the common goal of maximizing access to critical research.

VIREMIA AND VIRUS SHEDDING IN ELK INFECTED WITH TYPE 1 AND VIRULENT TYPE 2 BOVINE VIRAL DIARRHEA VIRUS

Stacy V. Tessaro,^{1,3} P. Suzanne Carman,² and Dirk Dereg¹

¹ Animal Diseases Research Institute, Canadian Food Inspection Agency, P.O. Box 640, Lethbridge, Alberta T1J 3Z4, Canada

² University of Guelph, Animal Health Laboratory, Box 3612, Guelph, Ontario N1H 6R8, Canada

³ Corresponding Author (e-mail: tessaros@em.agr.ca)

ABSTRACT: In order to determine whether elk (*Cervus elaphus*) could be infected with and shed bovine viral diarrhea virus (BVDV) and to determine whether BVDV could cause disease in elk, two groups of five yearling elk each and two control cattle were experimentally inoculated intranasally with type 1 Singer strain or a virulent type 2 isolate of BVDV, strain 24515. Virulence of the type 2 isolate was confirmed by inoculation of a control bovine cow which developed diarrhea, dehydration, severe thrombocytopenia, hemorrhages, and enteritis with intestinal necrosis. None of the elk inoculated with type 1 or type 2 BVDV developed clinical signs of illness. However, all elk became infected as demonstrated by viremia, nasal shedding, and/or seroconversion. One uninoculated, in-contact elk contracted type 1 BVDV and seroconverted. Thus, although BVDV does not appear capable of producing disease in nonpregnant elk, the species is susceptible to infection and can shed and transmit BVDV.

Key words: Bovine viral diarrhea virus, elk, *Cervus elaphus*, experimental infection.

INTRODUCTION

Bovine viral diarrhea virus (BVDV) is a member of the *Pestivirus* genus (family Flaviviridae), a group of closely related, small RNA viruses that includes border disease virus of sheep and hog cholera (classical swine fever) virus (Wengler, 1991). Bovine viral diarrhea virus commonly infects cattle, although sheep and swine are also susceptible to BVDV infection (Carbrey et al., 1976). In cattle, BVDV causes enteritis, reproductive and respiratory disorders, congenital malformations, persistent infections, and a fatal condition known as mucosal disease (Baker, 1995). Many infections, however, are subclinical in nature.

Recently, BVDV has been segregated into two genotypes, type 1 (BVDV 1) and type 2 (BVDV 2) (Pellerin et al., 1994). Viruses of either genotype may exist as one of two biotypes, cytopathic and noncytopathic, as defined by the presence or absence of cytopathic effects in cell culture, respectively (Lee and Gillespie, 1957; Gillespie et al., 1960). Some viruses of the BVDV 2 genotype are particularly virulent in cattle (Pellerin et al., 1994). These viruses have been responsible for recent out-

breaks of severe disease in cattle in both Canada (Carman et al., 1998) and the United States (Ridpath et al., 1994). Acute disease caused by virulent BVDV 2 is characterized by fever, thrombocytopenia, hemorrhages (Corapi et al., 1989), oral lesions, pneumonia, diarrhea, and high abortion and mortality rates (Carman et al., 1998).

Although pestiviruses have long been known to cause economically important disease in domestic animals, the situation in populations of game-farmed and free-ranging wildlife is less clear (reviewed in Nettleton, 1990 and Løken, 1995). The majority of evidence for pestivirus infection in wildlife is derived from serological surveys and suggests that most ruminants can be infected. For instance, antibodies reactive to BVDV have been observed in 17 of 29 species of ruminants in one large scale study of African wildlife (Hamblin and Hedger, 1979). From Europe and North America antibodies reactive to BVDV have been found in red deer (*Cervus elaphus*), fallow deer (*Dama dama*), and roe deer (*Capreolus capreolus*) in Great Britain (Lawman et al., 1978) and Germany (Frölich, 1995); reindeer (*Rangifer tarandus*) in Norway (Stuen et al., 1993); white-tailed deer (*Odocoileus virginianus*) (Khars et al.,

1964) and mule deer (*Odocoileus hemionus*) (Couvillion et al., 1980) in the United States; and in elk (*Cervus elaphus*) (Kingscote et al., 1987), caribou (*Rangifer tarandus*) (Elazhary et al., 1979), and moose (*Alces alces*) (Thorsen and Henderson, 1971) in Canada. In addition, antibodies reactive to border disease virus have been observed in roe deer in Germany (Frölich, 1995) and elk in the United States (Van Campen and Williams, 1996).

Pestiviruses have only occasionally been isolated from cervids. Isolations that have been reported include those from a red deer (Nettleton et al., 1980), roe deer (Frölich and Hoffman, 1995), and a captive fallow deer (Edwards et al., 1988). The latter two viruses have been partially characterized. Sequence analysis places the roe deer isolate in the BVDV 1 genotype (Fischer et al., 1998), whereas there is some controversy over whether the fallow deer isolate belongs in the BVDV 1 genotype or whether it constitutes a unique genotype (Dekker et al., 1995; Becher et al., 1997; van Rijn et al., 1997).

There have only been a few reports of experimental infections of cervids with BVDV. McMartin et al. (1977) reported a lack of clinical signs in a red deer after oral and intranasal exposure to BVDV, whereas Morton et al. (1990) observed mild disease in two experimentally infected reindeer. Recently, Van Campen et al. (1997) showed that mule deer and white-tailed deer were susceptible to infection with BVDV 1 and could shed the virus, but none of the animals developed clinical disease.

The objectives of the study described herein were to determine whether elk were susceptible to infection with BVDV 1 or virulent BVDV 2 and to determine the course of infection. A report of clinical BVD in bison in Elk Island National Park, Alberta, Canada in 1997 (N. Cool, pers. comm.) precipitated this study. Although elk in the Park did not appear to be clinically affected by the BVDV outbreak, some elk were seropositive to the virus and it was considered important to determine the course of infec-

tion in elk and whether or not they could serve as a reservoir for BVDV.

MATERIALS AND METHODS

Fourteen yearling elk were obtained from Elk Island National Park, Alberta, Canada. Three groups of elk were housed separately in three isolation units. Two groups of five elk (3 males, 2 females) each were inoculated on day 0 either with the cytopathic, type 1 Singer strain of BVDV (BVDV 1-Singer) or the virulent, noncytopathic, type 2 strain 24515 (BVDV 2-24515). Four other elk were not inoculated: two (one male, one female) were isolated as negative controls, and the other two (females) were introduced on the second day post inoculation (dpi) to either group of inoculated elk. Two 2-yr-old bovine cows (Angus × Hereford) served as positive controls and were housed in the remaining available isolation unit and inoculated with BVDV 1-Singer or BVDV 2-24515. All inoculated animals were given a total of 2×10^7 50% tissue culture infectious doses (TCID₅₀) of BVDV 1-Singer or BVDV 2-24515. One ml of virus inoculum was given in each nostril. All procedures complied with the guidelines of the Canadian Council on Animal Care (Ottawa, Ontario, Canada).

The BVDV 1-Singer strain, obtained from Animal Diseases Research Institute (Nepean, Ontario, Canada) (Deregt et al., 1998), and BVDV 2-24515, isolated in 1993 during an epizootic of acute severe disease in cattle in Ontario, Canada (Carman et al., 1998), were propagated in BVDV-free Madin-Darby bovine kidney (MDBK) cells as previously described (Deregt et al., 1992). The titer of virus in the inoculum was determined by end-point titration and staining of infected foci using an immunoperoxidase test as described previously (Deregt and Prins, 1998).

Elk and cattle were monitored twice daily for signs of clinical disease. Blood samples, nasal swabs, and rectal swabs were collected twice weekly for the first 2 wk of the experiment and once weekly thereafter. Blood analyses (routine hematology and clinical chemistry panels) were performed at the Western College of Veterinary Medicine (Saskatoon, Saskatchewan, Canada). Elk and cattle were euthanized with an intravenous overdose of pentobarbital on dpi 57–78, except for the BVDV 2-inoculated cow which was euthanized on dpi 16.

Virus isolation was attempted from serum, leukocytes, nasal and rectal swabs, and from tissues obtained at necropsy. To prepare leukocytes, 2 ml of Red Cell Lysing Buffer (Sigma-Aldrich Canada Ltd., Oakville, Ontario, Canada) was added to 1 ml of whole blood. Leu-

kocytes were then pelleted by centrifugation, washed once in minimal essential medium (MEM) (Canadian Life Technologies, Burlington, Ontario, Canada) containing penicillin (200 µg/ml) and streptomycin (200 I.U./ml), and finally resuspended in 2 ml of medium before storage at -80°C . Nasal and rectal swabs were placed into tubes containing 2 ml of MEM containing 5% horse serum (Canadian Life Technologies) and antibiotics, vortexed, and also stored at -80°C . Tubes containing rectal swab material were centrifuged to clarify the sample before virus isolation. The following tissues were collected from all animals at necropsy for virus isolation: tonsil, mediastinal and retropharyngeal lymph nodes, and ileum. Approximately 1 g of tissue was minced in 5 ml of MEM containing antibiotics. The resulting homogenate was allowed to settle for 3 hr at 4°C before using the supernatant for virus isolation.

Virus isolation was performed in the same manner for all samples. Two hundred µl of serum, leukocyte preparation, and supernatants from nasal and rectal swabs and tissue homogenates were inoculated onto confluent MDBK cells in 24-well plates for 1 hr. The inoculum was removed and cells were incubated in 1 ml of MEM containing 2% horse serum and antibiotics for 4 days at 37°C . After examination for cytopathic effect, cultures were frozen and thawed. For a second passage of virus, 25 µl of the supernatant from frozen and thawed cultures and 100 µl of freshly trypsinized MDBK cells were added to wells of a 96-well microtiter plate. After further incubation at 37°C for 4 days, cells were observed for cytopathic effect and fixed and stained for BVDV infection using an immunoperoxidase test as described previously (Deregt and Prins, 1998).

To determine the virus neutralizing antibody titers in elk and bovine sera, a serum neutralization test was performed essentially as described with modifications for determination of antibodies against noncytopathic BVDV (Deregt et al., 1992). For titers against BVDV 1 and BVDV 2, the Singer strain and 24515 were used as the challenge virus, respectively. Sera from elk and bovine cows collected before inoculation on dpi 0 were also tested for antibodies against the border disease virus isolate BD31 (Ridpath and Bolin, 1997). The titer recorded was the reciprocal of the highest dilution of serum which completely neutralized infection as determined by the absence of cytopathic effect (Singer) or immunoperoxidase staining (24515, BD31).

Representative samples of major organs and lymph nodes were collected at necropsy for histological evaluation. Tissues were fixed in 10% neutral buffered formalin, processed to paraf-

fin, sectioned at 5 µm, and stained with hematoxylin and eosin for light microscopy.

RESULTS

With one exception, all elk remained healthy during the course of the study. The exception was the in-contact female elk of the BVDV 2-inoculated group which was found dead on dpi 12 without having shown any clinical signs of disease in the days prior to death. Bacteriology was not done, but pathologic findings in this elk included splenomegaly and generalized lymph node hyperplasia suggesting that it died from an acute septicemia.

Although clinical signs of disease were not observed, virus was isolated from inoculated elk. Cytopathic BVDV was isolated from serum and/or nasal swabs from all five of the BVDV 1-inoculated elk and noncytopathic BVDV was isolated from the same samples from three of the BVDV 2-inoculated elk, on dpi 3 and/or dpi 7 (Table 1). Cytopathic BVDV was also isolated from the serum of the in-contact elk in the BVDV 1-inoculated group on dpi 23.

Noncytopathic BVDV was isolated from serum, nasal swabs, and leukocytes from the bovine cow inoculated with virulent BVDV 2-24515 (Table 1). However, virus was not isolated from leukocytes of any of the inoculated or in-contact elk. Virus isolation was negative for all samples of the in-contact elk in the BVDV 2-inoculated group, for the BVDV 1-inoculated bovine cow, and the two negative control elk. Attempted virus isolation from rectal swabs, and from tissues collected at necropsy, gave negative results for all animals.

Blood parameters remained in the normal range for all elk and the BVDV 1-inoculated bovine cow during the course of the study (data not shown). In particular, they showed neither a leukocytopenia nor a thrombocytopenia. However, virulence of the BVDV 2 isolate was confirmed in the inoculated bovine cow which showed a continuous leukocytopenia from dpi 3. The total leukocyte count dropped from $10.9 \times 10^9/\text{L}$ (day 0) to a low of $1.9 \times 10^9/\text{L}$

TABLE 1. Isolation of bovine viral diarrhea virus from serum and nasal swabs collected from experimentally infected elk.

Group and animal ^b	Day post-inoculation ^a								≥35 ^c
	0	3	7	10	14	16	23	28	
BVDV 1 (Singer)									
elk #33M	-/-	-/+	+/-	-/-	-/-	-/-	-/-	-/-	-/-
elk #42F	-/-	-/+	+/+	-/-	-/-	-/-	-/-	-/-	-/-
elk #46F	-/-	-/-	-/+	-/-	-/-	-/-	-/-	-/-	-/-
elk #47M	-/-	+/-	-/-	-/-	-/-	-/-	-/-	-/-	-/-
elk #52M	-/-	-/+	-/-	-/-	-/-	-/-	-/-	-/-	-/-
in-contact elk #37F ^d	-/-	-/-	-/-	-/-	-/-	-/-	+/-	-/-	-/-
bovine #16F	-/-	-/-	-/-	-/-	-/-	-/-	-/-	-/-	-/-
BVDV 2 (24515)									
elk #32M	-/-	-/-	+/-	-/-	-/-	-/-	-/-	-/-	-/-
elk #38F	-/-	-/-	-/-	-/-	-/-	-/-	-/-	-/-	-/-
elk #39F	-/-	-/+	-/+	-/-	-/-	-/-	-/-	-/-	-/-
elk #48M	-/-	+/-	+/+	-/-	-/-	-/-	-/-	-/-	-/-
elk #49M	-/-	-/-	-/-	-/-	-/-	-/-	-/-	-/-	-/-
in-contact elk #43F ^{d,e}	-/-	-/-	-/-	-/-	-/-	-/-	-/-	-/-	-/-
bovine #13F ^f	-/-	-/+	+/+ ^g	-/+ ^g	-/+	-/-	-/-	-/-	-/-
No virus									
control elk #35M	-/-	-/-	-/-	-/-	-/-	-/-	-/-	-/-	-/-
control elk #40F	-/-	-/-	-/-	-/-	-/-	-/-	-/-	-/-	-/-

^a For each day results are given for serum followed by those for nasal swabs; -, negative; +, positive.^b Sex is indicated by M = male, F = female.^c Virus isolation was negative on dpi 35, 42, 49, and 56 for all animals which remained to the end of the experiment.^d In-contact elk were introduced to inoculated group on dpi 2.^e This animal died on dpi 12.^f The cow was euthanized on dpi 16.^g Virus was also isolated on these days from blood leucocytes.

L on dpi 14. The leukocytopenia represented a decline in the number of lymphocytes (to $1.5 \times 10^9/L$) starting at dpi 3 and a profound decline in the number of neutrophils (to $0 \times 10^9/L$) on dpi 10 and dpi 14. The cow developed diarrhea on dpi 11 and was depressed, anorexic, and markedly dehydrated on dpi 14. Severe thrombocytopenia ($10 \times 10^9/L$) was observed on dpi 14. This was a ~40-fold decrease in platelet number in this animal from a week earlier. Platelets and lymphocytes then rebounded to normal numbers, and the number of neutrophils began to increase, by dpi 16. Fibrinogen levels were very highly elevated in the cow on dpi 14 and dpi 16 (13 and 14 g/L, respectively). The cow was euthanized on dpi 16.

At necropsy, the BVDV 2-inoculated bovine cow had subcutaneous hemorrhages,

and petechial and ecchymotic hemorrhages on the pleural surface of the lungs, epicardium, serosa of the rumen and intestines, and in the mesentery and omentum. Ulcerative enteritis was prominent, especially in association with Peyer's patches which often were necrotic. Foci of ulcerative colitis were seen histologically. Also present were areas of transmural intestinal necrosis with associated focal fibrinous peritonitis and distension of the mesentery with fibrin. In contrast, at necropsy none of the elk nor the BVDV 1-inoculated bovine cow showed any gross or microscopic lesions at necropsy which could be attributed to BVDV infection.

All elk and cattle were seronegative to BVDV and border disease virus on day 0. By dpi 14, all inoculated elk and cattle showed seroconversion and subsequent

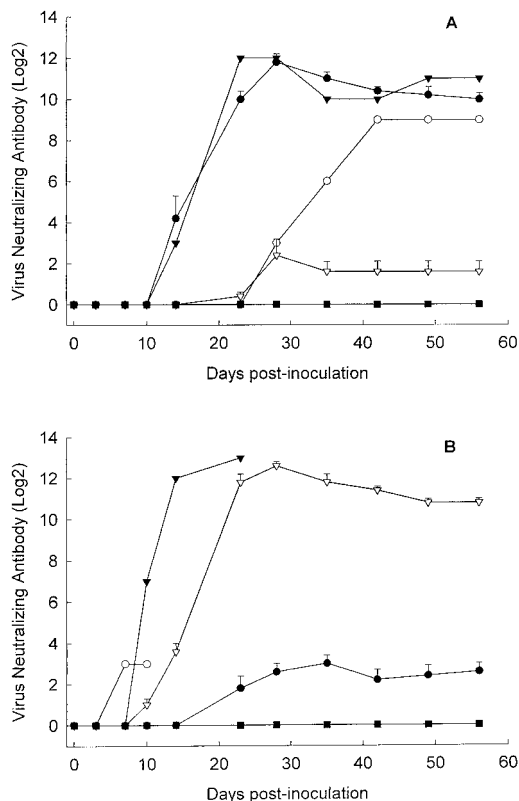


FIGURE 1. Virus neutralizing antibody titers against bovine viral diarrhea virus (BVDV) in elk (and cattle) experimentally infected with BVDV 1-Singer or BVDV 2-24515 and non-inoculated, in-contact and negative control elk. Neutralizing antibody against BVDV 1-Singer (A) or BVDV 2-24515 (B). Both A and B, mean (+SE) antibody titer of five elk (#33, 42, 46, 47, 52) inoculated with BVDV 1-Singer (●); mean (+SE) antibody titer of five elk (#32, 38, 39, 48, 49) inoculated with BVDV 2-24515 (▽); mean antibody titer of negative control elk (#35, 40) (■). A only, antibody titer of in-contact elk (#37) in BVDV 1-inoculated group (○); antibody titer of bovine cow (#16) inoculated with BVDV 1-Singer (▼). B only, antibody titer of in-contact elk (#43) in BVDV 2-inoculated group (○); antibody titer of bovine cow (#13) inoculated with BVDV 2-24515 (▼).

high antibody titers to BVDV (Fig. 1). Mean maximum reciprocal neutralizing antibody titers of ~4,000 and ~8,000 were achieved for elk in the BVDV 1- and BVDV 2-inoculated groups, respectively, by dpi 28. The titers against the homologous virus were much higher, by ~600 to 800-fold over the mean titers calculated for these groups against the heterologous

virus, reflecting both the significant antigenic differences between BVDV 1-Singer and BVDV 2-24515 and a very distinct response to the challenge virus.

DISCUSSION

This study shows that elk can be infected with BVDV 1 and BVDV 2 and that shedding of the virus occurs in infected elk. Furthermore, infected elk can transmit the virus to other elk as demonstrated by viremia and seroconversion in one of the in-contact elk. From this study, it is also apparent that, although elk can be infected with BVDV, the virus does not produce acute disease in nonpregnant animals of this species.

With one exception, the death of one in-contact elk which occurred early in the experiment, all elk remained healthy during the study. Although the in-contact elk did show a small antibody titer to BVDV on dpi 7, this was observed before inoculated animals of the group seroconverted, and only 5 dpi after it was introduced to the group which is probably too early for an antibody response to infection with BVDV. Further, the fact that the antibody titer did not increase from this low level on dpi 10 suggests that these antibodies were cross-reactive but non-specific to BVDV. Necropsy findings were consistent with septicemia as the cause of death. Thus, the death of this elk does not appear to have been attributable to BVDV.

Although a few infection studies of cervids with BVDV have been done previously, no study using virulent BVDV 2 has been reported. The recent emergence of this genotype as a severe pathogen of cattle made this an interesting agent to investigate in elk. The BVDV 2-24515 isolate used in this study was recently used in another study to infect neonatal calves in which it produced severe multisystemic disease (Ellis et al., 1998). The virulence of the agent for cattle was confirmed in our study. The lack of signs of disease in elk inoculated with BVDV 2-24515 suggest that elk are resistant to acute disease even

from strains of BVDV that are particularly virulent in cattle.

Of interest was the finding that while the BVDV 2 isolate was associated with leukocytes in the cow, the virus did not appear to be associated with leukocytes of elk based on attempted virus isolation. It has been suggested that the virulence of BVDV 2 correlates with increased uptake of the virus in leukocytes (J. F. Ridpath, pers. comm.). Thus, one might speculate that the lack of disease in infected elk may, in part, be due to an inability of BVDV to infect elk leukocytes, a hypothesis that requires further testing.

In cattle, BVDV produces both acute and persistent infections. In the former, the majority of animals usually recover with the production of antibodies and clearance of the virus. Cattle can be born persistently infected (PI) when infected in utero with noncytopathic BVDV (Baker, 1995). These PI animals shed virus throughout their life, thereby maintaining the virus in the environment. In herds, PI animals are often the major source of infection, resulting in reproductive disease in pregnant cattle. Thus, a major emphasis in the control of BVDV in cattle is avoidance and culling of PI animals. It is not known if BVDV can cause reproductive disease in elk or whether elk can be persistently infected with the virus. These would be interesting questions to answer in another study.

It is apparent from this study that acute infection with BVDV is of little consequence to nonpregnant elk. However, virus is shed by infected elk and, therefore, elk may transmit BVDV to other wild or domestic animals. This knowledge may be of importance for the transport and quarantine of elk. From this study, the period of BVDV shedding in elk does not appear to be longer than 1 wk.

ACKNOWLEDGMENTS

We thank S. Prins, W. Krampfl, and J. Dixon-MacDougall for technical assistance and animal handling, T. Entz of Agriculture and Agri-food Canada for assistance with graphics, and E. Blake for assistance with the preparation of this

manuscript. We also thank B. Chisholm and S. A. Gilbert of the Canadian Food Inspection Agency, and N. Cool of Elk Island National Park, for logistical support of the project. This work was supported by funds from the Rocky Mountain Elk Foundation, Pfizer Animal Health Canada, private donations from elk ranchers, and the Government of Canada's Matching Investment Initiative.

LITERATURE CITED

- BAKER, J. C. 1995. The clinical manifestations of bovine viral diarrhea infection. *Veterinary Clinics of North America: Food Animal Practice* 11: 627-640.
- BECHER, P., M. ORLICH, A. D. SHANNON, G. HORN, M. KONIG, AND H. -J. THIEL. 1997. Phylogenetic analysis of pestiviruses from domestic and wild ruminants. *Journal of General Virology* 78: 1357-1366.
- CARBREY, E. A., W. C. STEWART, J. I. KRESSE, AND M. L. SYNDER. 1976. Natural infection of pigs with bovine viral diarrhea virus and its differential diagnosis from hog cholera. *Journal of the American Veterinary Medical Association* 169: 1217-1219.
- CARMAN, S., T. VAN DREUMEL, J. RIDPATH, M. HAZLETT, D. ALVES, E. DUBOVI, R. TREMBLAY, S. BOLIN, A. GODKIN, AND N. ANDERSON. 1998. Severe acute bovine viral diarrhea in Ontario, 1993-1995. *Journal of Veterinary Diagnostic Investigation* 10: 27-35.
- CORAPI, W. V., T. W. FRENCH, AND E. J. DUBOVI. 1989. Severe thrombocytopenia in young calves experimentally infected with noncytopathic bovine viral diarrhea virus. *Journal of Virology* 63: 3934-3943.
- COUVILLION, C. E., E. W. JENNEY, J. E. PEARSON, AND M. E. COKER. 1980. Survey for antibodies to viruses of bovine virus diarrhea, bluetongue, and epizootic hemorrhagic disease in hunter-killed mule deer in New Mexico. *Journal of the American Veterinary Medical Association* 177: 790-791.
- DEKKER, A., G. WENSVOORT, AND C. TERPSTRA. 1995. Six antigenic groups within the genus pestivirus as identified by cross neutralization assays. *Veterinary Microbiology* 47: 317-329.
- DERECT, D. AND S. PRINS. 1998. A monoclonal antibody-based immunoperoxidase monolayer (micro-isolation) assay for detection of type 1 and type 2 bovine viral diarrhea viruses. *Canadian Journal of Veterinary Research* 62: 152-155.
- , S. R. BOLIN, J. VAN DEN HURK, J. F. RIDPATH, AND S. A. GILBERT. 1998. Mapping of a type 1-specific and a type-common epitope on the E2 (gp53) protein of bovine viral diarrhea virus with neutralization escape mutants. *Virus Research* 53: 81-90.
- , S. SMITHSON AND G. KOZUB. 1992. A short

- incubation serum neutralization test for bovine viral diarrhea virus. *Canadian Journal of Veterinary Research* 56: 161–164.
- EDWARDS, S., J. SANDS, AND J. W. HARKNESS. 1988. The application of monoclonal antibody panels to characterize pestivirus isolates from ruminants in Great Britain. *Archives of Virology* 102: 197–206.
- ELAZHARY, M. A. S. Y., R. S. ROY, AND J. L. FRECHETTE. 1979. Serological evidence of IBR and BVD infection in caribou (*Rangifer tarandus*). *Veterinary Record* 105: 336.
- ELLIS, J. A., K. H. WEST, V. S. CORTESE, S. L. MYERS, S. CARMAN, K. M. MARTIN, AND D. M. HAINES. 1998. Lesions and distribution of viral antigen following an experimental infection of young seronegative calves with virulent bovine viral diarrhea virus-type II. *Canadian Journal of Veterinary Research* 62: 161–169.
- FISCHER, S., E. WEILAND, AND K. FRÖLICH. 1998. Characterization of a bovine viral diarrhea virus isolated from roe deer in Germany. *Journal of Wildlife Diseases* 34: 47–55.
- FRÖLICH, K. 1995. Bovine virus diarrhea and mucosal disease in free-ranging and captive deer (Cervidae) in Germany. *Journal of Wildlife Diseases* 31: 247–250.
- , AND M. HOFFMAN. 1995. Isolation of bovine viral diarrhea virus-like pestiviruses from roe deer. *Journal of Wildlife Diseases* 31: 243–246.
- GILLESPIE, J. H., J. A. BAKER, AND K. MCENTEE. 1960. A cytopathogenic strain of virus diarrhea virus. *Cornell Veterinarian* 50: 73–79.
- HAMBLIN, C., AND R. S. HEDGER. 1979. The prevalence of antibodies to bovine viral diarrhea/mucosal disease virus in African wildlife. *Comparative Immunology, Microbiology and Infectious Diseases* 2: 295–303.
- KHARS, R., G. ATKINSON, J. A. BAKER, L. CARMICHAEL, L. COGGINS, J. GILLESPIE, P. LANGER, V. MARSHALL, D. ROBSON, AND B. SHEFFY. 1964. Serological studies on the incidence of bovine virus diarrhea, infectious bovine rhinotracheitis, bovine myxovirus parainfluenza-3, and *Leptospira pomona* in New York state. *Cornell Veterinarian* 54: 360–369.
- KINGSCOTE, B. F., W. D. G. YATES, AND G. B. TIFIN. 1987. Diseases of wapiti utilizing cattle range in southwestern Alberta. *Journal of Wildlife Diseases* 23: 86–91.
- LAWMAN, M. J. P., D. EVANS, E. P. J. GIBBS, A. MCDIARMID, AND L. ROWE. 1978. A preliminary survey of British deer for antibody to some virus diseases of farm animals. *British Veterinary Journal* 134: 85–91.
- LEE, K. M., AND J. H. GILLESPIE. 1957. Propagation of virus diarrhea virus of cattle in tissue culture. *American Journal of Veterinary Research* 18: 952–953.
- LØKEN, T. 1995. Ruminant pestivirus infections in animals other than cattle and sheep. *Veterinary Clinics of North America: Food Animal Practice* 11: 597–614.
- MCMARTIN, D. A., D. R. SNODGRASS, AND W. CORRIGALL. 1977. Bovine virus diarrhoea antibody in a Scottish red deer. *Veterinary Record* 100: 187.
- MORTON, J. K., J. F. EVERMAN, AND R. A. DIETERICH. 1990. Experimental infection of reindeer with bovine viral diarrhea virus. *Rangifer* 10: 75–77.
- NETTLETON, P. F. 1990. Pestivirus infections in ruminants other than cattle. *Revue Scientifique et Technique Office International des Épidémiologies* 9: 131–150.
- , J. A. HERRING, AND W. CORRIGALL. 1980. Isolation of bovine viral diarrhea virus from a Scottish red deer. *Veterinary Record* 107: 425–426.
- PELLERIN, C., J. VAN DEN HURK, J. LECOMTE, AND P. TIJSSEN. 1994. Identification of a new group of bovine viral diarrhea virus strains associated with severe outbreaks and high mortalities. *Virology* 203: 260–268.
- RIDPATH, J. F., AND S. R. BOLIN. 1997. Comparison of the complete genomic sequence of the border disease virus, BD31, to other pestiviruses. *Virus Research* 50: 237–243.
- , ———, AND E. J. DUBOVI. 1994. Segregation of bovine viral diarrhea virus into genotypes. *Virology* 205: 66–74.
- STUEN, S., J. KROGSRUD, B. HYLLSETH, AND N. J. C. TYLER. 1993. Serosurvey of three virus infections in reindeer in northern Norway and Svalbard. *Rangifer* 13: 215–219.
- THORSEN, J., AND J. P. HENDERSON. 1971. Survey for antibody to infectious bovine rhinotracheitis (IBR), bovine virus diarrhea (BVD) and parainfluenza 3 (PI3) in moose sera. *Journal of Wildlife Diseases* 7: 93–95.
- VAN CAMPEN, H., AND E. S. WILLIAMS. 1996. Wildlife and bovine viral diarrhea virus. In *International Symposium Bovine Viral Diarrhea Virus: A 50 Year Review*. Cornell University, College of Veterinary Medicine, Diagnostic Laboratory, Ithaca, New York, pp. 167–175.
- , ———, J. EDWARDS, W. COOK, AND G. STOUT. 1997. Experimental infection of deer with bovine viral diarrhea virus. *Journal of Wildlife Diseases* 33: 567–573.
- VAN RIJN, P. A., H. G. P. VAN GENNIP, C. H. LEENDERTSE, C. J. M. BRUSCHKE, D. J. PATON, R. J. M. MOORMAN, AND J. T. VAN OIRSCHOT. 1997. Subdivision of the *pestivirus* genus based on envelope glycoprotein E2. *Virology* 237: 337–348.
- WENGLER, G., 1991. Family Flaviviridae. In *Classification and nomenclature of viruses*. International Committee on Taxonomy of Viruses, 5th Edition R. I. B. Francki, C. M. Fauquet, D. L. Knudson, and F. Brown (eds.). Springer-Verlag, Berlin, Germany, pp. 223–233.

Received for publication 18 November 1998.