

## **FATAL TOXOPLASMOSIS IN FREE-RANGING ENDANGERED 'ALALA FROM HAWAII**

Authors: Work, Thierry M., Massey, J. Gregory, Rideout, Bruce A., Gardiner, Chris H., Ledig, David B., et al.

Source: Journal of Wildlife Diseases, 36(2) : 205-212

Published By: Wildlife Disease Association

URL: <https://doi.org/10.7589/0090-3558-36.2.205>

---

BioOne Complete ([complete.BioOne.org](https://complete.bioone.org)) is a full-text database of 200 subscribed and open-access titles in the biological, ecological, and environmental sciences published by nonprofit societies, associations, museums, institutions, and presses.

Your use of this PDF, the BioOne Complete website, and all posted and associated content indicates your acceptance of BioOne's Terms of Use, available at [www.bioone.org/terms-of-use](https://www.bioone.org/terms-of-use).

Usage of BioOne Complete content is strictly limited to personal, educational, and non - commercial use. Commercial inquiries or rights and permissions requests should be directed to the individual publisher as copyright holder.

---

BioOne sees sustainable scholarly publishing as an inherently collaborative enterprise connecting authors, nonprofit publishers, academic institutions, research libraries, and research funders in the common goal of maximizing access to critical research.

# FATAL TOXOPLASMOSIS IN FREE-RANGING ENDANGERED 'ALALA FROM HAWAII

Thierry M. Work,<sup>1,7</sup> J. Gregory Massey,<sup>2</sup> Bruce A. Rideout,<sup>3</sup> Chris H. Gardiner,<sup>4</sup> David B. Ledig,<sup>5</sup> O. C. H. Kwok,<sup>6</sup> and J. P. Dubey<sup>6</sup>

<sup>1</sup> U.S. Geological Survey, Biological Resources Division, National Wildlife Health Center, Honolulu Field Station, P.O. Box 50167, Honolulu Hawaii 96850, USA

<sup>2</sup> Hawaii Division of Forestry and Wildlife, 2600 Piipolo Road, Makawao, Hawaii 96768, USA

<sup>3</sup> San Diego Zoo, P.O. Box 551, San Diego, California 92112, USA

<sup>4</sup> Armed Forces Institute of Pathology, Washington, D. C. 20306, USA

<sup>5</sup> U.S. Fish and Wildlife Service, Kona Forest Unit of Hakalau Forest National Wildlife Refuge, P.O. Box 244, Honaunau, Hawaii 96726, USA

<sup>6</sup> U.S. Department of Agriculture, Agricultural Research Service, Parasite Biology and Epidemiology Laboratory, Bldg. 101, 10300 Baltimore Avenue, Beltsville, Maryland 20705, USA

<sup>7</sup> Corresponding author (email:thierry\_work@usgs.gov)

**ABSTRACT:** The 'Alala (*Corvus hawaiiensis*) is the most endangered corvid in the world, and intensive efforts are being made to reintroduce it to its former native range in Hawaii. We diagnosed *Toxoplasma gondii* infection in five free-ranging 'Alala. One 'Alala, recaptured from the wild because it was underweight and depressed, was treated with diclazuril (10 mg/kg) orally for 10 days. Antibodies were measured before and after treatment by the modified agglutination test (MAT) using whole *T. gondii* tachyzoites fixed in formalin and mercaptoethanol. The MAT titer decreased four-fold from an initial titer of 1:1,600 with remarkable improvement in physical condition. Lesions of toxoplasmosis also were seen in two partially scavenged carcasses and in a third fresh intact carcass. *Toxoplasma gondii* was confirmed immunohistochemically by using anti-*T. gondii* specific serum. The organism was also cultured by bioassay in mice from tissues of one of these birds and the brain of a fifth 'Alala that did not exhibit lesions. The life cycle of the parasite was experimentally completed in cats. This is the first record of toxoplasmosis in 'Alala, and the parasite appears to pose a significant threat and management challenge to reintroduction programs for 'Alala in Hawaii.

**Key words:** 'Alala, *Corvus hawaiiensis*, bioassay, diclazuril, endangered species, immunohistochemistry, pathology, *Toxoplasma gondii*.

## INTRODUCTION

The 'Alala (*Corvus hawaiiensis*) is one of the most endangered corvids in the world with less than 25 birds remaining in captivity or in the wild. Free-ranging 'Alala are now restricted to a small portion of their historical range in the South Kona region of the island of Hawaii (National Research Council, 1992). Suggested causes for the 'Alala's decline include disease, loss of genetic diversity, introduced predators, or habitat loss (van Riper et al., 1986; Giffin et al., 1987; National Research Council, 1992).

Data on diseases of free-ranging 'Alala are limited. Avian pox (Jenkins et al., 1989) and avian malaria (*Plasmodium relictum*) (Jenkins et al., 1989; Massey et al., 1996) cause morbidity in young 'Alala, and *Erysipelothrix rhusiopathiae* caused the death of one young bird ~8 mo after release into

the wild (Work et al., 1999). As in other rare endangered species, the identification of 'Alala morbidity and mortality factors has been hampered by the lack of diagnostic specimens. The marking of captive-raised 'Alala with radio-transmitters prior to their release has increased the recovery of carcasses. However, a number of wild-origin 'Alala have not been captured and marked. Even when marked, wild birds will often not show clinical signs of illness until just prior to death, and consequently, confirmatory diagnosis is complicated by the scavenged or partially decomposed condition of the recovered carcass. Finally, if a disease is detected in live birds, therapy can be complicated by lack of information on safety and efficacy of drug use in endangered species. This paper describes clinical signs, lesions, and chemotherapy of *Toxoplasma gondii* infection in 'Alala.

## METHODS

Twenty seven captive-raised 'Alala (Kuehler et al., 1994) were released in the South Kona region (155°86'E; 19°30'N) (Hawaii, Hawaii, USA) from 23 August 1993 through the present with the most recent release being on 5 January 1999. All birds were fitted with a backpack radiotransmitter (Advanced Telemetry Systems, Model 10-28, Isanti, Minnesota, USA) and tracked daily (Kuehler et al., 1995) in the early stages of the reintroduction period by The Peregrine Fund and U.S. Fish and Wildlife Service personnel. Mortalities were referred to the National Wildlife Health Center Honolulu Field Station or the San Diego Zoo. Because of excessive mortalities (7/11 birds) over a 4 mo period, remaining released birds were recaptured in September 1998, placed in an outdoor aviary at the reintroduction site, and fed *ad libitum* a mixture of fruit, vegetables, scrambled eggs, and fresh-frozen mice and rats (Gourmet Rodent, Archer, Florida, USA).

One recaptured 'Alala (bird 1), exhibiting depression and inappetence, was flown from Hawaii to a quarantine facility on Maui. Two to 3 ml of blood in lithium heparin were collected from a jugular vein with a 3 ml syringe attached to a 0.6 cm, 0.8 mm needle. Blood was centrifuged, plasma harvested, and stored at -70 C in cryovials. Blood was obtained at the time of recapture and on days 44, 57 and 70 post-capture. Weights were measured with a spring scale (Pesola, Bern, Switzerland) in the field, and an electronic balance in the quarantine facility.

Serology for *T. gondii* infection was done using plasma and the modified agglutination test (MAT) (Dubey and Desmonts, 1987). Plasma was screened initially at 1:25, 1:50, and 1:500 dilutions, and serial two-fold dilutions were tested using tachyzoites fixed in formalin and mercaptoethanol. A titer of >1:25 was considered positive for *T. gondii* infection.

We treated Bird 1 for *T. gondii* with an oral suspension of diclazuril (1 mg/ml) (Janssen Pharmaceutica, Beerse, Belgium). The dosage regimen consisted of a loading dose of 10 mg/kg orally once a day for three days (days 44-46; Fig. 1) followed by a single dose orally (10 mg/kg) every other day (days 48, 50, 52, 54, 56; Fig. 1) for a total of 18 days. Behavioral observations to evaluate condition and detect any adverse drug reaction were made every 1-2 hr, for the first 24 hr and twice daily thereafter until diclazuril treatment ended. During treatment, Bird 1 was offered scrambled eggs, fruits, vegetables, and fresh-frozen mice *ad libitum*.

Four 'Alala carcasses with tissues available

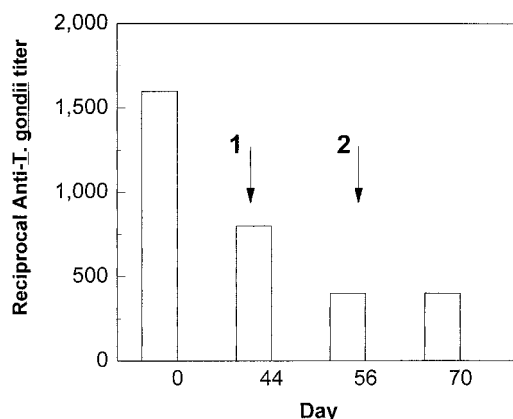


FIGURE 1. Reciprocal anti-*T. gondii* antibody titers as measured by the modified agglutination test for 'Alala treated with diclazuril. Arrows 1 and 2 represent start and end of treatment with diclazuril, respectively.

for examination were recovered. Birds 2, 3, and 4 were partially scavenged carcasses found in June, July, and September 1998, respectively. These birds had been dead for approximately 24-48 hr before they were found and necropsied. Bird 5 was observed healthy in the wild in April 1999, but was seen acutely ill 2 days later and recaptured; the bird died the next day despite supportive care. The carcass was chilled immediately and a necropsy performed the next morning.

A complete post mortem examination was done, and available tissues, including skeletal muscle, heart, spleen, brain, lung, trachea, kidney, adrenal, gonad, liver, esophagus, proventriculus, ventriculus, small and large intestines, pancreas, cloaca, and bone marrow were fixed in 10% buffered formalin, embedded in paraffin, sectioned at 5  $\mu$ m, stained with hematoxylin and eosin (H&E), and examined microscopically. Impression smears of spleen, lung and liver from Bird 5 were stained with a Romanowsky-type stain (Campbell, 1994), and also examined microscopically. Age of birds and time in wild was determined from dates of hatching and release (Kuehler, 1998).

For immunohistochemical examination, deparaffinized unstained tissue sections on poly-L-lysine (Sigma, St. Louis, Missouri, USA) slides were reacted with anti-*T. gondii* antibodies made in rabbits (Lindsay and Dubey, 1989) except that peroxidase/antiperoxidase (Sigma) system was used. In addition, unstained sections were reacted with anti-bradyzoite specific (anti-BAG-5) antibodies made in rabbits (McAllister et al., 1996).

TABLE 1. Sex, days in the wild, approximate age (days) at death, and date carcass was found for 'Alala infected with *Toxoplasma gondii*.

Bird	Sex	Days in wild	Age at death	Date carcass found
1	M	240	408 <sup>a</sup>	NA
2	F	168	356	24 June 1998
3	F	197	382	23 July 1998
4	M	597	791	2 September 1998
5	M	95	321	11 April 1999

<sup>a</sup> Age when bird was recaptured on 4 September 1998.

Bioassays in mice (Dubey and Beattie, 1988) for *T. gondii* were done using the brain from Bird 4 and liver, spleen and lung from Bird 5. Briefly, tissues were homogenized (10% w/v) in sterile aqueous saline (0.85% NaCl), centrifuged, and resuspended (1 ml deposit in 9 ml saline) in saline containing 1,000 units/ml of penicillin and 100 µg/ml of streptomycin. One ml of the suspension was injected subcutaneously into each of four mice which were observed for clinical signs. Tissues of mice that died were examined for developmental stages of *T. gondii*. Survivors were bled 30 to 80 days after inoculation (DAI) and their sera tested (1:25) for antibodies to *T. gondii*. After serologic testing, the mice were killed and the brain examined for *T. gondii* tissue cysts (Dubey and Beattie, 1988). Tissues of infected mice were subinoculated subcutaneously into clean mice for maintenance of the parasite. To obtain oocysts, mice with tissue cysts were fed to *T. gondii*-free cats and their feces examined for oocysts (Dubey, 1995).

## RESULTS

Time in the wild for birds 1–5 ranged from 95–597 days and approximate age at death ranged from 321–791 days (Table 1). At capture, Bird 1 was depressed, underweight (440 g), inappetent with dull ruffled feathers, and had a high (1:1,600) titer to *T. gondii* (Fig. 1). The bird remained lethargic during the first 2–3 days of treatment with diclazuril, but gradually improved and showed increasing interest in food. By the end of treatment, the bird gained 40 g, and its clinical condition improved markedly. Antibody titers to *T. gondii* between capture and the start of drug therapy dropped two-fold soon after therapy started, and remained at 1:400

(Fig. 1). The 'Alala has since been placed into the captive breeding flock, and has maintained weight, normal clinical demeanor and appetite.

Birds 2 and 3 were partially scavenged and in poor body condition; Bird 2 had an enlarged friable spleen, and Bird 3 had focal hemorrhage in the left lung and right intercostal musculature. Bird 4 was completely consumed by maggots except for the brain. Bird 5 had an enlarged mottled friable spleen, pale foci within an enlarged liver, 0.3 ml of clear yellow fluid in the pericardial sac, fibrin tags adhering to the inner intercostal muscles, and diffuse hemorrhage in skeletal muscles of the neck and fascia of the trachea.

Histologic examination of tissues in birds 2 and 3 revealed numerous 10–16 µm diameter round tissue cysts filled with bradyzoites in the brain, acute multifocal necrosis of neuropil, and perivascular mononuclear infiltrates (Fig. 2A). Other lesions included myocarditis, adrenalitis with tachyzoites, hepatic congestion and hemosiderosis. No lesions were seen in the brain of Bird 4. Bird 5 had multiple foci of necrosis, nonsuppurative inflammation, and hemorrhage associated with tachyzoites in the spleen, liver, brain, adrenal, and skeletal muscle (Fig. 2B). Numerous tachyzoites were seen in impression smears of liver and spleen of Bird 5; many of the tachyzoites were dividing and their shape varied with stage of division (Fig. 2C). In contrast to Birds 2 and 3, tissue cysts with bradyzoites were rarely observed in the brain of Bird 5. Fluid from the lung and liver and antemortem plasma from Bird 5 had MAT anti-*T. gondii* titers of 1:3,200, 1:1,600, and 1:800, respectively. Tissue cysts and tachyzoites in tissues of all birds reacted with polyclonal anti-*T. gondii* serum. Individual extracellular bradyzoites and tissue cysts from Bird 3 reacted positively to anti-BAG-5 antibody (Fig. 2D).

Of the four mice inoculated with brain from Bird 4, two mice died from bacterial infection (determined by time to death and presence of bacteria on culture and

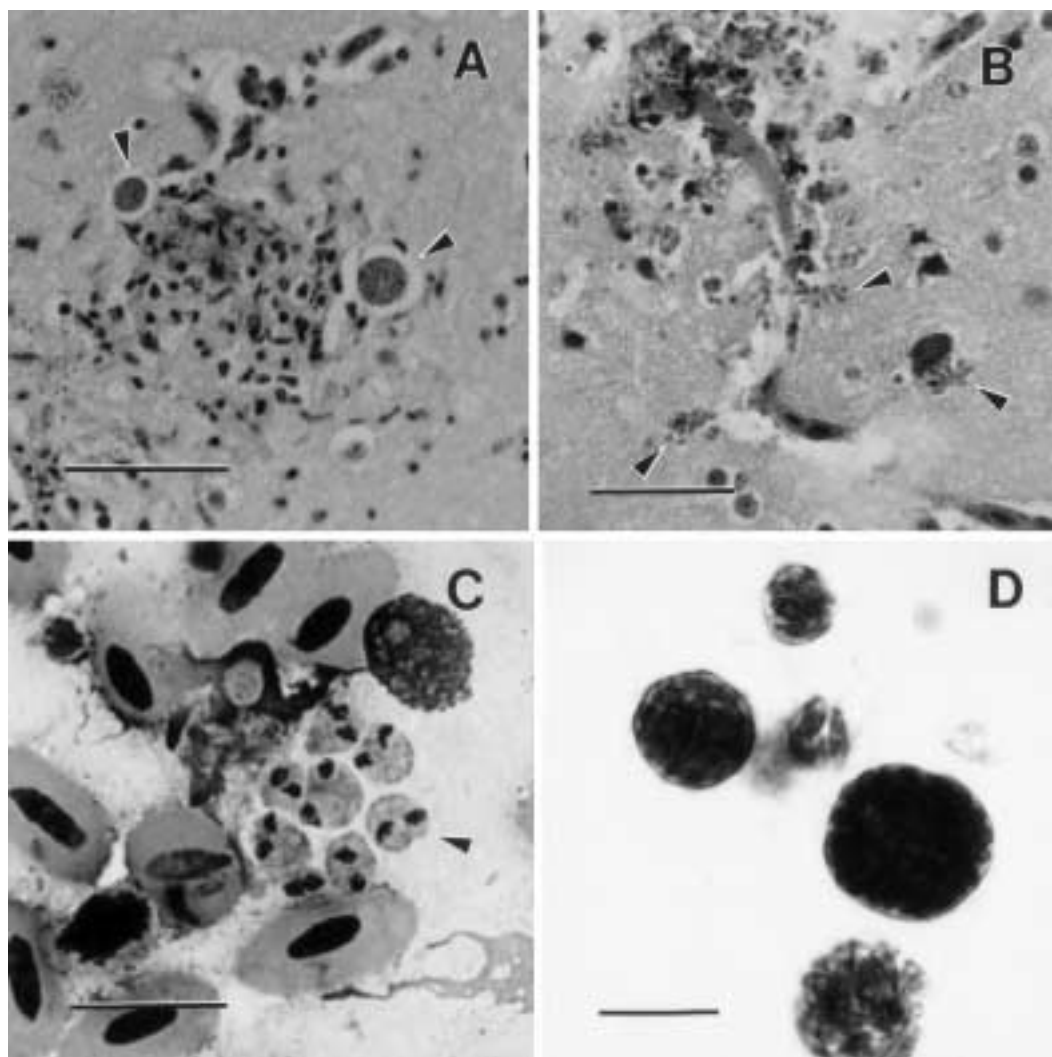


FIGURE 2. A. Tissue cysts (arrowhead) associated with necrosis in the brain of Bird 2. H&E. bar = 50  $\mu$ m. B. Perivascular necrosis and tachyzoites (arrowhead) in brain of Bird 5. H&E. Bar = 30  $\mu$ m. C. *Toxoplasma gondii* tachyzoites (arrowhead) in impression smear of liver from Bird 5. Modified Romanowsky. Bar = 10  $\mu$ m. D. Immunohistochemical staining of tissue cysts with anti-BAG-5 antibody from brain of Bird 3. Note different density suggesting different ages of these cysts. Bar = 10  $\mu$ m.

impression smears of organs) 2 and 4 days DAI and were discarded. One mouse seroconverted ( $>1:500$ ) to *T. gondii* 80 DAI, and the last remained seronegative and had no tissue cysts in the brain. Brain from the seropositive mouse containing numerous tissue cysts of *T. gondii* was subinoculated into four mice all of which died 12 DAI with *T. gondii* tachyzoites in the lung. Homogenate of lung from one infected

mouse was subinoculated into four mice all of which survived. Tissue cysts were found in the brains of all mice killed 106 DAI. Four *T. gondii*-free cats fed tissue cysts shed *T. gondii* oocysts with a prepatent period of four days. All mice inoculated with liver, spleen, lung and brain from Bird 5 seroconverted ( $>1:25$ ) by 28 DAI and tissue cysts of *T. gondii* were found in the brain of two mice killed 30 DAI. Tis-

sue cysts were infective to *T. gondii*-free mice.

### DISCUSSION

While we did not confirm toxoplasmosis in the live sick 'Alala (Bird 1), the MAT titers were indicative of infection with the parasite (Dubey et al., 1994). The histologic lesions observed in 3 dead 'Alala (Birds 2, 3 and 5) were compatible with those of avian toxoplasmosis (Brickford and Saunders, 1966); however, an unusual feature was the presence of numerous tissue cysts, fewer tachyzoites and severe encephalitis in Birds 2 and 3. Lindsay et al. (1995a) reported lesions in roller canaries (*Serinus canaria*) similar to those seen in Birds 2 and 3 of this study. In contrast, most cases of experimental (Dubey et al., 1994, 1995) and naturally acquired avian toxoplasmosis (Howerth and Rodenroth, 1985) manifest the presence of numerous tachyzoites and few tissue cysts. The numerous dividing tachyzoites in tissues of Bird 5 revealed the proliferative nature of *T. gondii* in 'Alala and was suggestive of recently acquired acute toxoplasmosis. Although the absence of lesions in Bird 4 prevents us from concluding that *T. gondii* was the cause of death, the findings from Bird 5 indicate that this organism can be rapidly fatal to 'Alala.

*Toxoplasma gondii* was first isolated by mouse inoculation of internal organs from apparently healthy American crows (*Corvus brachyrhynchos*) in Syracuse, New York (USA) (Finlay and Manwell, 1956). Franti et al. (1976) found that among free-ranging birds in California (USA), antibody prevalence to *T. gondii*, measured using the indirect hemagglutination test, was highest (18%) in American crows. In a survey of wildlife in the Czech Republic, Literak et al. (1992), using mouse inoculation of tissues, also found a prevalence of 18% in apparently healthy Eurasian Rooks (*Corvus frugelicus*); however, using similar methods in the Caucasus (Russia), Iygiste and Gusev (1962) were unable to detect *T. gondii* in two ravens (*Corvus cor-*

*ax*). The presence of *T. gondii* in corvids is not surprising given their scavenging omnivorous habits and the widespread distribution of feline definitive hosts. Because the parasite can be found in soil (Ruiz et al. 1973), insects (Wallace, 1973a), and a variety of wildlife species (Dreesen, 1990), there are presumably ample opportunities for scavenging birds like corvids to become infected.

On Oahu, cats and rodents are infected with *T. gondii* (Wallace, 1973b) while insects may serve as transport hosts. The presence of the parasite in Pacific islands is closely related to the presence of cats (Wallace, 1969). Among birds, susceptibility to *T. gondii* varies with species. Experimentally, chuckar partridges (*Alectoris graeca*) were more susceptible to toxoplasmosis than pheasants; raptors were the most resistant (Dubey et al., 1992).

We suspect that 'Alala in Kona became infected with *T. gondii* by ingesting oocysts from infected feral cat feces, tissue cysts from transport hosts such as infected rodents, native or non-native birds, or from invertebrates that ingest oocysts. Feral cats are present throughout the South Kona region of the island of Hawaii, and newly released captive-bred 'Alala have been seen investigating and foraging for insects in non-native mammal feces in the reintroduction area. These observations indicate that in addition to direct predation, feral cats pose a significant disease threat to re-introduced 'Alala. The parasite may be a significant factor in the 'Alala's decline by increasing mortality rates directly or indirectly by increasing susceptibility of infected ill birds to predators such as non-native mammals and native raptors like the 'Io (*Buteo solitarius*). Results of cat feeding experiments indicated that the *T. gondii* strain from 'Alala (Bird 4) cycled through cats efficiently.

Efforts to reintroduce 'Alala in Hawaii have included intensive non-native mammal trapping and removal to reduce the chances of predator-induced mortality. However, in the long term, the elimination

of *T. gondii* in reintroduction habitat would require the elimination of feral cats. For various reasons, this is unlikely to happen in Hawaii in the near future. Trying to produce enough captive bred 'Alala for release to saturate the habitat and absorb losses due to the parasite may also be difficult and impractical. Another less desirable management option would involve treating sick 'Alala with diclazuril or administering the drug to 'Alala prophylactically.

It is unclear whether 'Alala are unusually susceptible to toxoplasmosis. Susceptibility to *T. gondii* may be increased in released 'Alala as they are stressed or lose weight during the weaning period of the reintroduction process. This may be due, in part, to lack of experience foraging in the wild. The body mass of the sick 'Alala (Bird 1) was low for a male (J.G. Massey, unpubl. data), and some of the birds necropsied were in fair to poor body condition. The prevalence of *T. gondii* infection and antibodies in apparently healthy crows and ravens on the continents suggests that at least some corvids in these areas survive infection. The presence of *T. gondii* from the brain of Bird 4 suggests that the parasite can reside in 'Alala brain with no associated lesions. Our findings indicate that with supportive care, 'Alala can survive infection with *T. gondii*. Whether wild 'Alala can survive infection without supportive care is unknown.

Drugs commonly used to treat toxoplasmosis include clindamycin (Sande and Mandell, 1985), sulfadiazine (Mandell and Sande, 1985) and pyrimethamine (Webster, 1985). Sulfadiazine was used to successfully treat roller canaries infected with *T. gondii* in Australia (Lindsay et al., 1995a). However, the potential side effects of these drugs such as colitis (clindamycin), renal damage (sulfadiazine) or anemia (pyrimethamine) (Sande and Mandell, 1985; Mandell and Sande, 1985; Webster, 1985) complicates their use in endangered species.

Diclazuril, a benzene acetonitrile, is

used as an anticoccidial for poultry and rabbits in Europe (Vanparijs et al., 1989, 1991); diclazuril is not currently available commercially in the USA. Diclazuril appears to be safe and highly effective against *T. gondii* tachyzoites both in vitro (Lindsay and Blagburn, 1994) and in vivo (Lindsay et al., 1995b). In the 'Alala treated with diclazuril, no adverse effects or plasma changes associated with hepatic or renal toxicity were seen. The dosage of diclazuril in this study was that used to successfully treat mice experimentally infected with *T. gondii* (Lindsay et al., 1995b). The rapid clinical response of Bird 1 to drug therapy and the associated decrease in antibody titers suggests that the diclazuril was effective in the treatment of *T. gondii*. Diclazuril seems to have valuable potential for treatment of *T. gondii* in birds. Although we did not document side effects in this instance, there is a clear need for more systematic evaluations of this drug as a therapeutic and prophylactic agent for controlling pathogenic protozoal infections in avian species other than poultry.

#### ACKNOWLEDGMENTS

We are grateful to the following participants in 'Alala research and recovery: The 'Alala Partnership Group (C. Salley, K. Unger, S. Timpson, B. Rosehill, N. Santimer, J. Burgett, K. Clarkson, J. Klavitter, D. Ball, G. Nakai, P. Harrity, A. Lieberman and C. Kuehler). We are grateful to B. McIlraith and The Peregrine Fund for use of the quarantine facilities on Maui. S. Derrickson suggested we use diclazuril, and M. Bush graciously provided the drug used in this study. D. Lindsay, S. Derrickson, and anonymous reviewers kindly provided constructive comments on the manuscript.

#### LITERATURE CITED

- BRICKFORD, A. A., AND J. R. SAUNDERS. 1966. Experimental transmission of toxoplasmosis in chickens. *American Journal of Veterinary Research* 116: 308-318.
- CAMPBELL, T. W. 1994. Hematology. In *Avian medicine: Principles and application*, B. W. Ritchie, G. J. Harrison and L. R. Harrison (eds.). Wingers Press, Lake Worth, Florida, pp. 176-198.
- DRESEN, D. W. 1990. *Toxoplasma gondii* infections

- in wildlife. *Journal of the American Veterinary Medical Association* 196: 274–276.
- DUBEY, J. P. 1995. Duration of immunity to shedding of *Toxoplasma gondii* oocysts by cats. *The Journal of Parasitology* 81: 410–415.
- , AND C. P. BEATTIE. 1988. *Toxoplasmosis of animals and man*, CRC Press, Boca Raton, Florida, 220 pp.
- , AND G. DESMONT. 1987. Serological response of equids fed *Toxoplasma gondii* oocysts. *Equine Veterinary Journal* 9: 337–339.
- , M. A. GOODWIN, M. D. RUFF, S. K. SHEN, O. C. H. KWOK, G. L. WILKINS, AND P. THULLIEZ. 1995. Experimental toxoplasmosis in chukar partridges (*Alectoris graeca*). *Avian Pathology* 24: 95–107.
- , S. L. PORTER, F. TSENG, S. K. SHEN, AND P. THULLIEZ. 1992. Induced toxoplasmosis in owls. *Journal of Zoo and Wildlife Medicine* 23: 98–102.
- , M. D. RUFF, G. C. WILKINS, S. K. SHEN, AND O. C. H. KWOK. 1994. Experimental toxoplasmosis in pheasants (*Phasianus colchicus*). *Journal of Wildlife Diseases* 30: 40–45.
- FINLAY, P., AND R. D. MANWELL. 1956. *Toxoplasma* from the crow, a new natural host. *Experimental Parasitology* 5: 149–153.
- FRANTI, C. E., H. P. RIEMANN, D. E. BEHYMER, D. SUTHER, T. A. HOWARTH, AND R. RUPPANNER. 1976. Prevalence of *Toxoplasma gondii* antibodies in wild and domestic animals in California. *Journal of the American Veterinary Medical Association* 169: 901–906.
- GIFFIN, J. G., J. M. SCOTT, AND S. MOUNTAINSPRING. 1987. Habitat selection and management of the Hawaiian crow. *The Journal of Wildlife Management* 51: 485–494.
- HOWERTH, E. W., AND N. RODENROTH. 1985. Fatal systemic toxoplasmosis in a wild turkey. *Journal of Wildlife Diseases* 21: 446–449.
- IYGISTE, A. K., AND V. M. GUSEV. 1962. Toxoplasmosis of wild birds in the USSR. *Dokladi Akademii Nauk SSSR* 143: 491–92.
- JENKINS, C. D., S. A. TEMPLE, C. VAN RIPER, AND W. R. HANSEN. 1989. Disease-related aspects of conserving the endangered Hawaiian crow. In *Disease and threatened birds*, J. E. Cooper (ed.) International Council on Bird Preservation, Cambridge, UK, pp. 77–87.
- KUEHLER, C. 1998. 'Alala (*Corvus hawaiiensis*) studybook. The Peregrine Fund, Inc., Boise, Idaho, 11 pp.
- , M. KUHN, B. MCILRAITH, AND G. CAMPBELL. 1994. Artificial incubation and hand rearing of alala (*Corvus hawaiiensis*) eggs removed from the wild. *Zoo Biology* 13: 3.
- , P. HARRITY, A. LIEBERMAN, AND A. KUHN. 1995. Reintroduction of hand reared alala (*Corvus hawaiiensis*) in Hawaii. *Oryx* 29: 261–266.
- LINDSAY, D. S., AND B. L. BLAGBURN. 1994. Activity of diclazuril against *Toxoplasma gondii* in cultured cells and mice. *American Journal of Veterinary Research* 55: 530–533.
- , AND J. P. DUBEY. 1989. Immunohistochemical diagnosis of *Neospora caninum* in tissue sections. *American Journal of Veterinary Research* 50: 1981–1983.
- , R. B. GASSER, K. E. HARRIGAN, D. N. MADILL, AND B. L. BLAGBURN. 1995a. Central nervous system toxoplasmosis in roller canaries. *Avian Diseases* 39: 204–207.
- , N. S. RIPPEY, AND B. L. BLAGBURN. 1995b. Treatment of acute *Toxoplasma gondii* infections in mice with diclazuril or a combination of diclazuril and pyrimethamine. *The Journal of Parasitology* 81: 315–318.
- LITERAK, I., K. HEJLICECK, J. NEZVAL, AND C. FOLK. 1992. Incidence of *Toxoplasma gondii* in populations of wild birds in the Czech Republic. *Avian Pathology* 21: 659–665.
- MANDELL, G. L., AND M. SANDE. 1985. Antimicrobial agents-sulfonamides. In *Goodman and Gilman's pharmacological basis of therapeutics*, A. G. Gilman, L. S. Goodman, T. W. Rall, and F. Murad (eds.). McMillan, New York, New York, pp. 1095–1114.
- MASSEY, J. G., T. K. GRACZYK, AND M. R. CRANFIELD. 1996. Characteristics of naturally acquired *Plasmodium relictum capistranoae* infections in native Hawaiian crows (*Corvus hawaiiensis*) in Hawaii. *The Journal of Parasitology* 82: 182–185.
- MCCALLISTER, M. M., S. F. PARMLEY, L. M. WEISS, V. J. WELCH, AND A. M. MCGUIRE. 1996. An immunohistochemical method for detecting bradyzoite antigen (BAG5) in *Toxoplasma gondii*-infected tissues cross-reacts with a *Neospora caninum* bradyzoite antigen. *The Journal of Parasitology* 82: 354–355.
- NATIONAL RESEARCH COUNCIL. 1992. *The Scientific bases for the preservation of the Hawaiian crow*. National Academy Press, Washington, D. C., 136 pp.
- RUIZ, A., J. K. FRENKEL, AND L. CERDAS. 1973. Isolation of *Toxoplasma* from soil. *The Journal of Parasitology* 59: 204–206.
- SANDE, M., AND G. L. MANDELL. 1985. Antimicrobial agents-tetracyclines. In *Goodman and Gilman's pharmacological basis of therapeutics*, A. G. Gilman, L. S. Goodman, T. W. Rall, and F. Murad (eds.). McMillan, New York, New York, pp. 1177–1198.
- VANPARIJS, O., L. DESPLENTER, AND R. MARSBOOM. 1989. Efficacy of diclazuril in the control of intestinal coccidiosis in rabbits. *Veterinary Parasitology* 34: 185–190.
- , ———, AND ———. 1991. Efficacy of diclazuril against turkey coccidiosis in a floor pen experiment. *Avian Diseases* 33: 479–481.
- VAN RIPER, C., III, S. G. VAN RIPER, M. L. GOFF,



- AND M. LAIRD. 1986. The epizootiology and ecological significance of malaria in Hawaiian land birds. *Ecological Monographs* 56: 327–344.
- WALLACE, G. D. 1969. Serologic and epidemiologic observations on Toxoplasmosis on three Pacific atolls. *American Journal of Epidemiology* 90: 103–111.
- . 1973a. Intermediate and transport hosts in the natural history of *Toxoplasma gondii*. *American Journal of Tropical Medicine and Hygiene* 22: 456–464.
- . 1973b. The role of the cat in the natural history of *Toxoplasma gondii*. *American Journal of Tropical Medicine and Hygiene* 22: 313–322.
- WEBSTER, L. T., JR. 1985. Drugs used in chemotherapy of protozoal infections. *In* Goodman and Gilman's pharmacological basis of therapeutics, A. G. Gilman, L. S. Goodman, T. W. Rall, and F. Murad (eds.). McMillan, New York, New York, pp. 1029–1049.
- WORK, T. M., D. BALL, AND M. WOLCOTT. 1999. Erysipelas in a free-ranging Hawaiian crow (*Corvus hawaiiensis*). *Avian Diseases* 43: 338–341.

Received for publication 15 July 1999.