

## **PATHOLOGY OF UPPER RESPIRATORY TRACT DISEASE OF GOPHER TORTOISES IN FLORIDA**

Authors: McLaughlin, G. S., Jacobson, E. R., Brown, D. R., McKenna, C. E., Schumacher, I. M., et al.

Source: Journal of Wildlife Diseases, 36(2) : 272-283

Published By: Wildlife Disease Association

URL: <https://doi.org/10.7589/0090-3558-36.2.272>

---

BioOne Complete ([complete.BioOne.org](https://complete.bioone.org)) is a full-text database of 200 subscribed and open-access titles in the biological, ecological, and environmental sciences published by nonprofit societies, associations, museums, institutions, and presses.

Your use of this PDF, the BioOne Complete website, and all posted and associated content indicates your acceptance of BioOne's Terms of Use, available at [www.bioone.org/terms-of-use](https://www.bioone.org/terms-of-use).

Usage of BioOne Complete content is strictly limited to personal, educational, and non - commercial use. Commercial inquiries or rights and permissions requests should be directed to the individual publisher as copyright holder.

---

BioOne sees sustainable scholarly publishing as an inherently collaborative enterprise connecting authors, nonprofit publishers, academic institutions, research libraries, and research funders in the common goal of maximizing access to critical research.

## **PATHOLOGY OF UPPER RESPIRATORY TRACT DISEASE OF GOPHER TORTOISES IN FLORIDA**

**G. S. McLaughlin,<sup>1,2</sup> E. R. Jacobson,<sup>1,7</sup> D. R. Brown,<sup>3,4</sup> C. E. McKenna,<sup>4</sup> I. M. Schumacher,<sup>5</sup> H. P. Adams,<sup>6</sup> M. B. Brown,<sup>3</sup> and P. A. Klein<sup>4,5</sup>**

<sup>1</sup> Department of Small Animal Clinical Sciences, College of Veterinary Medicine, University of Florida, Gainesville, Florida 32610, USA

<sup>2</sup> Department of Wildlife Ecology and Conservation, Institute of Food and Agricultural Sciences, College of Agriculture, University of Florida, Gainesville, Florida 32610, USA

<sup>3</sup> Department of Pathobiology, College of Veterinary Medicine, University of Florida, Gainesville, Florida 32610, USA

<sup>4</sup> Department of Pathology, Immunology, and Laboratory Medicine, College of Medicine, University of Florida, Gainesville, Florida 32610, USA

<sup>5</sup> Biotechnologies for the Ecological, Evolutionary, and Conservation Sciences, University of Florida, Gainesville, Florida 32610, USA

<sup>6</sup> Department of Cell Biology, Integrated Microscopy Core, Baylor College of Medicine, Houston, Texas 77030, USA

<sup>7</sup> Corresponding author (e-mail: jacobsons@mail.vetmed.ufl.edu)

**ABSTRACT:** Between August 1993 and September 1995, 24 gopher tortoises (*Gopherus polyphemus*) were received for pathological evaluations from various locations in Florida (USA). All tortoises were examined for clinical signs of upper respiratory tract disease (URTD) including nasal and ocular discharge, palpebral edema, and conjunctivitis. Of the 24 tortoises, 10 had current or previously observed clinical signs of URTD and 14 did not. A blood sample was drawn for detection of anti-mycoplasma antibodies by ELISA, and nasal lavage samples were collected for culture and detection of *Mycoplasma agassizii* gene sequences by polymerase chain reaction (PCR). Of the 14 clinically healthy tortoises, eight were sero-, culture- and PCR-negative, and six were seropositive for antibodies against *M. agassizii*. Of those six, five were culture- and/or PCR-positive for *M. agassizii*, and one was culture- and PCR-negative. Of the 10 ill tortoises, nine were seropositive by the ELISA and one was in the suspect range. Nine of the ill tortoises, including the suspect tortoise, were culture- and/or PCR-positive for *M. agassizii*, and one was culture- and PCR-negative. For histologic evaluation and discussion, the eight sero-, culture-, and PCR-negative tortoises were designated URTD-negative, and the other 16 were classified as URTD-positive. Histologic evaluation of the upper respiratory tract (URT) indicated the presence of mild to severe inflammatory, hyperplastic, or dysplastic changes in 14 URTD-positive tortoises. Seven of eight URTD-negative tortoises had normal appearing nasal cavities; one had mild inflammatory changes. Transmission electron microscopy revealed an organism consistent with *Mycoplasma* spp. on the nasal mucosal surface of tortoises with clinical signs and lesions of URTD. Additionally, Gram-negative bacteria were isolated more frequently from the nasal cavities of URTD-positive tortoises than URTD-negative tortoises. Because clinical signs of URTD were never observed in six of the URTD-positive tortoises, we also conclude that subclinical URTD can occur in gopher tortoises.

**Key words:** Gopher Tortoise, *Gopherus polyphemus*, *Mycoplasma agassizii*, upper respiratory tract disease, pathology.

### **INTRODUCTION**

Rhinitis and upper respiratory tract disease (URTD) have been reported in a variety of species of wild and captive tortoises in the USA (Jacobson et al., 1991) and Europe (Lawrence and Needham, 1985). Several agents have been hypothesized to cause respiratory tract disease in tortoises, including viruses (Jackson and Needham, 1983), *Mycoplasma* sp. (Fowler, 1980; Lawrence and Needham, 1985), and *Pasteurella* sp. (Snipes et al., 1980). Herpesviruses (Lange et al., 1989; Müller et al.,

1990; Kabisch and Frost, 1994) and iridoviruses (Müller et al., 1988) have been associated with rhinitis, glossitis, pharyngitis, pneumonia, and death in Mediterranean (*Testudo graeca* and *T. hermanni*) and Russian tortoises [*T. (Agrionemys) horsfieldii*] in Europe.

In the late 1980s, an upper respiratory tract disease was recognized for the first time in free-ranging desert tortoises (*Gopherus agassizii*) in the Mojave Desert of the southwestern USA (Jacobson et al., 1991). A mycoplasma, provisionally named

*Mycoplasma agassizii*, was isolated from ill tortoises and, through transmission studies, was determined to be a cause of URTD in desert tortoises (Brown et al, 1994)

Although URTD had been seen in captive gopher tortoises since the late 1970's (E. R. Jacobson, unpubl. data), the first documentation of the disease in wild gopher tortoises was in 1989, when an epizootic of URTD was documented on Sanibel Island (Lee County, Florida, USA; G. S. McLaughlin and M. S. Elie, unpubl. data), during the course of an ecological study (McLaughlin, 1990). When tested by ELISA, >80% of the adult tortoises from Sanibel Island were seropositive for antibodies against *M. agassizii* (Beyer, 1993).

Due to the 1979 listing by the Florida Game and Fresh Water Fish Commission (Tallahassee, Florida, USA) of the gopher tortoise as a species of special concern, and the subsequent permitting of over 450 relocations involving more than 8,000 tortoises (J. E. Berish, pers. commun.), attention has been focused, in particular, on the dynamics and persistence of both natural and relocated populations (Cox, 1989). The observation of URTD on Sanibel Island and the association of mycoplasmosis with declines of certain desert tortoise populations in the Mojave Desert (California, USA) elicited concerns regarding declining and isolated populations of gopher tortoises. Because an understanding of the effects of URTD on both individuals and populations is essential for proper management of remaining populations, a study was begun in 1993 on the etiology, pathology, and diagnosis of URTD in gopher tortoises. In this paper, we report the results of pathological, serological, and microbiological examinations of gopher tortoises with and without clinical signs of URTD from multiple locations in Florida.

#### MATERIALS AND METHODS

Twenty-four gopher tortoises from the following locations in Florida were transported to the University of Florida (UF, Gainesville,

Florida, USA) from August 1993 to September 1995. They come from Alachua County (29°42'N, 82°18'W;  $n = 2$ ), Sanibel Island, Lee County (26°26'N, 82°6'W;  $n = 3$ ), Volusia County (29°4'N, 81°16'W;  $n = 1$ ), St. Lucie County (27°23'N, 80°25'W;  $n = 1$ ), Indian River County (27°44'N, 80°34'W;  $n = 1$ ), Orange and/or Osceola Counties (28°21'N, 81°34'W;  $n = 16$ ). Collection of tortoises, except those from Orange and Osceola counties, was opportunistic, and consisted of submissions to the UF Veterinary Medical Teaching Hospital (VMTH), or other veterinary clinics in Florida. Some tortoises had clinical signs of URTD, (i.e., nasal and ocular discharge, occlusion of nares by caseous exudate, palpebral edema, and conjunctivitis) while others lacked specific signs but were traumatized by automobiles. Tortoises from Orange and Osceola counties were selected on the basis of clinical evaluations from a group of tortoises destined for relocation. Tortoises from all sites were evaluated for clinical signs of URTD and those exhibiting one or more signs or with a past history of clinical signs were designated as ill ( $n = 10$ ). Tortoises were designated healthy ( $n = 14$ ) if they were free of any history of or current signs of URTD, regardless of other disease conditions.

All tortoises were euthanatized with a combination of drugs. Ketamine hydrochloride (Ketaset®, Fort Dodge Laboratories, Inc., Fort Dodge, Iowa, USA) was administered intramuscularly at 60–80 mg/kg, followed by a concentrated barbiturate solution (Socumb, The Butler Company, Columbus, Ohio, USA) intracoeleomically at 1 ml/kg. Once the tortoises showed complete muscle relaxation and were unresponsive to painful stimulation, they were exsanguinated via a 23 gauge butterfly catheter inserted into the carotid artery, and then decapitated. Nasal passage lavage samples were collected by flushing approximately 0.5 ml sterile SP4 broth (Tully et al., 1979) into and out of the nares by using a 1 ml tuberculin syringe with no needle attached. Nasal passage swab samples were collected by using calcium alginate swabs which were then streaked onto SP4 agar plates (Tully et al., 1979). Following lavage and swab collection, the head including the nasal septum was bisected longitudinally with an electric saw which was thoroughly cleaned and the blades sanitized with alcohol after each use. The cartilage over each nasal cavity was reflected aseptically, and flushes and swabs of both left and right nasal cavities were collected as described above. Additionally, swab samples for aerobic bacteria isolation were collected from 16 tortoises (see below).

Heads were fixed in 10% neutral buffered formalin (NBF), decalcified, embedded in par-

affin, sectioned longitudinally at 5 to 6  $\mu\text{m}$ , and stained with hematoxylin and eosin (H&E). Sections were examined by light microscopy and classified on a scale of 0 to 5, with 0 being normal and 5 exhibiting severe inflammation and structural changes. The scale was previously developed for grading changes in the nasal cavity tissues of desert tortoises with mycoplasmosis (Jacobson et al., 1995). Changes in the epithelium and submucosa were recorded separately.

The following criteria were utilized for grading lesions. *Normal* was when there were occasional small subepithelial lymphoid aggregates, rare heterophils in the lamina propria, no changes in mucosal or glandular epithelium, and no edema. *Mild changes* were those that had small multifocal subepithelial lymphoid aggregates, small numbers of heterophils, lymphocytes, and plasma cells in the lamina propria, mild edema in the lamina propria, and mild changes in the structure of the mucosal epithelium. *Moderate changes* were those that had multifocally to focally extensive subepithelial lymphoid aggregates, diffuse moderate numbers of heterophils, lymphocytes, and plasma cells in the lamina propria, occasionally infiltrating the overlying mucosal epithelium, moderate edema in the lamina propria, and proliferation and disorganization of the basal epithelium. *Severe changes* were those that had focally extensive to diffuse bands of lymphocytes and plasma cells subjacent to and obscuring the overlying mucosal epithelium, large numbers of heterophils in the lamina propria and infiltrates in the overlying mucosal epithelium, marked edema of the lamina propria, degeneration, necrosis, and loss of the mucosal epithelium with occasional erosion, proliferation of the basal cells of the epithelium with metaplasia of the mucous and olfactory epithelium to a basaloid epithelium, and occasional squamous metaplasia of the mucous epithelium.

Samples from eight ill and four healthy tortoises were collected for transmission electron microscopy (TEM). The nasal cavity mucosal tissue was removed from the underlying cartilaginous tissues and separated into anterior dorsal, anterior ventral, posterior dorsal and posterior ventral quadrants. Each quadrant was cut into 1 mm cubes and placed in 2.5% glutaraldehyde, and post-fixed in osmium tetroxide. Specimens were prepared for TEM by embedding in epon-araldite and sectioning with an ultramicrotome. Thick sections were stained with toluidine blue and examined by light microscopy. Ultrathin sections were placed on copper grids, stained with uranyl acetate and lead citrate, and examined with a Hitachi

H7000 transmission electron microscope (Hitachi America, Ltd., San Diego, California, USA) operated at 75 kv.

Of the 24 gopher tortoises, gross necropsies were conducted on 21; only the heads of the three remaining tortoises were examined. Of the 21 tortoises necropsied, multiple tissues were collected from 15 tortoises and only the heads and livers from six. For those tortoises selected for gross necropsy (ill,  $n = 15$ ; healthy,  $n = 6$ ), the plastron was removed from the carapace, and viscera within the coelomic cavity were exposed. For those tortoises for which complete necropsies were conducted, the following tissues were collected, fixed in neutral buffered 10% formalin, sectioned at 5 to 6  $\mu\text{m}$ , and stained with hematoxylin and eosin: glottis, cranial trachea, tracheal bifurcation, left lung, right lung, thyroid, heart, brain, thymus, esophagus, stomach, small intestine, pancreas, large intestine, cloaca, spleen, liver, left and right kidney, urinary bladder, right and left gonads, chin (mental) gland, buccal salivary gland, and tongue. Liver sections also were stained with Perl's iron stain (Luna, 1968). Tissues were examined by light microscopy and abnormalities or changes were recorded.

The nasal lavage samples were serially diluted ten-fold to  $10^{-2}$  and incubated at 30°C for a maximum of 3 wk, or until determined to be positive or contaminated. Twenty  $\mu\text{l}$  of each dilution were placed on SP4 agar and incubated at 30 C and 5%  $\text{CO}_2$ , as were the streak plates. Plates were examined regularly for a maximum of 6 wk to detect the growth of mycoplasma.

Swab specimens of the nasal cavities of healthy ( $n = 5$ ) and ill ( $n = 11$ ) tortoises were collected for aerobic bacterial isolation attempts. Samples were cultured on Columbia blood agar (Remel, Lenexa, Kansas, USA) and MacConkey agar (Remel, Lenexa, Kansas, USA), and incubated at 37 C. Bacteria were identified utilizing the identification systems API 20E for enteric organisms and API NFT for non-enterics (BioMerieux Vitek, Hazelwood, Missouri, USA). Isolates of organisms consistent with *Pasteurella* spp. were identified to species according to biochemical profiles listed for *P. testudinis* (Snipes and Biberstein, 1982).

A 100  $\mu\text{l}$  aliquot of each nasal lavage sample was analyzed for the presence of *M. agassizii* DNA based upon polymerase chain reaction (PCR) amplification of the 16S rRNA gene (Brown et al., 1995). Samples were centrifuged for 60 min at 16,000 RCF at 4 C, and the supernatant aspirated. Three to four microliters of 20  $\mu\text{g/ml}$  proteinase K (Sigma, St. Louis, Missouri, USA) and 20  $\mu\text{l}$  lysis buffer (100 mM tris pH 7.5, 6.5 mM DTT, 0.05% Tween 20)

were added to the pellets, which were resuspended, and the samples were incubated at 37 C for 8 to 16 hr. After denaturing the proteinase K at 97 C for 15 min, 5  $\mu$ l of each sample were removed and added to 45  $\mu$ l of reaction solution containing two primers for the 16S rRNA gene at 1  $\mu$ M each, deoxynucleoside triphosphates at 200  $\mu$ M, 2.0 mM MgCl<sub>2</sub>, and 2.5 units of *Taq* polymerase (Promega, Madison, Wisconsin, USA). The primers were complementary to sequences found in the V3 variable region of the 16S rRNA gene [sense strand nucleotides (nt) 471 to 490, 5'-CCTATATTATGACGGTACTG-3'; Brown et al., 1995] and a *Mycoplasma* genus-specific region [anti-sense strand nt 1055 to 1031, 5'-TGCACCATCTGTCACTCTGTAACTC-3'; Van Kuppeveld et al., 1992]. Samples were subjected to 50 cycles of template denaturation for 45 sec at 94 C, primer annealing for 1 min at 55 C, and polymerization for 45 sec at 72 C, followed by 10 min at 72 C. Positive samples yielded 576 base pair (bp) products that were visualized by combining 15  $\mu$ l of product with 2  $\mu$ l bromophenol blue in 50% glycerol solution and electrophoresing on ethidium bromide-stained 1.5% agarose gels in tris-borate-EDTA buffer. Positive control samples, with 250 ng of purified *M. agassizii* DNA as the template, and negative control samples, with water in place of a template, were included with each amplification run. A molecular size marker, Hae III digest of  $\phi$ X phage DNA (Promega, Madison, Wisconsin, USA), was included on each gel.

In order to confirm that the isolates obtained from naturally and experimentally infected tortoises were *M. agassizii*, an additional procedure, restriction fragment length polymorphism (RFLP) analysis, was conducted on at least one isolate from each tortoise. Twenty microliter samples of products from the above amplification procedure were incubated with 10 to 20 units of the endonuclease AgeI (New England Biolabs, Inc., Beverly, Massachusetts, USA), which cuts the *M. agassizii* amplification product at nt 613, at 25 C for 1 hr, and the products electrophoresed as above. The procedure resulted in products of 434 and 142 bp from *M. agassizii*-positive samples, and no change in non-*M. agassizii* samples.

An aliquot of plasma from each blood sample was used in an ELISA for determinations of levels of antibodies specific for *M. agassizii* (Schumacher et al., 1993). Ninety-six-well microtiter plates (Maxisorp F96, Nunc, Kamstrup, Denmark) were coated with 50  $\mu$ l of a whole-cell lysate of *M. agassizii* strain 723 at 10  $\mu$ g/ml in phosphate buffered saline with 0.02% azide (PBS-AZ). Plates were incubated overnight at 4C, washed four times with PBS-AZ plus

0.05% Tween 20 (PBST) in an automatic plate washer (EL403, Bio-Tek Instruments, Inc., Winooski, Vermont, USA), and blocked overnight at 4 C with 250  $\mu$ l/well PBST containing 5% non-fat dry milk (PBS-TM). Following washing, 50  $\mu$ l of plasma diluted appropriately for the specific study with PBS-TM were added to individual wells in duplicate or triplicate, and the plates were incubated at room temperature for 60 min. The plates were washed, 50  $\mu$ l/well of a biotinylated monoclonal antibody (MAB HL673) against the light chain of desert tortoise immunoglobulins IgY and IgM at 1  $\mu$ g/ml in PBS-TM was added, and plates were incubated for 60 min. Following washing, a conjugate of alkaline phosphatase and streptavidin (AP-S; Zymed Laboratories, Inc., San Francisco, California, USA) at 1:2,000 in PBS-AZ was added at 50  $\mu$ l/well, plates were incubated for 60 min, and washed. Substrate, *p*-nitrophenyl phosphate disodium (*p*NPP; Sigma), was prepared at 1 mg/ml in 0.01 M sodium bicarbonate, pH 9.6, with 2 mM MgCl<sub>2</sub>, and added to wells at 100  $\mu$ l/well. Plates were incubated for 60 min in the dark, then read at 405 nm on a microplate reader (EAR 400 AT, SLT Labinstruments, Salzburg, Austria). The mean of two or three wells coated with antigen and incubated with conjugate and substrate only was used as the blank. A positive control, plasma from a naturally infected gopher tortoise from Sanibel Island, and a negative control, plasma from an uninfected tortoise from Orange County, were included on each plate.

Results from the ELISA were optical density (OD) readings from the microplate reader. The OD readings reflected the intensity of the yellow color developed when all components of the reaction (specific tortoise antibodies against *M. agassizii*, biotinylated MAB HL673, AP-S, and *p*NPP) were present. The readings were on a continuous scale, but were interpreted categorically by calculating the ratio of the sample readings to the negative control reading. Ratio values less than or equal to 2.0 were considered negative, those > 2.0 and  $\leq$  3.0 were classified as suspect, and those > 3.0 were classified as positive.

## RESULTS

Based on diagnostic tests, all 10 of the tortoises originally classified as ill were determined to be affected by URTD (Table 1). Nine were seropositive by the ELISA and one was in the suspect range. Eight ill tortoises were culture- and PCR-positive, one was culture-negative but PCR-positive, and one was culture- and PCR-neg-

TABLE 1. Enzyme linked immunosorbent assay (ELISA), polymerase chain reaction (PCR), culture, and nasal histopathology results from necropsied gopher tortoises from various locations in Florida (USA), for determining infection with *Mycoplasma agassizii*.

Tortoises without clinical signs of URTD <sup>a</sup>					Tortoises with clinical signs of URTD				
ID	ELISA	Culture	PCR	Histopathology	ID	ELISA	Culture	PCR	Histopathology
94-15	—	—	—	normal	93-67	+	+	+	severe
94-16	+	—	—	severe	93-74	+	—	+	severe
94-17	—	—	—	normal	94-29	+	+	+	mild
94-18	—	—	—	normal	94-30	+	+	+	moderate
94-32	—	—	—	normal	94-44	+	+	+	severe
94-37	—	—	—	normal	94-45	+	+	+	moderate
94-49	+	+	+	mild	94-47	+	—	—	normal
94-50	+	—	+	moderate	94-48	+	+	+	severe
94-51	—	—	—	mild	95-11	s <sup>b</sup>	+	+	moderate
95-07	+	+	+	moderate	95-23	+	+	+	mild
95-21	+	+	—	mild					
95-22	+	+	—	mild					
95-40	—	—	—	normal					
95-43	—	—	—	normal					
Total	43% <sup>c</sup>	29%	21%	50%		90%	80%	90%	90%

<sup>a</sup> Upper respiratory tract disease.

<sup>b</sup> Suspect.

<sup>c</sup> Totals are percent of tortoises with or without clinical signs that were positive for that parameter.

ative. Of the 14 clinically healthy tortoises, six tortoises were seropositive for antibodies against *M. agassizii*. Of those six, two were culture- and PCR-positive, two were culture-positive but PCR-negative, one was culture-negative but PCR-positive,

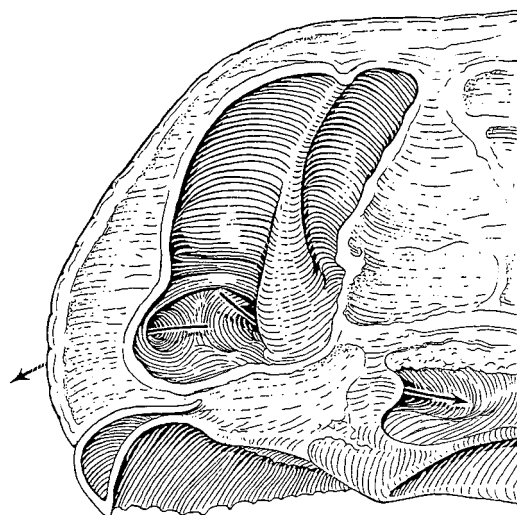


FIGURE 1. Diagrammatic representation of the interior of a gopher tortoise head sectioned longitudinally, illustrating the relationship of the nasal cavity to the external and internal nares.

and one was culture- and PCR-negative. For histological evaluation and further discussion, the eight clinically healthy, seronegative, and culture- and PCR-negative for *M. agassizii* were designated as URTD-negative, and the remaining 16 tortoises were designated as URTD-positive.

The URT consisted of external nares that opened into ventro-lateral depressions, which were continuous with large dorsal nasal cavities (Fig. 1). Right and left dorsal nasal cavities were separated by a cartilaginous septum. Each nasal cavity was bisected by a ridge, forming larger anterior and smaller posterior compartments. Ventrally, the nasal passageways were continuous with the ventromedial choanae (internal nares), which opened into the palatine region of the dorsal nasopharyngeal cavity.

The integument continued through the external nares into a short vestibule, which was initially lined by keratinized stratified squamous epithelium. That epithelium abruptly changed to mucous glandular epithelium, which lined the nasal passageway throughout its length. Interspersed among

the mucous epithelial cells were ciliated epithelial cells. The ventro-lateral depression was lined primarily by mucous and ciliated epithelial cells. Both anterior and posterior dorsal nasal chambers were lined by a multilayered olfactory epithelium with occasional mucous cells. Numerous serous and mucous glands, vessels, nerve bundles, and clusters of melanophores were present in the connective tissue surrounding the nasal cavities. Small focal aggregates of lymphoid cells were seen in the submucosa.

Of the eight URTD-negative tortoises examined, multiple foreign bodies consistent with plant material were seen in the submucosa of the glottis of three tortoises, in the tongue of one tortoise, and in the buccal salivary gland of one tortoise. Lymphoid aggregates were scattered throughout the esophagus, small intestine, large intestine and cloaca, and also were present in the connective tissue surrounding the mental (chin) glands.

Gross observations revealed fat was in the pleuro-peritoneal cavity, particularly around the great vessels lateral to the heart, and in the axillary and inguinal regions. The bilateral multilobular thymus glands were located cranial to the base of the heart, at the branching of the subclavian and carotid arteries. By light microscopy, there was a typically dark staining cortex and a lighter staining medulla. The cortex contained many densely packed thymocytes. In the medulla there were significantly fewer cells including thymocytes, thymic epithelial cells, myoid cells, and heterophils.

The thyroid was located at the base of the heart, and was not associated with the thymus. In one of the URTD-negative tortoises, the thyroid was enlarged, with multifocal areas of follicular epithelial cell hyperplasia. In all tortoises, follicles varied in size, with many having numerous red blood cells in the colloid and either intra-epithelial or supra-epithelial vacuoles.

The spleen was located on the right side, between the proximal duodenum and

transverse colon and was associated closely with pancreatic tissue. Histologically, spleens were composed of distinct areas of white and red pulp. White pulp consisted of collections of lymphoid tissue surrounding blood vessels. Red pulp, located between the perivascular collections of the white pulp, included red blood cells within sinusoids and small numbers of lymphocytes. No abnormalities were seen in the spleens of any URTD-negative tortoises examined.

Livers of healthy tortoises were dark brown. Using Perl's iron stain, no iron was observed in the liver of one tortoise, a minimal amount of iron was observed in the livers of four tortoises, and moderate to abundant amounts of iron were observed in the liver of one tortoise. Four tortoises had low numbers of small melanomacrophages, one had moderate numbers of melanomacrophages, and in one the melanomacrophages were large and more numerous.

Three URTD-positive tortoises had petechial to ecchymotic hemorrhages under the dermal scutes. Ill tortoises often presented with, or had a history of, lethargy, anorexia, or abnormal activity patterns. Gross examination revealed URTD-affected tortoises to have less fat than healthy tortoises, and the thymus glands were smaller and difficult to locate. Gross examination of heads of ill tortoises revealed minimal to large amounts of exudate within the nasal cavity and nasal passageways. In some tortoises, caseous exudate occluded the nasal cavity. By light microscopy, of the 16 heads, two had no changes, three had mild changes, six had moderate changes, and five had severe inflammatory changes in the nasal cavity. In the tortoises with mild changes, mild mucosal hyperplasia and slightly increased lymphoid aggregates were seen in the nasal passage and ventro-lateral depression. In those tortoises with moderate changes, mild mucosal hyperplasia and slightly increased lymphoid aggregates were seen in the nasal passage and ventro-lateral depression.

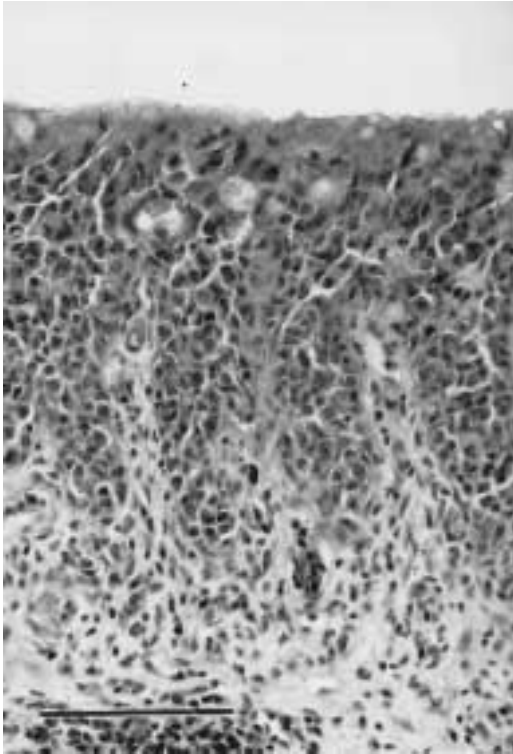


FIGURE 2. Photomicrograph of the nasal cavity tissues of a gopher tortoise with upper respiratory tract disease. The changes were classified as severe, with aggregates of lymphoid cells in the submucosa, proliferation of the basal cells, and dysplasia of the mucosal epithelium. H&E. Bar = 100  $\mu$ m.

In those tortoises with moderate changes, lesions generally were confined to the nasal passage and the ventral aspects of the nasal cavities, and consisted of mucosal epithelial and lymphoid hyperplasia, with infiltration of mononuclear cells and heterophils. In some tortoises with moderate inflammation, basal cell proliferation and loss of cilia could be detected. In the tortoises with severe inflammatory changes (Fig. 2), there were lymphoid aggregates around submucosal glands, with glandular epithelial hyperplasia. The normal mucosal architecture was replaced by infiltrates of mononuclear cells and heterophils. The olfactory mucosa was replaced with proliferating mucous epithelial cells. Proliferating basal cells projected into the underlying lamina propria of some tortoises. Ex-

udate, consisting of sloughed epithelial cells and inflammatory cells, was found in the nasal cavity lumen.

Seven ill tortoises had inflammatory changes in the submucosa of the glottis, ranging from focal lymphoid aggregates to hyperplasia of mucosal epithelial cells. These changes were not associated with foreign bodies. Basal cell proliferation and submucosal lymphoid hyperplasia were seen in the glottis of one tortoise, with hyperplasia extending into the cranial tracheal epithelium. In that tortoise, there also were multifocal areas of alveolar epithelial cell hyperplasia in the lung. Two other tortoises also had foci of epithelial hyperplasia in the trachea. Five other ill tortoises had focal to multifocal lymphoid aggregates in the lung interstitia.

The gastrointestinal tracts of ill tortoises had increased numbers and larger lymphoid aggregates in the submucosa compared to those of clinically healthy tortoises. In one ill tortoise there was mucous cell hyperplasia of the colon and in another there was a severe colitis with epithelial cell hyperplasia and submucosal lymphoid hyperplasia, with infiltrates of large numbers of heterophils. Four other ill tortoises had increased lymphoid aggregates in the esophagus, stomach and/or small intestine. Three additional tortoises had increased numbers and larger lymphoid aggregates in the submucosa of the cloaca.

The spleens of 11 URTD-positive tortoises were examined. Of these, lymphoid hyperplasia was seen in the white pulp of three. Heterophils were found infiltrating the splenic tissues in three other tortoises. In one tortoise the follicles were small, with an increase in the amount of red pulp.

Grossly, changes were seen in the livers of eight tortoises positive for URTD. In one, the liver was atrophied and darker than normal, while in three, the livers were enlarged and pale pink to tan colored; one of those had fibrin on the surface. The livers of three tortoises were mottled with gray to black and had rough-



ened surfaces. Two animals had focal white to cream colored lesions approximately 1 mm in diameter on the surface of the livers. By light microscopy, one tortoise with a grossly normal appearing liver had perivascular cuffing of the central vein by lymphocytes and heterophils.

Using H&E staining, melanomacrophages were scattered throughout the liver and golden-brown intracytoplasmic granules were seen within hepatocytes and Kupffer cells of most URTD-positive tortoises. The intracytoplasmic granules stained positive using Perl's iron stain. Two tortoises had no detectable iron, four had moderate amounts of iron, and in four the iron was abundant. The kidneys of all ill tortoises contained golden brown granules within renal epithelial cells that were similar to those seen in H&E stained tissue sections of liver.

Using TEM, one tortoise from Sanibel Island and another from Indian River County had organisms consistent with *Mycoplasma* spp. closely associated with nasal mucosa cell membranes (Fig. 3). Associated epithelial cells had vacuolated cytoplasm and inflammatory cell infiltrates were present in the mucosa. Increased numbers of mucous epithelial cells were seen and were consistent with light microscopic findings.

The aerobic microbial isolates of healthy tortoises consisted primarily of members of the genera *Staphylococcus*, *Streptococcus*, and *Corynebacterium* (75% of total isolates); a few Gram-negative rods were isolated (25%). A greater number of Gram-negative bacteria were isolated from the nasal cavities of tortoises with URTD, and those isolates made up a greater proportion of the isolates (40%). *Pasteurella testudinis* was not isolated from URTD negative tortoises but was isolated from five URTD positive tortoises; in two it represented the major aerobic isolate.

#### DISCUSSION

Gopher tortoises with clinical signs of URTD and evidence of infection by or ex-

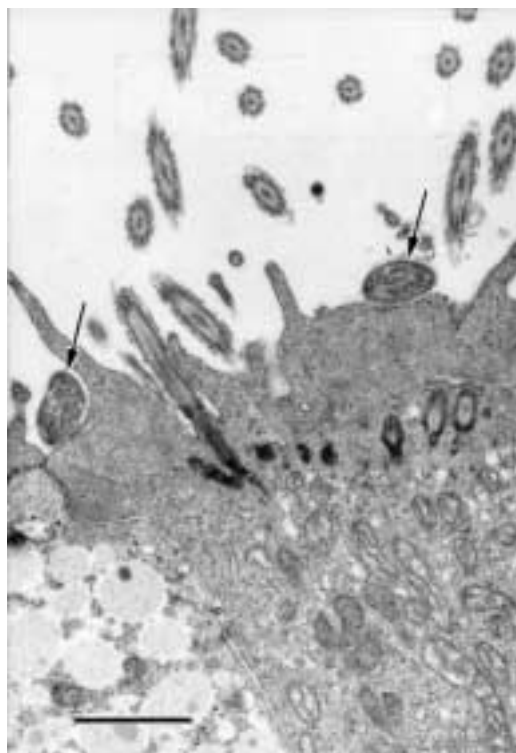


FIGURE 3. Transmission electron photomicrograph of the nasal cavity mucosa of a gopher tortoise with upper respiratory tract disease. Organisms consistent with *Mycoplasma* spp. (arrow) can be seen in close association with membranes of a ciliated cell. Lead citrate and uranyl acetate. Bar = 1  $\mu$ m.

posure to *M. agassizii* were obtained from multiple sites in Florida. Clinical URTD was seen in 10 tortoises, all of which tested suspect or positive by an ELISA. Eight (80%) of the ill tortoises were positive by culture and nine (90%) were positive by PCR. Six of 14 (43%) healthy appearing tortoises were seropositive by ELISA. In five of those six (83%), *M. agassizii* were detected by culture ( $n = 4$ , 67%) or PCR ( $n = 3$ , 50%). Collectively, ten (62%) of the URTD-positive gopher tortoises were both culture- and PCR positive for *M. agassizii*, two (12%) were culture-positive and PCR-negative, two (12%) were culture-negative and PCR-positive, and two (12%) were both culture- and PCR-negative. By TEM, organisms consistent with *Mycoplasma* spp. were demonstrated on

the nasal mucosal surfaces of two tortoises. Other than aerobic bacteria, no infectious agents were demonstrated in or on nasal cavity mucosa by TEM. Recent transmission studies confirmed *M. agassizii* as a cause of URTD in the gopher tortoise (Brown et al. 1999).

Jacobson et al. (1995) examined clinically healthy and clinically ill desert tortoises from Las Vegas Valley (Nevada, USA) and found that in the ill tortoises, 92% had lesions of URTD, 50% were culture positive for *M. agassizii*, and 100% of the serum samples reacted positively in the ELISA. However, 73% of the clinically healthy tortoises had lesions consistent with URTD, 50% were culture positive for *M. agassizii*, and 42% were seropositive for antibodies against the bacteria. Thus, although infections with *M. agassizii* does cause URTD (Brown et al., 1994), it is clear that subclinical mycoplasmosis can occur in a substantial proportion of a wild desert tortoise population. Similarly, subclinical URTD was seen in gopher tortoises in our study. Of the 10 ill tortoises, 90% had lesions, were ELISA positive and were culture or PCR positive for *M. agassizii*. However, 50% of clinically healthy tortoises had lesions consistent with URTD, 43% were seropositive, and 36% were culture or PCR positive.

As in desert tortoises with URTD (Brown et al., 1994), clinical signs varied among gopher tortoises with URTD. In some tortoises, one or both nares were occluded with caseous exudate, preventing externally visible nasal discharge. Although the impact of the disease on tortoise behavior has not been characterized, the changes probably interfere with tortoises' ability to forage. Lethargy, nonresponsiveness to stimuli, and altered behavior patterns—such as basking at lower temperatures than normal—may render a tortoise more susceptible to predation. Anorexia and reduced foraging (Brown et al., 1994) could lead to malnutrition, reduced reproduction, cachexia, and death.

By ELISA, 16 tortoises, including 10

clinically ill and six clinically healthy animals, had antibodies against *M. agassizii*, indicating current or previous exposure. One clinically ill tortoise with an ELISA ratio in the suspect range, but with positive culture and PCR results, may have been in the early stages of the disease, when antibody levels were just beginning to increase. The one clinically ill tortoise with a positive ELISA but negative culture and PCR results may have cleared the mycoplasma and developed signs in response to other pathogens or environmental irritants. Alternatively, it may have been at a stage in the disease when mycoplasma numbers were low. We have found that the number of mycoplasma shed can vary on a daily basis.

The greater number of species and increased proportion of Gram-negative bacteria isolated from ill gopher tortoises as compared to healthy ones could indicate that conditions in the URT of diseased tortoises are more favorable for the growth of those bacteria, or that tortoises infected with *M. agassizii* are more susceptible to secondary invaders. In particular, *Pasteurella testudinis* was isolated more frequently from ill than healthy gopher tortoises. The positive *Mycoplasma* spp. culture and/or PCR results from nasal cavity samples (obtained at necropsy) of four clinically healthy tortoises with negative nasal passage flushes and swabs support the hypothesis that tortoises can harbor the organism without showing clinical signs or shedding mycoplasma. Such animals may recrudescence under stressful conditions, begin shedding bacteria, and become infective to other tortoises. Several moribund animals developed petechial to ecchymotic hemorrhages under the scutes that may have been due to septicemia caused by secondary infection with opportunistic bacteria. However, blood cultures were not obtained from these tortoises, and the responsible organism was not identified. Westhouse et al. (1996) implicated an iridovirus as a cause of pneumonia, tracheitis, pharyngitis, and esophagitis

in a gopher tortoise from Sanibel Island. Intracytoplasmic inclusions were seen by light microscopy and particles morphologically compatible with iridovirus were seen by electron microscopy. No indications of viral infection were seen in any tortoise examined by light or electron microscopy in the current study.

In gopher tortoises with URTD, the light microscopic changes in the URT were similar to inflammatory and dysplastic changes reported for desert tortoises with URTD (Jacobson et al., 1991). Inflammation and epithelial proliferation around the glottis, tracheitis, proliferative pneumonia, and colonic mucosal cell proliferations in gopher tortoises have not been reported in desert tortoises with URTD. In this study, infected gopher tortoises appeared to have less fat than URTD-negative animals, and had atrophied thymuses, increased numbers of lymphocytes in the sinusoids of the spleens, and increased deposition of iron within hepatocytes and Kupffer cells. These changes may represent a response to chronic infection. Similar findings have been described from desert tortoises with URTD (Jacobson et al., 1991; Brown et al., 1994; Jacobson et al., 1995). Hemosiderosis, while often of undetermined origin, has been associated with bacterial infections (Munson et al., 1991) and exposure to toxins (Khan and Nag, 1993). Iron serves as a nutrient for invading microbes and sequestering iron is a mechanism for limiting the growth of these microbes (Weinberg, 1984). A hypoferremic response to infection is known to occur in the lizard, *Dipsosaurus dorsalis* (Hacker et al., 1981).

We have seen an annual cycle of convalescence and recrudescence of clinical signs in some captive desert and gopher tortoises. Other mycoplasmal diseases also can exist as chronic, subclinical infections, with recurrence of clinical signs and increases in transmission potential when the host is stressed (Simecka et al., 1992). Although data are lacking, various environ-

mental perturbations may influence the periodicity of outbreaks. Annual fluctuations in temperature, rainfall, and forage availability may be sufficient to cause detectable outbreaks in an infected population. Increased morbidity and mortality may occur in times of unusually severe environmental stress, such as prolonged drought, hurricanes, excessive rainfall with flooding of burrows, or very cold winters. Human impacts on tortoises and their habitat, whether through disruption of normal behavior patterns, degradation of habitat through agriculture, silviculture, mining or development operations, or pollution, may cause sufficient physiological stress to trigger proliferation of the mycoplasma and recurrence of signs. Capturing and transporting of tortoises during relocation, restocking and repatriation efforts also may be significant sources of stress that result in overt disease. The release of ill captive tortoises may be a significant factor accounting for the presence of URTD in certain populations. For instance, gopher tortoises originating in northern Florida and southern Georgia were released onto Sanibel Island following numerous tortoise races. Many of those tortoises were kept under very poor husbandry conditions that would have allowed transmission of various pathogens (Dietlein and Smith, 1979).

The effects of mycoplasmosis on the long-term health and viability of affected populations are poorly understood. Based on data collected on Sanibel Island (McLaughlin, 1990), subsequent censuses, and submissions to VMTH, at least 30% and possibly up to 50% of the adults on one site died with signs of URTD. Given the low recruitment rates of gopher tortoise populations (Cox, 1989), it is unlikely that the population on that site will recover to its previous levels without intensive management.

#### ACKNOWLEDGMENTS

This study was funded by a grant from The Walt Disney Company. We thank B. C. Crenshaw, S. J. Tucker, J. Hutchison, A. White-

marsh, and M. Lao for their technical assistance, and L. Mallory for the drawing of the tortoise head. We also thank the staff of the Clinical Microbiology and Pathology and Laboratory at VMTH, College of Veterinary Medicine, University of Florida for their contributions.

#### LITERATURE CITED

- BEYER, S. M. 1993. Habitat relations of juvenile gopher tortoises and a preliminary report of upper respiratory tract disease (URTD) in gopher tortoises. M.S. Thesis, Iowa State University, Ames, Iowa, 95 pp.
- BROWN, D. R., B. C. CRENSHAW, G. S. McLAUGHLIN, I. M. SCHUMACHER, C. E. MCKENNA, P. A. KLEIN, E. R. JACOBSON, AND M. B. BROWN. 1995. Taxonomy of the tortoise mycoplasmas *Mycoplasma agassizii* and *Mycoplasma testudinis* by 16S rRNA gene sequence comparisons. *International Journal of Systematic Bacteriology* 45: 348–350.
- BROWN, M. B., I. M. SCHUMACHER, P. A. KLEIN, K. HARRIS, T. CORRELL, AND E. R. JACOBSON. 1994. *Mycoplasma agassizii* causes upper respiratory tract disease in the desert tortoise. *Infection and Immunity* 62: 4580–4586.
- , G. S. McLAUGHLIN, P. A. KLEIN, B. C. CRENSHAW, I. M. SCHUMACHER, D. R. BROWN, AND E. R. JACOBSON. 1999. Upper respiratory tract disease in the Gopher Tortoise is caused by *Mycoplasma agassizii*. *Journal of Clinical Microbiology* 37: 2262–2269.
- COX, J. 1989. Survival characteristics of small gopher tortoise populations and their possible influence on relocation efforts. *In* Gopher tortoise relocation symposium proceedings, J. E. Diemer, D. R. Jackson, J. L. Landers, J. N. Layne, and D. A. Wood (eds.). Florida Game and Fresh Water Fish Commission, Nongame Wildlife Program Technical Report #5, Tallahassee, Florida, pp. 7–14.
- DIETLEIN, N. E., AND A. SMITH. 1979. Gopher tortoise races—what they mean to the tortoise. *In* Desert tortoise council proceedings 1979 Symposium, E. St. Amant (ed.). Desert Tortoise Council, Long Beach, California, pp. 181–185.
- FOWLER, M. E. 1980. Differential diagnosis of pneumonia in reptiles. *In* Reproductive biology and diseases of captive reptiles J. B. Murphy and J. T. Collins (eds.). Society for the Study of Amphibians and Reptiles, Lawrence, Kansas, pp. 227–233.
- HACKER, M. R., B. A. ROTHENBUR, AND M. J. KLUGER. 1981. Plasma iron, copper, and zinc in lizard *Dipsosaurus dorsalis*: effects of bacteria injection. *American Journal of Physiology (Regulatory Integrative Comparative Physiology 9)* 240: R 272–R 275.
- JACKSON, O. F., AND J. R. NEEDHAM. 1983. Rhinitis and virus antibody titers in chelonians. *Journal of Small Animal Practice* 24: 31–36.
- JACOBSON, E. R., J. M. GASKIN, M. B. BROWN, R. K. HARRIS, C. H. GARDINER, J. L. LAPOINTE, H. P. ADAMS, AND C. REGGIARDO. 1991. Chronic upper respiratory tract disease of free-ranging desert tortoises, *Xerobates agassizii*. *Journal of Wildlife Disease* 27: 296–316.
- , M. B. BROWN, I. M. SCHUMACHER, B. R. COLLINS, R. K. HARRIS, AND P. A. KLEIN. 1995. Mycoplasmosis and the desert tortoise (*Gopherus agassizii*) in Las Vegas Valley, Nevada. *Chelonian Conservation and Biology* 1: 280–284.
- KABISCH, D., AND J. W. FROST. 1994. Isolation of herpesvirus from *Testudo hermanni* and *Agrionemys horsfieldii*. *Verhandlungsbericht des Internationalen Symposiums über die Erkrankungen der Zoo- und Wildtiere* 36: 241–245.
- KHAN, R. A., AND K. NAG. 1993. Estimation of hemosiderosis in seabirds and fish exposed to petroleum. *Bulletin of Environmental Contamination and Toxicology* 50: 125–131.
- LANGE, H., W. HERBST, J. M. WIECHERT, AND T. SCHLETER. 1989. Elektronenmikroskopischer Nachweis von Herpesviren bei einem Massensterben von Griechischen Landschildkröten (*Testudo hermanni*) und Vierzehenschildkröten (*Agrionemys horsfieldii*). *Tierärztliche Praxis* 17: 319–321.
- LAWRENCE, K., AND J. R. NEEDHAM. 1985. Rhinitis in long-term captive Mediterranean tortoises (*Testudo graeca* and *T. hermanni*). *Veterinary Record* 117: 662–664.
- LUNA, L. G. 1968. *Manual of Histologic Staining Methods of the Armed Forces Institute of Pathology*. McGraw-Hill Book Company, New York, New York. 399 pp.
- McLAUGHLIN, G. S. 1990. Ecology of gopher tortoises (*Gopherus polyphemus*) on Sanibel Island, Florida. M.S. Thesis, Iowa State University, Ames, Iowa, 124 pp.
- MÜLLER, M., N. ZANGGER, AND T. DENZLER. 1988. Iridovirus-Epidemie bei der Griechischen Landschildkröte (*Testudo hermanni hermanni*). *Verhandlungsbericht de Internationalen Symposiums über die Erkrankungen der Zoo- und Wildtiere* 30: 271–274.
- , W. SACHSSE, AND N. ZANGGER. 1990. Herpesvirus-Epidemie bei der Griechischen (*Testudo hermanni*) und der Maurischen Landschildkröte (*Testudo graeca*) in der Schweiz. *Schweizer Archiv für Tierheilkunde* 132: 199–203.
- MUNSON, L., F. J. LUIBEL, AND H. J. VAN KRUINGEN. 1991. Siderophilic bodies associated with hemosiderosis and atypical mycobacterial infection in an island siamang (*Hylobates syndactylus*). *Journal of Medical Primatology* 20: 265–70.
- SCHUMACHER, I. M., M. B. BROWN, E. R. JACOBSON, B. R. COLLINS, AND P. A. KLEIN. 1993. Detec-

- tion of antibodies to a pathogenic mycoplasma in desert tortoises (*Gopherus agassizii*) with upper respiratory tract disease. *Journal of Clinical Microbiology* 31: 1454–1460.
- SIMECKA, J. W., J. K. DAVIS, M. K. DAVIDSON, S. E. ROSS, C. T. K. H. STÄDTLANDER, AND G. H. CASSELL. 1992. Mycoplasmas which infect animals. In *Mycoplasmas: molecular biology and pathogenesis*, Maniloff, J., R. N. McElhaney, L. R. Finch, J. B. Baseman (eds.). American Society for Microbiology, Washington, D. C., pp. 391–415.
- SNIPES, K. P., AND E. L. BIBERSTEIN. 1982. *Pasteurella testudinis* sp. nov.: A parasite of desert tortoises. *International Journal of Systematic Bacteriology* 32: 201–210.
- , E. L. BIBERSTEIN, AND M. E. FOWLER. 1980. A *Pasteurella* sp. Associated with respiratory disease in captive desert tortoises. *Journal of the American Veterinary Medical Association* 177: 804–807.
- TULLY, J. G., D. L. ROSE, R. F. WHITCOMB, AND R. P. WENZEL. 1979. Enhanced isolation of *Mycoplasma pneumoniae* from throat washings with a newly modified culture medium. *Journal of Infectious Diseases* 139: 478–482.
- VAN KUPPEVELD, F. J. M., J. T. M. VAN DER LOGT, A. F. ANGULO, M. J. VAN ZOEST, W. G. V. QUINT, H. G. M. NIESTERS, J. M. D. GALAMA, AND W. J. G. MELCHERS. 1992. Genus- and species-specific identification of mycoplasmas by 16s r RNA amplification. *Applied Environmental Microbiology* 58: 2602–2615.
- WESTHOUSE, R. A., E. R. JACOBSON, R. K. HARRIS, K. R. WINTER, AND B. L. HOMER. 1996. Respiratory and pharyngo-esophageal iridovirus infection in a gopher tortoise (*Gopherus polyphemus*). *Journal of Wildlife Diseases* 32: 682–686.
- WEINBERG, E. D. 1984. Iron withholding: A defense against infection and neoplasia. *Physiological Reviews* 64: 65–102.

*Received for publication 14 January 1998.*