

Proliferative Pododermatitis Associated with Virus-like Particles in a Northern Gannet

Authors: Daoust, Pierre-Yves, Wadowska, Dorota, Kibenge, Frederick, Campagnoli, Raymond P., Latimer, Kenneth S., et al.

Source: Journal of Wildlife Diseases, 36(2) : 378-382

Published By: Wildlife Disease Association

URL: <https://doi.org/10.7589/0090-3558-36.2.378>

BioOne Complete ([complete.BioOne.org](https://complete.bioone.org)) is a full-text database of 200 subscribed and open-access titles in the biological, ecological, and environmental sciences published by nonprofit societies, associations, museums, institutions, and presses.

Your use of this PDF, the BioOne Complete website, and all posted and associated content indicates your acceptance of BioOne's Terms of Use, available at www.bioone.org/terms-of-use.

Usage of BioOne Complete content is strictly limited to personal, educational, and non - commercial use. Commercial inquiries or rights and permissions requests should be directed to the individual publisher as copyright holder.

BioOne sees sustainable scholarly publishing as an inherently collaborative enterprise connecting authors, nonprofit publishers, academic institutions, research libraries, and research funders in the common goal of maximizing access to critical research.

Proliferative Pododermatitis Associated with Virus-like Particles in a Northern Gannet

Pierre-Yves Daoust,^{1,3} Dorota Wadowska,¹ Frederick Kibenge,¹ Raymond P. Campagnoli,² Kenneth S. Latimer,² and Branson W. Ritchie² ¹ Department of Pathology & Microbiology, Atlantic Veterinary College, University of Prince Edward Island, Charlottetown, PEI C1A 4P3, Canada; ² Emerging Disease Research Group, College of Veterinary Medicine, The University of Georgia, Athens, Georgia 30602-7390, USA; ³ Corresponding author (e-mail: daoust@upe.ca).

ABSTRACT: Small multifocal lesions of proliferative pododermatitis were observed in an emaciated adult male northern gannet (*Morus bassanus*). Ultrastructurally, these lesions were associated with numerous virus-like particles with a size and morphology suggestive of *Papovaviridae*. DNA in situ hybridization with probes for avian polyomaviral and papillomaviral nucleic acid and an immunohistochemical test for the presence of papillomaviral antigen failed to identify this virus further. To our knowledge, papovavirus-like particles have not been recognized previously in this avian species.

Key words: Case report, *Morus bassanus*, northern gannet, papovavirus, pododermatitis.

The northern gannet (*Morus bassanus*) is a piscivorous bird inhabiting the North Atlantic ocean. It is a coastal species which rarely flies over land, even during migrations, and which exploits mainly the first few meters of water for feeding by diving from an altitude of up to 30 m. The western population, which in 1984 was estimated at about 40,000 pairs, is composed of only six breeding colonies, all located on islands in Canadian waters (three in the Gulf of St. Lawrence, three along the eastern coast of the province of Newfoundland) (Nettleship and Chapdelaine, 1988). Adults are known to forage over long distances from these colonies, generally within a radius of 150 km (Moisan and Scherrer, 1973). Birds of all ages migrate to the coastal regions of North Carolina, South Carolina and Florida in October and come back on their breeding ground in April (Moisan and Scherrer, 1973). Perhaps because of its marine habitat and the relatively isolated location of its breeding colonies, little has been published about causes of morbidity and mortality in this species. In this report, we describe in one of

these birds mild lesions of proliferative pododermatitis associated with the presence of virus-like particles with a size and morphology suggestive of *Papovaviridae*.

On August 5 1997, an adult male northern gannet was found alive but very weak on the south shore of the Northumberland Strait, between Nova Scotia and Prince Edward Island, Canada (45°56'N, 63°52'W). It died shortly thereafter, and the carcass was frozen until submitted for necropsy to the Atlantic Veterinary College (University of Prince Edward Island, Charlottetown, Prince Edward Island, Canada) on August 14. Representative tissue samples were fixed in 10% neutral buffered formalin and processed routinely for light microscopic examination; 5 μ -thick sections were stained with hematoxylin and eosin (Luna, 1968). Samples of formalin-fixed lesions from the feet were postfixed in 2% glutaraldehyde followed by 1% osmium tetroxide, dehydrated in ethanol, and embedded in Epon/Araldite resin (JBS EM Services Inc., Montréal, Québec, Canada). Thin sections (75 nm) were stained with uranyl acetate (Hayat, 1989) and lead (Sato, 1968) and examined with a Hitachi H-600 electron microscope at 75 kV (Nissei Sangyo, Rexdale, Ontario, Canada). Formalin-fixed, paraffin-embedded skin samples were further examined for the presence of avian polyomaviral nucleic acid and papillomaviral nucleic acid by DNA in situ hybridization and for papillomaviral antigen by immunohistochemistry. The probes used in DNA in situ hybridization tests for detection of avian polyomaviral nucleic acid included oligonucleotides and a 1-kbp DNA probe to the VP-1 region (Garcia et al., 1994). The lat-

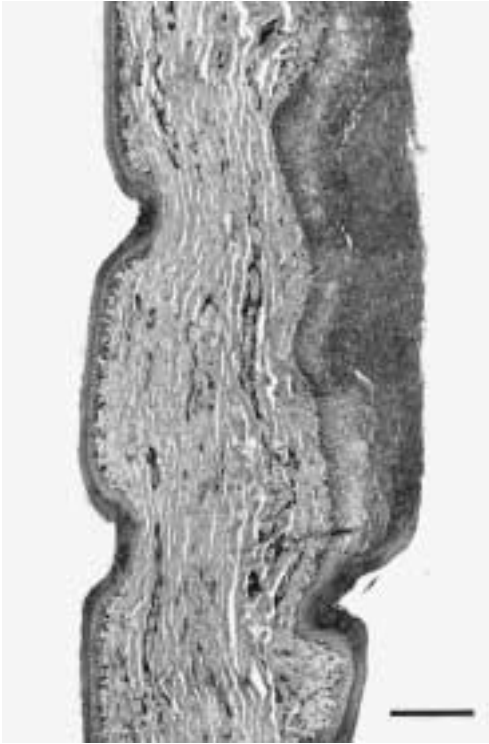


FIGURE 1. Photomicrograph of the webbed portion of a foot of a northern gannet, showing a large area of epidermal hypertrophy on the right. H&E. Bar = 0.2 mm.

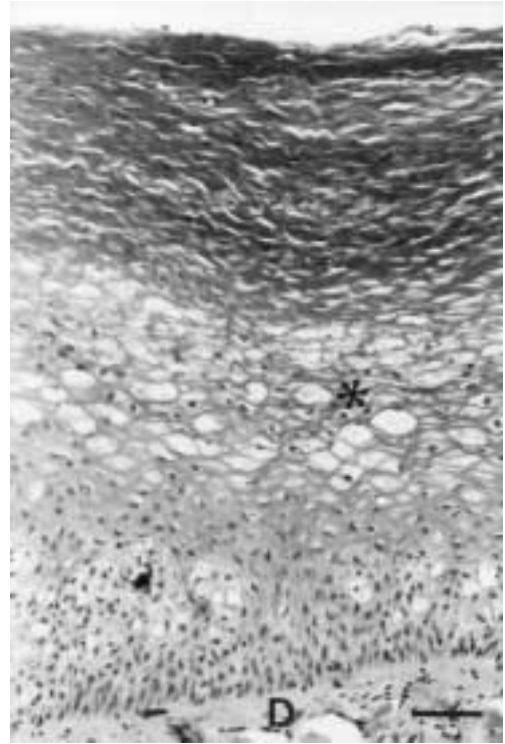


FIGURE 2. Photomicrograph of a lesion of proliferative pododermatitis in a northern gannet, showing acanthosis, hyperkeratosis, and ballooning degeneration of cells in the stratum spinosum, particularly its outer region (*). A small portion of the dermis (D) is visible. H&E. Bar = 50 μ m.

ter probe has been shown to detect nucleic acid from the avian polyomaviruses infecting various species of psittacine and passerine birds. The probe used for detection of papillomaviral nucleic acid was designed to detect African grey parrot papillomavirus and, therefore, may not react with other avian papillomaviruses (Latimer et al., 1997). For immunohistochemistry, a polyclonal antibovine papillomavirus antibody (BPV-1, Dako Corporation, Carpinteria, California, USA) was used that can detect papillomaviral antigen in several mammalian species, including cattle, dogs, and humans, (Kurman et al., 1984) but has not been shown to cross-react with avian papillomaviruses that have been tested in psittaciform birds (Campagnoli, unpubl. obs.).

The primary finding in this bird was a poor body condition characterized by de-

pletion of fat reserves, reduced body weight (1.96 kg, compared to an average of 2.93 kg in normal males; Dunning, 1993), and reduced flight muscle mass. Incidental findings included mild lesions of renal coccidiosis and a few (four to six) small raised, round or oval, white nodules, each approximately 2 mm in diameter, on the dorsal and plantar surfaces of the webbed portion of each foot. Microscopically, these nodules corresponded to areas of moderate to marked epidermal acanthosis and parakeratotic hyperkeratosis, occasionally with marked ballooning degeneration of cells in the stratum spinosum (Figs. 1, 2). Distinct inclusion bodies were not seen in the cells, and the underlying dermis showed no inflammation.

Ultrastructurally, the nucleus and cytoplasm of several epithelial cells in the out-

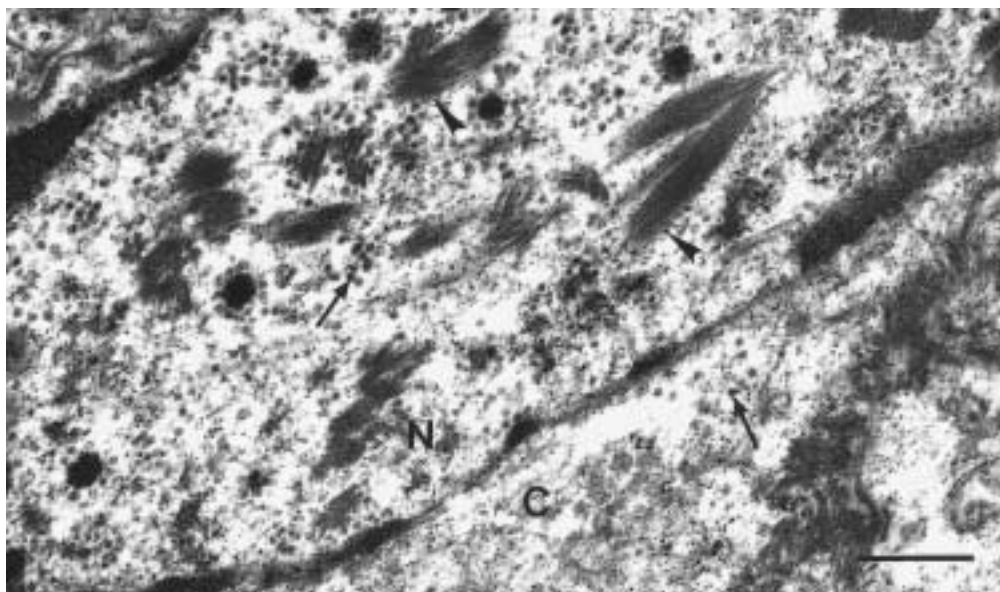


FIGURE 3. Transmission electron micrograph of a portion of a cell in the stratum spinosum from a lesion of proliferative pododermatitis in a northern gannet. Both the nucleus (N) and cytoplasm (C) contain spherical virus-like particles (arrows). The nucleus also contains several small bundles of short rod-shaped structures (arrowheads). Bar = 500 nm.

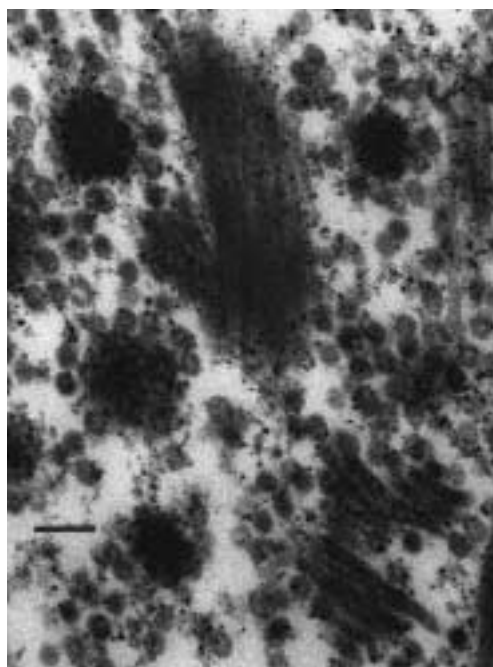


FIGURE 4. Higher magnification of a portion of the nucleus in Figure 3, showing several virus-like particles closely associated with small bundles of short rods. Bar = 100 nm.

er region of the stratum spinosum of the hyperplastic epidermis contained numerous spherical viral particles, ranging from 33 to 46 nm in diameter (based on measurement of 20 such particles in one electron micrograph) (Fig. 3). Some of the intranuclear viral particles were closely associated with small bundles of short rod-shaped structures (Figs. 3, 4). The outer diameter of these rods ranged from 33 to 39 nm (based on measurement of eight such rods with the most distinct profile); their internal structure could not be characterized because of the relatively poor state of preservation of the cells. Numerous large crystalline arrays of viral particles with icosahedral morphology ranging from 36 to 39 nm in diameter (based on measurement of 20 such particles in one electron micrograph) were in the overlying stratum corneum (Fig. 5). The results of DNA in situ hybridization for the presence of avian polyomaviral and papillomaviral nucleic acid and of immunohistochemistry for the presence of papillomaviral antigen were all negative. Foot lesions similar to

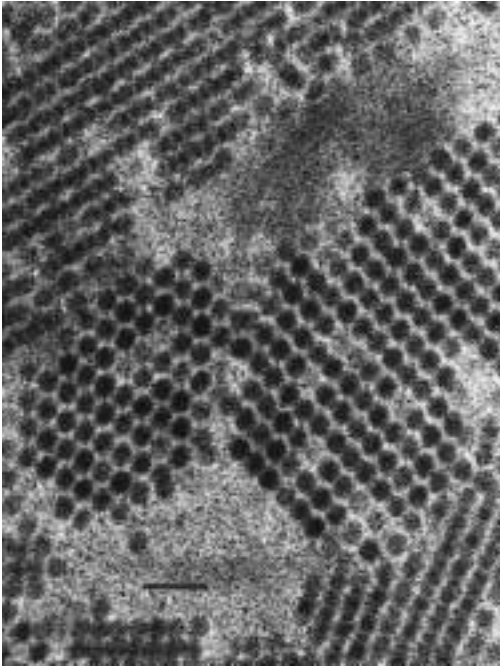


FIGURE 5. Transmission electron micrograph of a portion of the stratum corneum from a lesion of proliferative pododermatitis in a northern gannet, showing numerous nonenveloped virus-like particles arranged in crystalline arrays. The virus-like particles have an icosahedral morphology. Bar = 100 nm.

those in this bird were not seen in 84 other free-flying northern gannets examined at the Atlantic Veterinary College between 1988 and 1998.

The non-enveloped virus-like particles associated with the lesions of proliferative pododermatitis in this bird are probably members of the family Papovaviridae, based on their presence within nuclei, their size and shape, and their arrangement in crystalline arrays. Caliciviridae are nonenveloped viruses with a comparable size, but viral replication and assembly in this family take place in the cytoplasm, not the nucleus (Murphy, 1996). Hepadnaviridae have a size similar to the virus-like particles described in this northern gannet and also replicate in the nucleus, but they are enveloped viruses and members of their family have not been shown to replicate in epidermis (Murphy, 1996). The family Papovaviridae contains two subfam-

ilies: Papillomavirinae, members of which are typically 45–50 nm in diameter, and Polyomavirinae, which are 40–55 nm in diameter. Papillomaviruses are common among mammalian species but have been identified less frequently in avian species, where they have been associated with proliferative epidermal lesions on the head, legs and feet, characterized microscopically by acanthosis and hyperkeratosis (Ritchie, 1995). Avian polyomaviruses are best known as the cause of budgerigar fledgling disease, a systemic and often fatal infection of young budgerigars (*Melopsittacus undulatus*) characterized microscopically by multifocal cellular hydropic degeneration and necrosis in the epidermis (including developing feather follicles) and internal organs, often with large intranuclear basophilic or amphophilic viral inclusion bodies (Bernier et al., 1981). Ultrastructurally, the viral particles may be accompanied by “tubular structures” (Bernier et al., 1981) or “elongated forms” (Dykstra and Bozeman, 1982), comparable in diameter to, but much longer than, the intranuclear rods observed in this gannet. Systemic infection by avian polyomavirus has also been reported in nonbudgerigar psittacine birds and other avian families (Gerlach, 1994; Ritchie, 1995).

The specific identity of the virus-like particles associated with the cutaneous lesions in this northern gannet could not be determined. However, the proliferative nature of these lesions and the absence of internal lesions suggestive of a systemic viral infection support the involvement of a papillomavirus rather than a polyomavirus. We cannot offer a clear explanation for the smaller size of the virus-like particles in this bird as compared to the typical size of papovaviridae, although freezing and desiccation may have altered the details of these particles. Papillomaviruses tend to be highly host-specific (Ritchie, 1995), which may explain the failure of the DNA probe for parrot papillomavirus and of the polyclonal anti-bovine papillomavirus antibody used in this case to detect their

presence in the lesions. Additionally, the anti-bovine papillomavirus antibody appears to be most sensitive in detecting papillomaviruses within inclusion bodies. The virus-like particles in this northern gannet did not form discernable inclusion bodies. Papillomatous lesions in birds are usually mild, but may occasionally become clinically significant if they are secondarily infected or of sufficient size to interfere with movement, vision, or feeding (Ritchie, 1995).

The authors thank P. Novac and B. Rothfuss, for having submitted this bird.

LITERATURE CITED

- BERNIER, G., M. MORIN, AND G. MARSOLAIS. 1981. A generalized inclusion body disease in the budgerigar (*Melopsittacus undulatus*). *Avian Diseases* 25: 1083–1092.
- DUNNING, JR., J. B. (EDITOR). 1993. *Handbook of avian body masses*. CRC Press, Ann Arbor, Michigan, 371 pp.
- DYKSTRA, M. J., AND L. H. BOZEMAN. 1982. A light and electron microscopic examination of budgerigar fledgling disease virus in tissue and in cell culture. *Avian Pathology* 11: 11–28.
- GARCIA, A., K. S. LATIMER, F. D. NIAGRO, T. M. NORTON, R. P. CAMPAGNOLI, B. G. HARMON, E. W. HOWERTH, AND B. W. RITCHIE. 1994. Diagnosis of polyomavirus infection in seedcrackers (*Pyrenestes* sp.) and blue bills (*Spermophaga haematina*) using DNA in situ hybridization. *Avian Pathology* 23: 525–537.
- GERLACH, H. 1994. Viruses. In: *Avian medicine: Principles and application*, B. W. Ritchie, G. J. Harrison, and L. R. Harrison (eds.). Wingers Publishing, Inc., Lake Worth, Florida, pp. 862–948.
- HAYAT, M. A. 1989. *Principles and techniques of electron microscopy*, 3rd Edition, CRC Press, Boca Raton, Florida, pp. 305–315.
- KURMAN, R. J., A. B. JENSON, C. F. SINCLAIR, AND W. D. LANCASTER. 1984. Detection of human papillomaviruses by immunocytochemistry. In *Advances in immunohistochemistry*, R. A. DeLellis (ed.). Masson Publishing USA, Inc., New York, New York, pp. 201–221.
- LATIMER, K. S., F. D. NIAGRO, P. M. RAKICH, R. P. CAMPAGNOLI, B. W. RITCHIE, AND E. D. MCGEE. 1997. Investigation of parrot papillomavirus in cloacal and oral papillomas of psittacine birds. *Veterinary Clinical Pathology* 26: 158–163.
- LUNA, L. G. (EDITOR). 1968. *Manual of histologic staining methods of the Armed Forces Institute of Pathology*. McGraw-Hill Company, New York, New York, 258 pp.
- MOISAN, G., AND B. SCHERRER. 1973. Déplacements saisonniers des fous de Bassan de l'Île Bonaventure (Canada) (*Sula bassana*). *La Terre et la Vie* 27: 414–434.
- MURPHY, F. A. 1996. Virus taxonomy. In *Fields virology*, 3rd Edition, B. N. Fields, D. M. Knipe, P. M. Howley, R. M. Chanock, J. L. Melnick, T. P. Monath, B. Roizman, and S. E. Strauss (eds.). Lippincott-Raven Publishers, Philadelphia, Pennsylvania, pp. 15–57.
- NETTLESHIP, D. N., AND G. CHAPDELAINE. 1988. Population size and status of the northern gannet *Sula bassanus* in North America, 1984. *Journal of Field Ornithology* 59: 120–127.
- RITCHIE, B. W. 1995. *Avian viruses. Function and control*. Wingers Publishing, Inc., Lake Worth, Florida, 515 pp.
- SATO, T. 1968. A modified method for lead staining of thin sections. *Journal of Electron Microscopy* 17: 158–159.

Received for publication 17 September 1998.