



## **Muscular Sarcocystosis in Coyotes from Oklahoma**

Authors: Cummings, Connie A., Kocan, Alan A., Barker, Robert W., and Dubey, J. P.

Source: Journal of Wildlife Diseases, 36(4) : 761-763

Published By: Wildlife Disease Association

URL: <https://doi.org/10.7589/0090-3558-36.4.761>

---

BioOne Complete ([complete.BioOne.org](https://complete.BioOne.org)) is a full-text database of 200 subscribed and open-access titles in the biological, ecological, and environmental sciences published by nonprofit societies, associations, museums, institutions, and presses.

Your use of this PDF, the BioOne Complete website, and all posted and associated content indicates your acceptance of BioOne's Terms of Use, available at [www.bioone.org/terms-of-use](https://www.bioone.org/terms-of-use).

Usage of BioOne Complete content is strictly limited to personal, educational, and non - commercial use. Commercial inquiries or rights and permissions requests should be directed to the individual publisher as copyright holder.

---

BioOne sees sustainable scholarly publishing as an inherently collaborative enterprise connecting authors, nonprofit publishers, academic institutions, research libraries, and research funders in the common goal of maximizing access to critical research.

## Muscular Sarcocystosis in Coyotes from Oklahoma

Connie A. Cummings,<sup>1,5</sup> Alan A. Kocan,<sup>2</sup> Robert W. Barker,<sup>3</sup> and J. P. Dubey<sup>4</sup> <sup>1</sup> Department of Anatomy, Pathology, and Pharmacology, College of Veterinary Medicine, Oklahoma State University, Stillwater, Oklahoma 74078-2007, USA; <sup>2</sup> Department of Infectious Diseases and Physiology, College of Veterinary Medicine, Oklahoma State University, Stillwater, Oklahoma, 74078-2006, USA; <sup>3</sup> Department of Entomology and Plant Pathology, Oklahoma State University, Stillwater, Oklahoma 74078-2006, USA; <sup>4</sup> U.S. Department of Agriculture, Agricultural Research Service, Livestock and Poultry Science Institute, Parasite Biology and Epidemiology Laboratory, Beltsville, Maryland, 20705 USA; <sup>5</sup> Corresponding author (e-mail: rosscac@okstate.edu).

**ABSTRACT:** In a recent survey in Oklahoma (USA), 52 free-ranging coyotes were examined for the presence of sarcocysts. Two of these coyotes were found infected with sarcocysts in skeletal muscle. By light microscopy, the cyst wall was thin and smooth. Ultrastructurally, the cyst wall had minute villar protrusions. The sarcocysts were 14.4 to 50.4  $\mu\text{m}$  wide and 46.8 to 99  $\mu\text{m}$  long. This is the first report of *Sarcocystis* sp. sarcocysts in the skeletal muscle of coyotes.

**Key words:** Coyote, *Canis latrans*, sarcocystosis, sarcocysts, survey.

*Sarcocystis* spp. are one of the most common protozoan parasites that infect a variety of mammals throughout the world, including man. The definitive host, commonly a carnivore, becomes infected by ingesting tissue-containing sarcocysts. The intermediate host is often a herbivore or prey animal that becomes infected by ingesting sporulated oocyst or sporocysts excreted in the feces of the definitive host (Dubey et al., 1989). The formation of sarcocysts typically does not occur in the carnivore host (Anderson et al., 1992). Yet, sarcocysts have been reported frequently in dogs (*Canis familiaris*), domestic cats (*Felis catus*), and raccoons (*Procyon lotor*) (Dubey et al., 1989).

Coyotes (*Canis latrans*) are definitive hosts for *Sarcocystis cruzi*, *S. tenella*, *S. capracanis*, *S. odocoileocanis*, *S. hemionilatrantis*, and *S. alceslatrans*; however, coyotes have not been previously shown to be intermediate hosts for the genus (Dubey et al., 1989). Herein we report a *Sarcocystis* sp. in skeletal muscle of two coyotes.

Fifty-two adult coyotes from central and north central Oklahoma (35°50'N to 36°50'N, 97°00'W to 98°00'W) were examined for the presence of *Sarcocystis*

spp. The coyotes were approximately 1- to 5-yr-old with both sexes represented. Samples of biceps, triceps, axial, and temporalis muscle as well as heart, liver, kidney, spleen, lung, lymph nodes, bone, and intestine were collected from each coyote for histologic examination. The samples were fixed in neutral buffered 10% formalin, dehydrated through a serial gradient of ethanol, embedded in paraffin, then sectioned at 5  $\mu\text{m}$  and stained with hematoxylin and eosin (H&E) for examination by light microscopy. Two of the 52 coyotes were found infected with sarcocysts in skeletal muscle, but no other tissues, including the heart.

Although tissue fixation was not optimal for electron microscopy, ultrastructural observations of the sarcocysts were performed as a means of comparison and to confirm the presence of septa. Using the H&E stained tissue sections as a guide, a sample 1  $\times$  5 mm in thickness of formalin-fixed tissue from each of the two coyotes, was taken from the cut edge of each positive muscle specimen, diced into 1 mm cubes then directly postfixed in 1% osmium for one hr. Following osmium fixation, tissues were dehydrated in a serial gradient of acetone and embedded in hard polybed 812 resin. Thick sections, 1  $\mu\text{m}$ , were examined for sarcocysts. Ultrathin sections were taken from tissue harboring sarcocysts. Each ultrathin section was subsequently stained with uranyl acetate and lead citrate then examined by transmission electron microscopy (TEM). Representative specimens of *Sarcocystis* sp. were deposited in the U.S. National Parasite Collection (Beltsville, Maryland, USA; Accession number M1736-25).

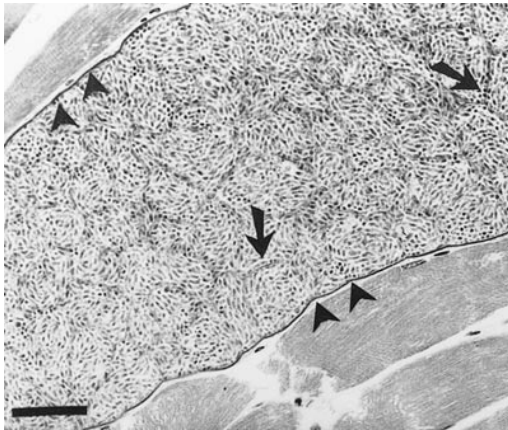


FIGURE 1. Histologic section of *Sarcocystis* sp. sarcocysts embedded in cytoplasm of striated muscle of an adult coyote. Longitudinal section. Note the thin cyst wall (arrowheads) and septa (arrows). H&E. Bar = 10  $\mu$ m.

Five different sections of skeletal muscle were examined histologically. Ten sarcocysts were found in the cytoplasm of striated muscle fibers from specimens of triceps and biceps femoris in the two infected coyotes (Fig. 1). The sarcocysts were 14.4 to 50.4  $\mu$ m thick and 46.8 to 99  $\mu$ m long (Fig. 1). By light microscopy, the sarcocyst wall was thin (<1  $\mu$ m thick) and smooth (Fig. 1). The septa were thin (<0.5  $\mu$ m thick).

Ultrastructurally, three sarcocysts were examined. The sarcocysts were divided into many compartments containing merozoites or bradyzoites (Fig. 2). Bradyzoites were about 5.0  $\mu$ m long. The primary cyst wall was 0.8 to 1  $\mu$ m thick with irregular, electron dense, variably spaced, villar protrusions (Fig. 3). Underneath these protrusions was a thickened layer composed of electron dense ground substance.

The sarcocysts found in the coyotes are different from those reported from domestic dogs (*Canis familiaris*) from India and the USA in both the cyst wall and the length of the bradyzoites. Sahasrabudhe and Shah (1966) reported a sarcocyst in the esophagus of a dog from India in which the cyst wall was 1–2  $\mu$ m thick but bradyzoite size was not determined. Hill

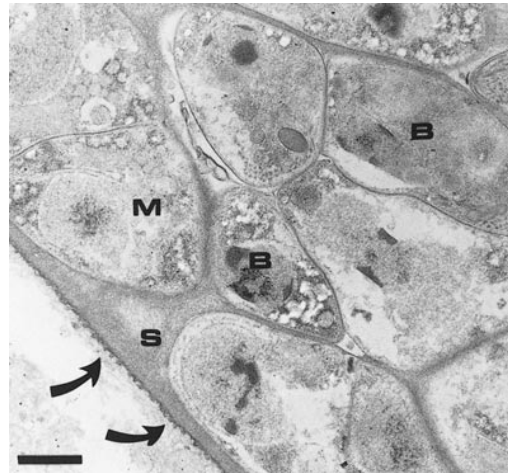


FIGURE 2. Transmission electron micrograph of *Sarcocystis* sp. from a coyote. Note thin cyst wall with villar protrusions (arrows). The cyst wall continues as septa (S) into the sarcocyst dividing groups of merozoites (M) and bradyzoites (B). Bar = 1  $\mu$ m.

et al. (1988) reported a sarcocyst in a dog from Georgia in which the cyst wall was 1.5–2.0  $\mu$ m thick and the bradyzoites were 11–12  $\mu$ m long, while Blagburn et al. (1989) reported a sarcocyst in a dog from Alabama in which the cyst wall was up to 2.3  $\mu$ m thick and the villar protrusions were up to 1.5  $\mu$ m long.

The typical life cycle of most *Sarcocystis* spp. involves a two host cycle with sexual reproduction of the parasite occurring in the enterocytes of the intestine of the definitive host and the asexual phase of the cycle occurring in striated muscle of a separate intermediate host. The morphology

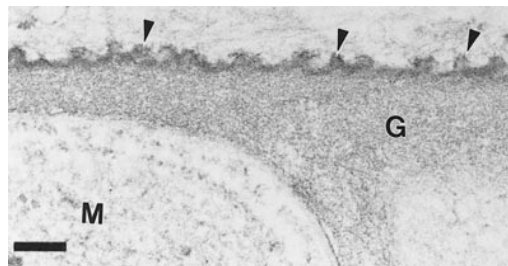


FIGURE 3. Transmission electron micrograph of *Sarcocystis* sp. from a coyote showing the sarcocyst wall with villar protrusions (arrowheads), ground substance (G), and a small portion of a developing merozoite (M). Bar = 2  $\mu$ m.

of the sarcocyst wall is one criterion that is used to distinguish *Sarcocystis* spp. (Dubey et al., 1989). Based on the criteria described by Dubey et al. (1989) the *Sarcocystis* sp. reported herein appears to be Type 1.

Presently, there are no reports of muscle sarcocyst infections in coyotes indicating that the organism reported here probably represents a new species. However, it remains to be determined if this organism represents a monoxenous species or if a separate definitive host exists for this parasite. Thus, we refrain from naming this organism until additional specimens are obtained.

This research was supported in part by Animal Health Grant no. 1433 and project 3714 of the Agricultural Experiment Station, Oklahoma State University.

#### LITERATURE CITED

- ANDERSON, A. J., E. C. GREINER, C. T. ATKINSON, AND M. E. ROELKE. 1992. Sarcocysts in the Florida bobcat (*Felis rufus floridanus*). *Journal of Wildlife Diseases* 28: 116–120.
- BLAGBURN, B. L., K. G. BRAUND, AND K. A. AMLING. 1989. Muscular *Sarcocystis* in a dog. *Proceedings of the Helminthological Society of Washington* 56: 207–210.
- DUBEY, J. P., C. A. SPER, AND R. FAYER. 1989. *Sarcocystosis of animals and man*. CRC Press, Boca Raton, Florida, 215 pp.
- HILL, J. E., W. L. CHAPMAN, AND A. K. PRESTWOOD. 1988. Intramuscular *Sarcocystis* sp. in two cats and a dog. *The Journal of Parasitology* 74: 724–727.
- SAHASRABUDHE, V. K., AND H. L. SHAH. 1966. The occurrence of *Sarcocystis* sp. in the dog. *The Journal of Protozoology* 13: 531.

*Received for publication 5 November 1999.*