

## **ELECTROCARDIOGRAM REFERENCE VALUES FOR THE BUZZARD IN SPAIN**

Authors: Espino, Luciano, Suárez, María L., López-Beceiro, Ana, and Santamarina, German

Source: Journal of Wildlife Diseases, 37(4) : 680-685

Published By: Wildlife Disease Association

URL: <https://doi.org/10.7589/0090-3558-37.4.680>

---

BioOne Complete ([complete.BioOne.org](https://complete.bioone.org)) is a full-text database of 200 subscribed and open-access titles in the biological, ecological, and environmental sciences published by nonprofit societies, associations, museums, institutions, and presses.

Your use of this PDF, the BioOne Complete website, and all posted and associated content indicates your acceptance of BioOne's Terms of Use, available at [www.bioone.org/terms-of-use](https://www.bioone.org/terms-of-use).

Usage of BioOne Complete content is strictly limited to personal, educational, and non - commercial use. Commercial inquiries or rights and permissions requests should be directed to the individual publisher as copyright holder.

---

BioOne sees sustainable scholarly publishing as an inherently collaborative enterprise connecting authors, nonprofit publishers, academic institutions, research libraries, and research funders in the common goal of maximizing access to critical research.

## ELECTROCARDIOGRAM REFERENCE VALUES FOR THE BUZZARD IN SPAIN

Luciano Espino,<sup>1,3</sup> María L. Suárez,<sup>1</sup> Ana López-Beceiro,<sup>2</sup> and German Santamarina<sup>1</sup>

<sup>1</sup> Department of Medicine, Faculty of Veterinary Medicine, University of Santiago de Compostela, Campus Universitario, 27002 Lugo, Spain

<sup>2</sup> Department of Surgery, Faculty of Veterinary Medicine, University of Santiago de Compostela, Campus Universitario, 27002 Lugo, Spain

<sup>3</sup> Corresponding author (e-mail: leschino@lugo.usc.es)

**ABSTRACT:** Electrocardiographic reference values were established on apparently healthy buzzards (*Buteo buteo*) in Lugo (Spain) from March 1997 to June 1999. All birds were anesthetized with isoflurane and placed in dorsal recumbence. The standard and augmented unipolar limb leads electrocardiograms were recorded in 65 buzzards. The wave forms were analyzed in lead II at 50 mm/sec and at 1 cm = 1 mV to determine P, PR, QRS, T and QT durations and P, QRS and T amplitudes. The polarity of each wave form was tabulated in all leads. The mean electrical axis (MEA) for the frontal plane was calculated using leads II and III. The mean heart rate was  $325.2 \pm 52.9$  beats/min. In lead II, the P wave was positive, the dominant pattern of QRS complex was QS and the T wave was always positive. The average value of the MEA was  $-99.2 \pm 7.7^\circ$ . Establishment of normal electrocardiogram (EKG) values will facilitate a better understanding of EKG changes seen in many diseases of these birds.

**Key words:** Arrhythmia, *Buteo buteo*, buzzard, cardiovascular disease, electrocardiogram, rap-tor.

### INTRODUCTION

The electrocardiogram (EKG) is defined as a graphic record of sequential, electrical depolarization-repolarization patterns of the heart. Electrocardiogram (EKG) of the bird is different from that in humans and some other mammals because the depolarization wave of the avian ventricle moves from epicardium to endocardium. Some diseases can affect the EKG trace in birds and EKG changes have been described in infectious and non-infectious diseases. In birds with *Escherichia coli* infection, Gross (1966) reported increases in the amplitude of P, R, S and T waves. Increases in duration of PR, TP and RS intervals and ventricular tachycardia were described in turkeys with influenza virus infection (Mckenzie and Will, 1972). Chickens infected with Newcastle disease virus showed ventricular arrhythmias, fusion of T and P waves and increases in the duration of the T wave (Mitchell and Bruhg, 1982). Thiamine deficiency produced sinus arrhythmias, ventricular premature contractions, and decrease of the ST segment in chickens (Sturkie, 1952a). In ducks, the electrocardiographic alterations associated

with hyperkalemia included bradycardia and tall T waves (Andersen, 1975). In recent years, electrocardiography has been used to investigate the sudden death syndrome and ascites in broilers (Odom et al., 1992; Olkowski et al., 1997). Electrocardiography may be used also to monitor heart rate and rhythm in an anesthetized patient (Degernes et al., 1988). Because the myocardium is very sensitive indicator to hypoxia, the EKG can serve as a reliable indicator of the oxygenation of the bird's myocardium.

Despite its clinical applicability, EKG has received relatively little attention from companion and wild bird practitioners. This might be due to the scarcity of electrocardiographic reference values in birds. Apparently, these values have been established only on a limited number of avian species including the chicken (Sturkie, 1949), turkey (Mckenzie et al., 1971), racing pigeon (Lumeij and Stokhof, 1985), African grey (*Psittacus erithacus*) and Amazon parrots (*Amazona spp.*) (Nap et al., 1992), and the Pekin duck (*Aix galericulata*) (Cinar et al., 1996). Only minor details about the EKG on raptors have been

published (Edjtehadi et al., 1977; Burtnick and Degernes, 1993) and these studies were done with a limited number of animals due to the difficulty in obtaining large numbers of birds. Therefore, it might be useful to establish the more detailed physiologic EKG pattern in buzzards (*Buteo buteo*) to be used in the diagnosis of cardiovascular diseases and to provide a source for later studies.

### MATERIALS AND METHODS

In this study, standard bipolar and augmented unipolar leads were recorded over a 2-yr period (March 1997 to June 1999) on 65 buzzards (*Buteo buteo*) in Lugo (Spain; 43°01'N, 7°35'W). All the birds were anesthetized due to the poor quality of EKG tracing seen when unanesthetized restraint was used. They were anesthetized with isoflurane (Isoflurane, Abbot Laboratories Ltd., Queenborough, UK) delivered by a precision vaporizer (Isotec 3, Ohmeda, BOC Health Care, UK). Anesthesia was induced by giving 5% isoflurane and 1 L/min oxygen for 1 min, then the isoflurane percentage was reduced to 2.5% for anesthetic maintenance (Casares et al., 1999).

Alligator clip electrodes were attached to the skin of each proximal cranial margin and each medial thigh region of the patient in dorsal recumbence (Fig. 1). Electrode gel was rubbed into the skin in the area where the alligator clip were attached to act as a conductive medium agent and thereby decrease the resistance of the skin. Electrocardiograms (EKGs) were recorded by a direct writing electrocardiograph (Cardiotest, EK 53, Hellige, Germany). All the EKGs were standardized at 1 cm = 1 mV with a paper speed of 50 mm/sec. Leads I, II, III, aVR, aVL and aVF were recorded. Standard EKG nomenclature was used (Tilley, 1985). Measurements were taken in lead II. The mean electrical axis (MEA) of ventricular depolarization in the frontal plane of individual birds was calculated from the vectors of ventricular depolarization in leads III and II using Bailey's system as described by Sturkie (1986). The statistical analyses were performed by using descriptive statistics with the computer program SPSS 9.0 for Windows (SPSS, Inc., Chicago, Illinois, USA).

### RESULTS

An example of the standard limb leads taken sequentially is shown in Figures 2

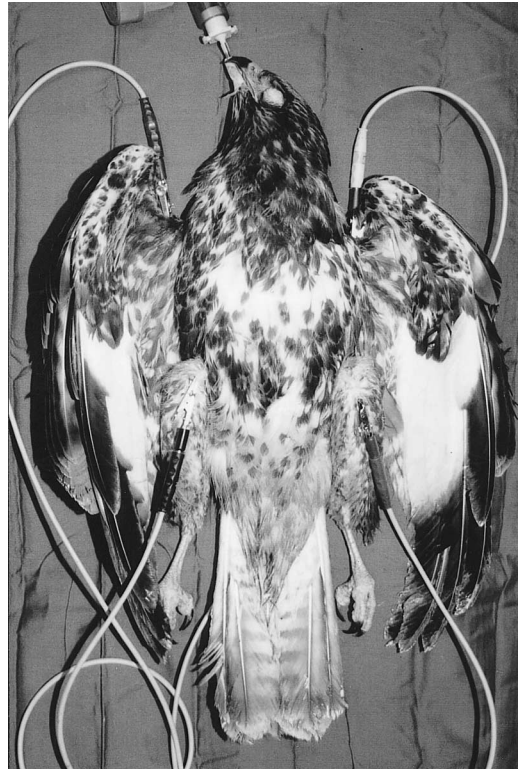


FIGURE 1. Proper placing of alligator clip electrodes in an anesthetized buzzard.

and 3. The configuration of the complexes is presented in Table 1.

The heart rate of the birds studied ranged from 200 to 440 beats/min with a mean ( $\pm$ SD) of  $325.2 \pm 52.9$  beats/min. There was a normal sinus rhythm in all the buzzards. The P wave was 48.4% positive, 51.6% negative in lead III, always negative in lead aVR and always positive in other leads. The mean duration of the P wave was  $0.025 \pm 0.01$  sec (0.02–0.04 sec), and its average amplitude was  $0.16 \pm 0.05$  mV (0.10–0.30 mV). The mean duration of the PR interval was  $0.06 \pm 0.01$  sec (0.04–0.10 sec).

In leads I, II, III and aVF, the dominant pattern of wave forms of the QRS complexes was QS whereas in leads aVR and aVF the pattern was always R. The mean duration of the QRS complex was  $0.03 \pm 0.01$  sec (0.02–0.04 sec) and its mean am-



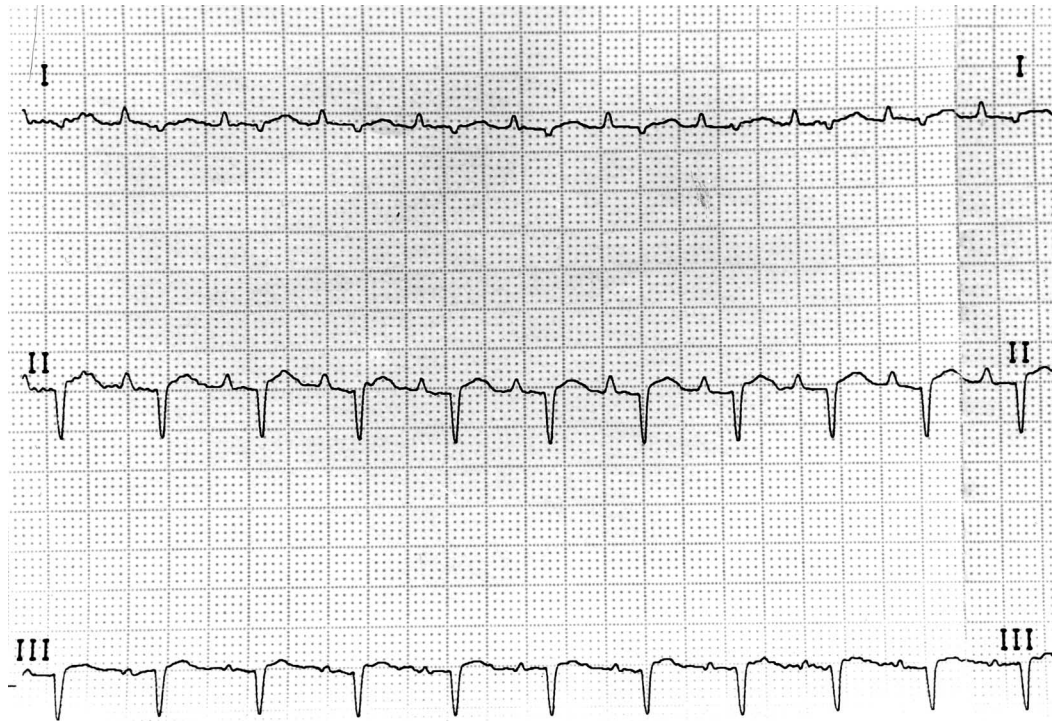


FIGURE 2. EKG from a normal anesthetized buzzard (bipolar leads).

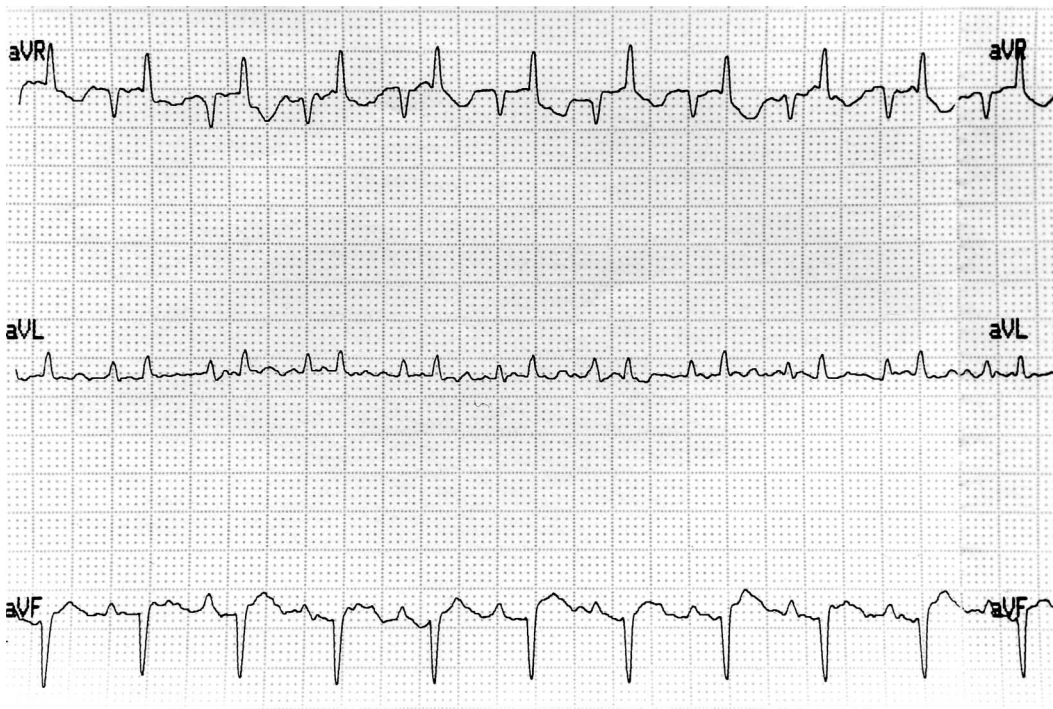


FIGURE 3. EKG from a normal anesthetized buzzard (unipolar leads).

TABLE 1. Configuration of the P wave, QRS complex and T wave in buzzards.

Leads	P wave		QRS complex			T wave	
	Positive	Negative	QS	rS	R	Positive	Negative
I	100%	0%	82.3%	17.7%	0%	100%	0%
II	100%	0%	82%	18%	0%	100%	0%
III	48.4%	51.6%	82.3%	17.7%	0%	100%	0%
aVR	0%	100%	0%	0%	100%	0%	100%
aVL	0%	100%	0%	0%	100%	0%	100%
aVF	100%	0%	80.6%	19.4%	0%	100%	0%

plitude was  $0.45 \pm 0.23$  mV (0.30–1.10 mV) in lead II.

The T wave was almost always positive in leads I, II, III and aVF and negative in leads aVR and aVL. The mean duration of the T wave was  $0.05 \pm 0.01$  sec (0.03–0.08 sec) and its mean amplitude was  $0.25 \pm 0.11$  mV (0.08–0.7 mV). The mean duration of the QT interval was  $0.1 \pm 0.01$  sec (0.08–0.13 sec).

The average value of the MEA of the heart was  $-99.2 \pm 7.7^\circ$  ( $-70.9$  to  $-111.4^\circ$ )

DISCUSSION

Recording an EKG in an awake raptor can be a problematic procedure and it may be a source of interferences. Anesthesia resolves this problem and it may alter only slightly the values of the EKG. In a comparative study between anaesthetized with isoflurane and unanesthetized Amazon and African grey parrots (Nap et al., 1992) only the median heart rate and the QT interval were significantly different.

In raptors anesthetized with isoflurane the main arrhythmias occurred during the period of induction or the period of recovery after long sessions of anesthesia (Aguilar et al., 1995). In our study all the birds had a normal sinus rhythm. An incomplete atrioventricular dissociation was described in a golden eagle (*Aquila chrysaetos*) with shotgun injuries but this arrhythmia could be due to either the anesthesia or to a trauma to the heart due to the multiple soft-tissue injuries observed in the bird (Burtnick and Degernes, 1993).

The mean heart rate that we observed was  $325.2 \pm 52.9$  beats/min. This is con-

sistent with values given by Edjtehadi et al. (1977) that described a mean heart rate of  $356 \pm 38$  beats/min in buzzards. Several pathologic conditions that may induce bradycardia include hypokalemia (Sturkie, 1952b), hyperkalemia (Andersen, 1975), thiamine deficiency (Sturkie, 1952a), and vitamin E deficiency (Sturkie, 1954). The P wave morphology was found variable in lead III (48.4% positive, 51.6% negative) which is a possible physiological variation because no patient presented any appreciable cardiac symptomatology. In a previous study on raptors, Burtnick and Degernes (1993) observed a negative P wave on lead II in one red-tailed hawk (*Buteo jamaicensis*). These authors suggested that the negative P wave was probably linked to ketamine-xylacine anesthesia. Also, they suggested that an atrial enlargement could be present or that this negative P wave was a normal variation. Moreover, Hill and Goldberg (1980) described seven different physiology morphologies in P waves in healthy domestic fowls.

The mean duration of the P wave was  $0.025 \pm 0.01$  sec which was smaller than the value described by Edjtehadi et al. (1977) at  $0.036 \pm 0.01$  sec, who had utilized only five animals in his study. An increase in duration and amplitude of the P wave is suggestive of biatrial enlargement and it is common in gallinaceous birds affected by influenza virus infection (Mitchell and Bruhg, 1982). Five patients showed overlapping of the P wave and the preceding T wave and they were excluded from our study because this PT form made ac-

curate measurements impossible (Zenoble, 1981). In a previous report fused T and P deflections were seen in 88% of the birds that developed ascites (Olkowski et al., 1997). However, the role of this PT fused pattern in the pathogenesis of ascites and sudden death syndrome warrants more detailed investigation.

The PR interval represents the period between the beginning of atrial depolarization and the beginning of ventricular depolarization. We have not observed any Ta wave in the PR segment. This Ta wave was interpreted as a sign of right atrial hypertrophy in the dog (Tilley, 1985) but in birds it should be considered normal (Lumeij and Sthokof, 1985; Boulianne et al., 1992). In agreement with McKenzie et al. (1971) and Cinar et al. (1996), we observed a negative correlation between heart rate and the PR interval. When the heart rate increased, the PR interval decreased.

The QRS complex was always negative in leads I, II, III and aVF. None of the buzzards showed an R pattern in these leads. Prominent R waves are suggestive of right ventricular hypertrophy and R1-R2-R3 pattern might be comparable to an S1-S2-S3 pattern in dogs (Czarnecki and Good, 1980). The mean values of duration (0.03 sec) and amplitude (0.45 mV) of QRS complexes were smaller than those reported previously in buzzards (Edjtchadi et al., 1977). An increased voltage in QRS complexes may be indicative of heart muscle hypertrophy. It also has been reported that the QRS complex was increased in birds that had developed ascites (Odom et al., 1992).

In African grey and parrots, the QT interval was significantly prolonged during isoflurane anesthesia (Nap et al., 1992). The QT interval's duration in our study was in agreement with the value reported previously in awake buzzards (Edjtchadi et al., 1977).

The T wave was positive in all leads except in leads aVR and aVL. The mean duration and amplitude of the T wave were

$0.05 \pm 0.01$  sec and  $0.25 \pm 0.11$  mV respectively. Elevated and peaked T waves were identified as a sign of hyperkalemia in ducks (Andersen, 1975). The same T pattern can be recorded in shocked raptors and after electrocution as a result of hyperkalemia (Blanco, 1993).

We have calculated the MEA from the vectors of ventricular depolarization in leads II and III using Bailey's hexaxial system (Sturkie, 1986). The average value of the electrical axis was  $-99.2 \pm 7.7^\circ$  ( $-70.9$  to  $-111.4^\circ$ ). Marked change to positive values ( $0$  to  $+120^\circ$ ) was described as a pathognomonic sign for dilated cardiomyopathy in parrots (Miller, 1986), chickens and turkeys (Hunsaker et al., 1971).

Most raptors require anesthesia at some point in their diagnostic workup, and the EKG can be easily incorporated at this time since the time involved is brief. Because of the potential ability to determine heart enlargement and the capacity to identify arrhythmias and conduction disturbances we highly recommend the routine use of the EKG for the detection of cardiac disease in raptors. These are the first reference values for the EKG parameters in buzzards with a respectively large number of birds. We suggest that the need for more complete cardiac workups, including the EKG in other raptors, is apparent.

#### LITERATURE CITED

- AGUILAR, R. F., V. E. SMITH, P. OGBURN, AND P. T. REDIG. 1995. Arrhythmias associated with isoflurane anesthesia in bald eagles (*Haliaeetus leucocephalus*). *Journal of Zoo and Wild Animal Medicine* 26: 508–516.
- ANDERSEN, H. T. 1975. Hyperpotassemia and electrocardiographic changes in the duck during prolonged diving. *Acta Physiologica Scandinavica* 63: 292–295.
- BLANCO, J. M. 1993. Avian electrocardiography: A contribution for the practitioner. In *Proceedings of the 1993 European Conference on Avian Medicine and Surgery*. European Committee of the Association of Avian Veterinarians, Utrecht, The Netherlands, pp. 137–154.
- BOULIANNE, M., D. B. HUNTER, R. J. JULIAN, M. R. O'GRADY, AND P. W. PHYSICK-SHEARD. 1992. Cardiac muscle mass distribution in the domestic



- turkey and relationship to electrocardiogram. *Avian Diseases* 36: 582–589.
- BURTNICK, N. L., AND L. A. DEGERNES. 1993. Electrocardiography on fifty-nine anesthetized convalescing raptors. In *Raptor Biomedicine*, P. T. Redig, J. E. Cooper, and D. B. Hunter (eds.). University of Minnesota Press, Minneapolis, Minnesota, pp. 111–121.
- CASARES, M., F. ENDERS, AND J. A. MONTOYA. 1999. Comparison of two techniques for attaching electrocardiographic electrodes to Psittacines. *Journal of Applied Animal Research* 16: 59–64.
- CINAR, A., C. BAGCI, F. BELGE, AND M. UZUN. 1996. The electrocardiogram of the Pekin duck. *Avian Diseases* 40: 919–923.
- CZARNECKI, C. M., AND A. L. GOOD. 1980. Electrocardiographic technique for identifying developing cardiomyopathies in young turkey poults. *Poultry Science* 59: 1515–1520.
- DEGERNES, L. A., T. J. KREEGER, R. MANDSAGER, AND P. T. REDIG. 1988. Ketamine-xylazine anesthesia in red-tailed hawks with antagonism by yohimbine. *Journal of Wildlife Diseases* 24: 322–326.
- EDJTEHADI, M., A. REZAKHANI, AND M. SZABUNIEWICZ. 1977. The electrocardiogram of the buzzard (*Buteo buteo*). *Zentralblatt Veterinary Medicine Association* 24: 597–600.
- GROSS, W. B. 1966. Electrocardiographic changes of *Escherichia coli* infected birds. *American Journal of Veterinary Research* 27: 1427–1436.
- HILL, J. R., AND J. M. GOLDBERG. 1980. P-wave morphology and atrial activation in the domestic fowl. *American Journal of Physiology* 239: 483–488.
- HUNSAKER, W. G., A. ROBERTSON, AND S. E. MAGWOOD. 1971. The effect of round heart disease on the electrocardiogram and heart weight of turkey poults. *Poultry Science* 20: 1712–1720.
- LUMEIJ, J. T., AND A. A. STOKHOF. 1985. Electrocardiogram of the racing pigeon (*Columbia livia domestica*). *Research in Veterinary Science* 38: 275–278.
- MCKENZIE, B. E., J. A. WILL, AND A. HARDIE. 1971. The electrocardiogram of the turkey. *Avian Diseases* 15: 737–744.
- , AND J. A. WILL. 1972. Electrocardiographic changes following influenza infection in turkeys. *Avian Diseases* 16: 308–318.
- MILLER, M. S. 1986. Electrocardiography. In *Clinical avian medicine and surgery*, G. L. Harrison, and L. R. Harrison (eds.). W. B. Saunders Co., Philadelphia, Pennsylvania, pp. 286–292.
- MITCHELL, B. W., AND M. BRUGH. 1982. Comparison of electrocardiograms of chickens infected with viscerotropic velogenic Newcastle disease virus and virulent avian influenza virus. *American Journal of Veterinary Research* 43: 2274–2278.
- NAP, A. M. P., J. T. LUMEIJ, AND A. A. STOKHOF. 1992. Electrocardiogram of the African grey (*Psittacus erithacus*) and amazon (*Amazon spp.*) parrot. *Avian Pathology* 21: 45–53.
- ODOM, T. W., L. M. ROSENBAUM, AND B. M. HARGIS. 1992. Evaluation of vectorelectrocardiographic analysis of young broiler chickens as a predictive index for susceptibility to ascites syndrome. *Avian Diseases* 36: 78–83.
- OLKOWSKI, A. A., H. L. CLASSEN, C. RIDDELL, AND C. D. BENNETT. 1997. A study of electrocardiographic patterns in a population of commercial broiler chickens. *Veterinary Research Communications* 21: 51–62.
- STURKIE, P. D. 1949. The electrocardiogram of the chicken. *American Journal of Veterinary Research* 10: 168–175.
- . 1952a. Effects of acute thiamine deficiency on the electrocardiogram of the chick. *Poultry Science* 31: 648–650.
- . 1952b. Further studies on potassium deficiency on the electrocardiogram of chickens. *Poultry Science* 33: 508–510.
- , E. P. SINGSEN, AND L. D. MATTERSON. 1954. The effects of dietary deficiencies of vitamin E and the B complex vitamins on the electrocardiogram of chickens. *American Journal of Veterinary Research* 15: 457–462.
- . 1986. Heart: Contraction, conduction, and electrocardiography. In *Avian physiology*, 4th Edition, P. D. Sturkie (ed.). Springer-Verlag, New York, New York, pp. 167–191.
- TILLEY, L. P. 1985. The approach to the electrocardiogram. In *Essentials of canine and feline electrocardiography*, 2nd Edition, P. L. Tilley (ed.). Lea and Febiger, Philadelphia, Pennsylvania, pp. 38–53.
- . 1985. Analysis of canine P-QRS-T deflections. In *Essentials of canine and feline electrocardiography*, 2nd Edition, P. L. Tilley (ed.). Lea and Febiger, Philadelphia, Pennsylvania, pp. 57–97.
- ZENOBLE, R. D. 1981. Electrocardiography in the parakeet and parrot. *Compendium on Continuing Education for Practicing Veterinarian* 3: 711–714.

Received for publication 15 July 2000.