



## **Experimental Aerosol Inoculation of *Mycobacterium bovis* in North American Opossums (*Didelphis virginiana*)**

Authors: Fitzgerald, Scott D., Zwick, Laura S., Diegel, Kelly L., Berry, Dale E., Church, Steven V., et al.

Source: Journal of Wildlife Diseases, 39(2) : 418-423

Published By: Wildlife Disease Association

URL: <https://doi.org/10.7589/0090-3558-39.2.418>

---

BioOne Complete ([complete.BioOne.org](https://complete.BioOne.org)) is a full-text database of 200 subscribed and open-access titles in the biological, ecological, and environmental sciences published by nonprofit societies, associations, museums, institutions, and presses.

Your use of this PDF, the BioOne Complete website, and all posted and associated content indicates your acceptance of BioOne's Terms of Use, available at [www.bioone.org/terms-of-use](https://www.bioone.org/terms-of-use).

Usage of BioOne Complete content is strictly limited to personal, educational, and non - commercial use. Commercial inquiries or rights and permissions requests should be directed to the individual publisher as copyright holder.

---

BioOne sees sustainable scholarly publishing as an inherently collaborative enterprise connecting authors, nonprofit publishers, academic institutions, research libraries, and research funders in the common goal of maximizing access to critical research.

## Experimental Aerosol Inoculation of *Mycobacterium bovis* in North American Opossums (*Didelphis virginiana*)

Scott D. Fitzgerald,<sup>1,5</sup> Laura S. Zwick,<sup>1</sup> Kelly L. Diegel,<sup>1</sup> Dale E. Berry,<sup>2</sup> Steven V. Church,<sup>2</sup> James G. Sikarskie,<sup>3</sup> John B. Kaneene,<sup>1,4</sup> and Willie M. Reed<sup>1</sup> <sup>1</sup>Diagnostic Center for Population and Animal Health and Department of Pathobiology and Diagnostic Investigation, College of Veterinary Medicine, Michigan State University, P.O. Box 30076, Lansing, Michigan 48909, USA; <sup>2</sup>Michigan Department of Community Health Tuberculosis Laboratory, Lansing, Michigan 48909, USA; <sup>3</sup>Department of Small Animal Clinical Sciences, College of Veterinary Medicine, Michigan State University, East Lansing, Michigan 48824, USA; <sup>4</sup>Department of Large Animal Clinical Sciences, College of Veterinary Medicine, Michigan State University, East Lansing, Michigan 48824, USA; <sup>5</sup>Corresponding author (email: fitzgerald@ahdl.msu.edu)

**ABSTRACT:** The goal of this study was to evaluate the susceptibility of North American opossums (*Didelphis virginiana*) to aerosol inoculation of *Mycobacterium bovis* at two dose levels in order to gain information on disease pathogenesis, fecal shedding of the organism, and the potential role that opossums play in the spread of this disease in nature. Six opossums received high dose ( $1 \times 10^7$  colony forming units (cfu) by aerosol inoculation, six opossums received low dose ( $1 \times 10^3$  cfu inoculation, and six opossums were sham-inoculated with sterile water and served as controls. Lungs were the most frequently infected tissues, with nine of 12 inoculated opossums positive for *M. bovis* on culture. Gross lesions consisted of multifocal pneumonia and enlarged lymph nodes. Microscopically, granulomatous pneumonia and granulomatous lymphadenitis associated with acid-fast bacilli were present in eight of 12 inoculated opossums. Fecal shedding of *M. bovis* was uncommon at both inoculation doses. While opossums were highly susceptible to aerosol inoculation of *M. bovis*, they did not become emaciated or develop widely disseminated lesions. From this study, opossums may transmit tuberculosis by aerosol infection to other opossums in close contact and serve as a source of infection to carnivores that feed upon them, however, transmission of the disease to large herbivores by fecal shedding or direct contact may be less likely.

**Key words:** Aerosol inoculation, *Didelphis virginiana*, *Mycobacterium bovis*, opossum, tuberculosis.

Endemic tuberculosis caused by *Mycobacterium bovis* involving both wildlife and domestic cattle in Michigan (USA) has been under active surveillance and study since 1994 (Schmitt et al., 1997). While white-tailed deer (*Odocoileus virginianus*) appear to be the principal wildlife host, a variety of wild carnivores and omnivores, including opossums, are naturally infected

with *M. bovis* (Bruning-Fann et al., 2001; Fitzgerald et al., 2001). Because the brushtail possum (*Trichosurus vulpecula*) has been identified as a critical wildlife reservoir of *M. bovis* in New Zealand, with the ability to transmit the disease in the advanced stages of infection to grazing cattle, additional studies in the North American opossum (*Didelphis virginiana*) were indicated (Paterson and Morris, 1995). American opossums are in the family Didelphidae, while brushtail possums are in the family Phalangeridae, making these two species distant relatives in the same order (Marsupialia) (Nowak, 1991). However, both opossums and possums share similar biologic traits including nocturnal activity and omnivorous dietary habits. Surveillance in Michigan has found naturally infected wild opossums with pulmonary lesions, and preliminary studies in our laboratory showed that opossums can be infected with *M. bovis* by oral and intramuscular inoculation (Diegel et al., 2002). This study utilized an aerosol inoculation method to more closely mimic natural droplet transmission and evaluated susceptibility to infection and fecal shedding at two different inoculation doses.

Eighteen wild-caught opossums with negative fecal cultures for *Mycobacterium* spp. were divided into three experimental groups. Six opossums were dosed with  $1 \times 10^7$  colony forming units (cfu) of *M. bovis* suspended in 2 ml of sterile water, six opossums were dosed with  $1 \times 10^3$  cfu *M. bovis*, and six were sham inoculated with 2 ml of sterile water. For inoculation,

opossums were tranquilized with intramuscular injection of 5 mg per kg tiletamine and zolazepam (Telazol®, Fort Dodge Laboratories, Fort Dodge, Iowa, USA; Stoskopf et al., 1999). Once tranquilized, opossums were placed in lateral recumbency inside a biosafety cabinet, their muzzles inserted into an anesthesia cone, and they were exposed to aerosol inoculum for 10 min (5 min lying in recumbency on each side). The inoculum was delivered through a commercial nebulizer (AeroVet® Aerosol Drug Delivery System, AeroVet Aerosol Products, Ontario, Canada), which was powered by a standard vacuum pump applying 15 pounds per square inch (PSI) room air.

Opossums were housed individually in Horsfal isolators with individual HEPA filters. Opossums were weighed at 2 wk intervals during the 90 day study. Fecal cultures for *Mycobacterium* spp. were collected on days 1, 30, and 60 post-inoculation (PI). Two opossums from each of the three experimental groups were tranquilized with Telazol®, then euthanized at days 30, 60, and 90 PI. Information recorded for each animal at necropsy included: total body weight and spleen, liver, and lung weights. All internal organs and subcutaneous lymph nodes were examined grossly during necropsy. The following tissues were collected in 10% buffered formalin for histopathologic evaluation: brain, nasal turbinate, cranial lymph nodes including tonsil, trachea, lungs, thoracic lymph nodes, heart, liver, spleen, kidney, gonad, adrenal gland, pancreas, small and large intestine, and mesenteric lymph nodes. All tissues were routinely processed, paraffin-embedded, sectioned at 3  $\mu$ m and stained by both routine hematoxylin and eosin stain, as well as by Ziehl-Neelsen acid-fast stain for microscopic evaluation. Fresh tissues were pooled for mycobacterial isolation as follows: 1) cranial lymph nodes and tonsil, 2) thoracic lymph nodes and lung, 3) liver, spleen, and kidney, and 4) intestines and mesenteric lymph nodes. Mycobacterial isolation and

identification techniques followed established protocols (Kent and Kubica, 1985; Butler et al., 1991; Reisner et al., 1994).

All opossums in the three experimental groups gained body weight over the course of the study. All animals were active and exhibited good appetite throughout the study, and no animal developed external lesions associated with tuberculosis. All opossums were negative for *Mycobacterium* spp. by fecal culture prior to inoculation. Fecal samples from all animals were culture negative at day 1 and day 30 PI; only one low dose inoculated opossum was positive for *M. bovis* by fecal culture on day 60 PI.

Typical gross lesions in inoculated opossums included multifocal granulomatous pneumonia (five of 12 inoculated opossums) and enlarged thoracic lymph nodes (seven of 12 inoculated opossums) (Fig. 1). While one animal in each of the high and low dose groups exhibited splenomegaly, and one animal in each inoculated group exhibited hepatomegaly, no statistically significant difference was found in mean spleen or liver weights between the three experimental groups. However, the mean lung weight was statistically significantly higher ( $P < 0.05$ ) in the high dose group ( $45.3 \pm 17.1$  gm) compared to both the low dose group ( $29.9 \pm 10.0$  gm) and the sham-inoculated control group ( $24.0 \pm 5.4$  gm). Statistical comparisons were made by Wilcoxon two-sample testing using SAS® software (Statistical Analysis Systems, Release 6.12, SAS Institute Inc., Cary, North Carolina, USA).

Microscopically, five of 12 inoculated opossums had granulomatous lymphadenitis with associated acid-fast bacilli; four opossums had lesions in their thoracic lymph nodes, and one opossum had a lesion in its mesenteric lymph node (Fig. 2). Eight of 12 inoculated opossums had granulomatous pneumonia associated with acid-fast bacilli typical of tuberculosis (Fig. 3); two of these animals were in the low dose group, while all six animals in the high dose group had this lesion. Granulo-



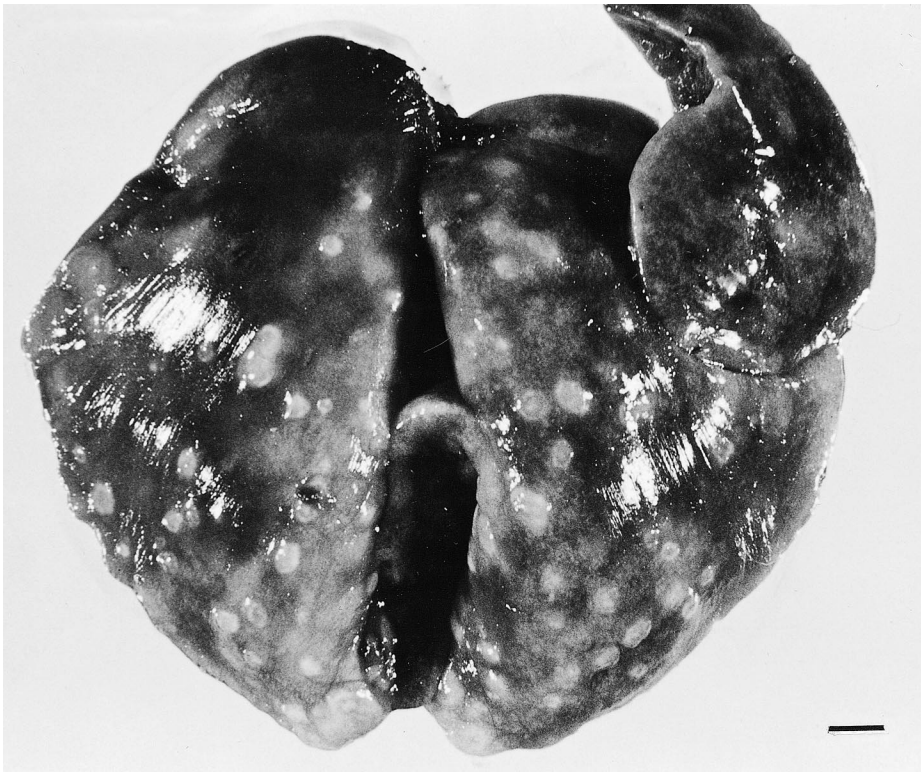

FIGURE 1. Lungs from a high dose *M. bovis* aerosol-inoculated opossum at 60 days post inoculation (PI). The lungs have dozens of scattered pale granulomas typical of pulmonary tuberculosis. Bar=1 cm.

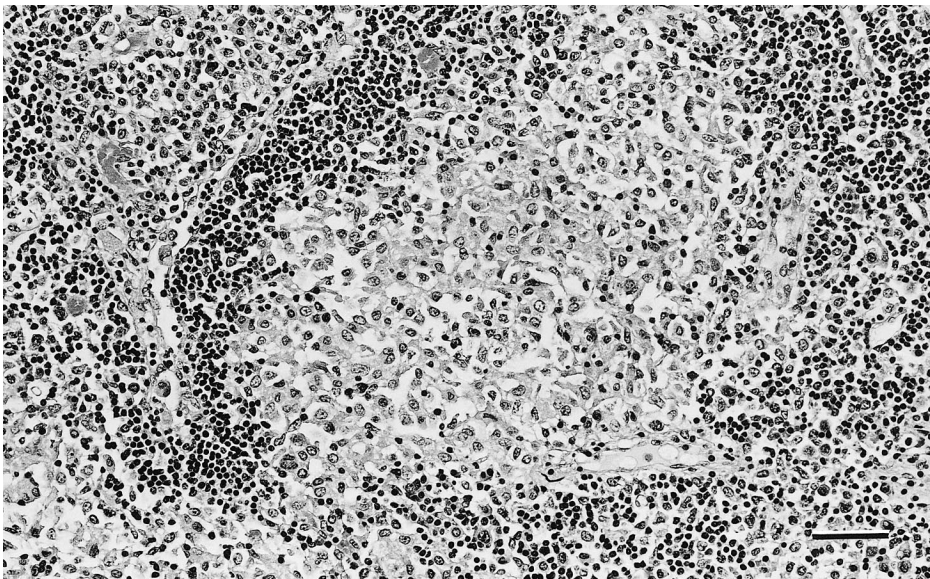


FIGURE 2. Photomicrograph of mesenteric lymph node from a high dose *M. bovis* aerosol-inoculated opossum at 30 days PI. The central portion of the lymphoid follicle has been replaced by granulomatous inflammation composed of mixed infiltrates of lymphocytes and macrophages. H&E. Bar=50  $\mu$ m.

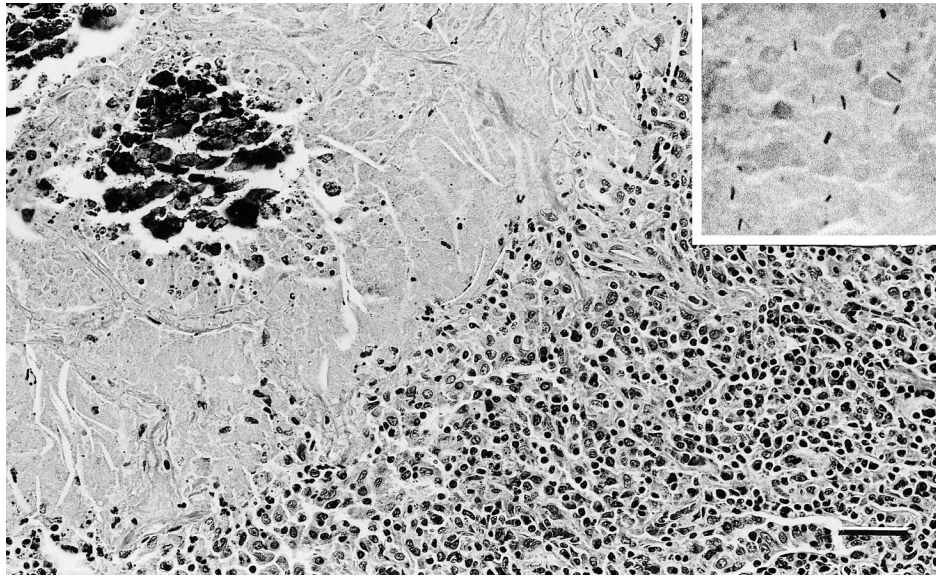


FIGURE 3. Photomicrograph of lung from a high dose *M. bovis* aerosol-inoculated opossum 90 days PI. The caseogranuloma is composed of necrotic debris that is partially mineralized, and it is surrounded by mixed infiltrates composed of lymphocytes, macrophages, and rare multi-nucleated giant cells. H&E. Bar=50  $\mu$ m. At high magnification, note moderate numbers of acid-fast bacilli within the necrotic debris. Ziehl-Neelsen acid-fast stain.

matous inflammatory infiltrates consisted of macrophages, lymphocytes, and neutrophils, with rare multi-nucleated giant cells present in some cases. Non-tuberculosis-associated lesions present in all three experimental groups included endogenous lipid pneumonia in seven opossums and disseminated besnoitiosis in eight opossums.

Thoracic tissues were the most frequently infected with *M. bovis*. Nine of 12 inoculated opossums (three of six low-dose animals, six of six high-dose animals) had *M. bovis* positive cultures from pooled samples of lung and thoracic lymph nodes; all controls had negative thoracic tissue cultures. Only two inoculated opossums had positive cranial lymph node pooled cultures, and all control opossum cranial lymph node pools were culture negative. Two inoculated opossums had positive intestinal and mesenteric lymph node pool cultures, one low dose and one high dose animal, and all control opossum intestinal pools were culture negative. Finally, only one high dose opossum had a positive ab-

dominal non-intestinal (liver, spleen, and kidney) pooled culture, while all low dose and control animals were culture negative.

The aerosol route of inoculation was highly successful in producing infected opossums, particularly in producing thoracic lesions. Furthermore, there was a noticeable dose effect, in that low dose animals had lower incidences of gross and microscopic lesions, lighter mean lung weight, and lower incidence of *M. bovis* positive cultures compared to the high dose animals. The higher mean lung weight of high dose inoculated animals was attributed to the marked granulomatous inflammatory infiltrate present in this group of animals. In spite of highly successful infection by the aerosol route, the inoculated opossums did not exhibit weight loss. Nor did the inoculated opossums exhibit clinical signs such as inappetence or depression. Finally, no mortality occurred during the 90 day course of the study. This is in marked contrast to experimental studies in brushtail possums with high-dose ( $2 \times 10^5$  cfu) inoculation



where high mortality rates occurred between 25 and 100 days PI (Jackson et al., 1995a). Even in low-dose (125 cfu) inoculation studies in brushtail possums, most animals exhibited inappetance, decreased body weight, and lethargy by 60 days PI (Buddle et al., 1994; Pfeiffer et al., 1994). Therefore, experimental aerosol inoculation of *M. bovis* in North American opossums would be a suitable model system to evaluate antibacterial agents for the treatment of tuberculosis, efficacy of tuberculosis vaccines, and more extended duration experiments to study long-term pathogenesis, organism shedding, and immunological responses.

Only one of 12 inoculated opossums was found to be shedding *M. bovis* in its feces at any PI culture period. Compared to previous experimental studies in opossums in which one of four oral-inoculated animals and three of four intramuscular-inoculated animals shed *M. bovis* in their feces, there is a strikingly lower prevalence of fecal shedding in aerosol inoculated animals (Diegel et al., 2002). It appears that aerosol infected opossums are significantly less likely to shed *M. bovis* in their feces compared to other exposure routes, or that a more advanced stage of the disease is required before fecal shedding develops. This aerosol inoculation model in opossums produced fecal culture results similar to those reported in naturally infected brushtail possums in New Zealand, where positive fecal cultures of *M. bovis* were uncommon in cross-sectional sampling of wild possums (Jackson et al., 1995a).

That aerosol inoculation tends to produce lesions most frequently in the thoracic viscera was not surprising. However, similar experimental studies using intratracheal inoculation in the brushtail possum at lower inoculation doses resulted in more widely disseminated lesions, significant losses in total body weight, and rapid deterioration of clinical signs (Buddle et al., 1994; Pfeiffer et al., 1994). One possible explanation for this disparity between study results is the fact that our aerosol

delivery system more closely resembles natural airborne infection, which allows normal host defense mechanisms, such as impaction of organisms on nasal turbinates, and clearance by the mucociliary apparatus in the airways. Many of the earlier experimental studies in brushtail possum studies utilized intratracheal inoculation which bypassed much of the natural defense mechanisms, likely resulting in a higher dose of infectious organisms in the lungs. The abdominal non-intestinal viscera pool (liver, spleen, and kidney) was harvested to evaluate hematogenous spread of *M. bovis*, because positive cultures would indicate generalized infection (Jackson et al., 1995b). In this study, only one high dose animal had evidence of generalized infection, while generalized infections involving these tissues are frequently reported in brushtail possums following either natural or experimental infection (Buddle et al., 1994; Cooke et al., 1995; Jackson et al., 1995b; Pfeiffer et al., 1994). Therefore, the North American opossum appears significantly less susceptible to *M. bovis* infection than is the brushtail possum. The North American opossum tends to primarily develop pulmonary tuberculosis, while the brushtail possum develops rapidly progressive disseminated tuberculosis.

In naturally infected brushtail possums, development of subcutaneous lymphadenitis and subsequent draining fistulous tracts results in a much greater risk for transmitting *M. bovis* to other animal species (Jackson et al., 1995a). The combination of fistulous tracts, generalized debilitation of infected possums, and the curious nature of large ruminants has been documented as a major factor in the interspecies transmission of *M. bovis* in New Zealand (Patterson and Morris, 1995). However, our study found neither debilitation, nor any gross involvement of subcutaneous lymph nodes or fistulous tracts in infected opossums. These results suggest that North American opossums are at significantly lower risk to serve as a source of

infection for cattle and cervidae than the brushtail possums.

Opossums are still relatively susceptible to *M. bovis* infection, whether they are exposed by aerosols, ingestion, or intramuscular injection. This means that if tuberculosis is introduced into these animals in the wild, active infections can develop and aerosol spread might occur to other opossums, such as from a mother to her young. Other carnivores might be infected by feeding on opossums. Our surveillance in Michigan has found several wild opossums with natural-occurring infections. Our studies to date suggest that while the North American opossum may potentially serve as a reservoir host species for *M. bovis* it does not play a major role in transmission of the organism to deer and cattle.

This study was funded in part by a grant from the United States Department of Agriculture, Animal and Plant Health Inspection Service, Veterinary Services, Tuberculosis Cooperative Agreements.

#### LITERATURE CITED

- BRUNING-FANN, C. S., S. M. SCHMITT, S. D. FITZGERALD, J. S. FIERKE, P. D. FRIEDRICH, J. B. KANEENE, K. A. CLARKE, K. L. BUTLER, J. B. PAYEUR, D. L. WHIPPLE, T. M. COOLEY, J. M. MILLER, AND D. P. MUZZO. 2001. Bovine tuberculosis in free-ranging carnivores from Michigan. *Journal of Wildlife Diseases* 37: 58–64.
- BUDDLE, B. M., F. E. ALDWELL, A. PFEFFER, AND G. W. DE LISLE. 1994. Experimental *Mycobacterium bovis* infection in the brushtail possum (*Trichosurus vulpecula*): Pathology, haematology and lymphocyte stimulation responses. *Veterinary Microbiology* 38: 241–254.
- BUTLER, W. R., K. C. JOST, JR., AND J. O. KILBURN. 1991. Identification of mycobacteria by high performance liquid chromatography. *Journal of Clinical Microbiology* 29: 2468–2472.
- COOKE, M. M., R. JACKSON, J. D. COLEMAN, AND M. R. ALLEY. 1995. Naturally occurring tuberculosis caused by *Mycobacterium bovis* in brushtail possums (*Trichosurus vulpecula*): II. Pathology. *New Zealand Veterinary Journal* 43: 315–321.
- DIEGEL, K. L., S. D. FITZGERALD, D. E. BERRY, S. V. CHURCH, W. M. REED, J. G. SIKARSKIE, AND J. B. KANEENE. 2002. Experimental inoculation of North American opossums (*Didelphis virginiana*) with *Mycobacterium bovis*. *Journal of Wildlife Diseases* 38: 275–281.
- FITZGERALD, S. D., K. L. BUTLER, L. S. ZWICK, K. R. CLARKE, S. M. SCHMITT, D. J. O'BRIEN, J. S. FIERKE, C. S. BRUNING-FANN, J. B. KANEENE, AND W. M. REED. 2001. Are we winning the fight against bovine tuberculosis in Michigan's wildlife? Proceedings of the Xth International Symposium of Veterinary Laboratory Diagnosticians, Salsomaggiore—Parma, Italy, pp. 53–54.
- JACKSON, R., M. M. COOKE, J. D. COLEMAN, R. S. MORRIS, G. W. DE LISLE, AND G. F. YATES. 1995a. Naturally occurring tuberculosis caused by *Mycobacterium bovis* in brushtail possums (*Trichosurus vulpecula*): III. Routes of infection and excretion. *New Zealand Veterinary Journal* 43: 322–327.
- , ———, ———, AND ———. 1995b. Naturally occurring tuberculosis caused by *Mycobacterium bovis* in brushtail possums (*Trichosurus vulpecula*): I. An epidemiological analysis of lesion distribution. *New Zealand Veterinary Journal* 43: 306–314.
- KENT, P. T., AND G. P. KUBICA. 1985. Public health mycobacteriology. A guide for the level III laboratory. US Department of Health and Human Services. Atlanta, Georgia.
- NOWAK, R. M. 1991. Order Marsupialia. In Walker's mammals of the world, Vol. 1, 5th Edition, R. M. Nowak (ed.). The Johns Hopkins University Press, Baltimore, Maryland, pp. 10–113.
- PATERSON, B. M., AND R. S. MORRIS. 1995. Interactions between beef cattle and simulated tuberculous possums on pasture. *New Zealand Veterinary Journal* 43: 289–293.
- PFEIFFER, A., B. M. BUDDLE, AND F. E. ALDWELL. 1994. Tuberculosis in the brushtail possum (*Trichosurus vulpecula*) after intratracheal inoculation with a low dose of *Mycobacterium bovis*. *Journal of Comparative Pathology* 111: 353–363.
- REISNER, B. S., A. M. GATSON, AND G. L. WOODS. 1994. Use of gen-probe accuprobes to identify *Mycobacterium avium* complex, *Mycobacterium tuberculosis* complex, *Mycobacterium kansasii* and *Mycobacterium gordonae* directly from Bactec TB broth cultures. *Journal of Clinical Microbiology* 32: 2995–2998.
- SCHMITT, S. M., S. D. FITZGERALD, T. M. COOLEY, C. S. BRUNING-FANN, L. SULLIVAN, D. E. BERRY, T. CARLSON, R. B. MINNIS, J. B. PAYEUR, AND J. SIKARSKIE. 1997. Bovine tuberculosis in free-ranging white-tailed deer from Michigan. *Journal of Wildlife Diseases* 33: 749–758.
- STOSKOPF, M. K., R. E. MEYER, M. JONES, AND D. O. BAUMBARGER. 1999. Field immobilization and euthanasia of American opossum. *Journal of Wildlife Diseases* 35: 145–149.

Accepted for publication 10 April 2002.