

## **Use of Immunohistochemistry to Diagnose Chytridiomycosis in Dyeing Poison Dart Frogs (*Dendrobates tinctorius*)**

Authors: Van Ells, Tracy, Stanton, James, Strieby, Ann, Daszak, Peter, Hyatt, Alex D., et al.

Source: Journal of Wildlife Diseases, 39(3) : 742-745

Published By: Wildlife Disease Association

URL: <https://doi.org/10.7589/0090-3558-39.3.742>

---

BioOne Complete ([complete.BioOne.org](https://complete.BioOne.org)) is a full-text database of 200 subscribed and open-access titles in the biological, ecological, and environmental sciences published by nonprofit societies, associations, museums, institutions, and presses.

Your use of this PDF, the BioOne Complete website, and all posted and associated content indicates your acceptance of BioOne's Terms of Use, available at [www.bioone.org/terms-of-use](https://www.bioone.org/terms-of-use).

Usage of BioOne Complete content is strictly limited to personal, educational, and non - commercial use. Commercial inquiries or rights and permissions requests should be directed to the individual publisher as copyright holder.

---

BioOne sees sustainable scholarly publishing as an inherently collaborative enterprise connecting authors, nonprofit publishers, academic institutions, research libraries, and research funders in the common goal of maximizing access to critical research.

## Use of Immunohistochemistry to Diagnose Chytridiomycosis in Dyeing Poison Dart Frogs (*Dendrobates tinctorius*)

Tracy Van Ells,<sup>1</sup> James Stanton,<sup>1</sup> Ann Strieby,<sup>1</sup> Peter Daszak,<sup>2</sup> Alex D. Hyatt,<sup>3</sup> and Corrie Brown<sup>1,4</sup>  
<sup>1</sup> Department of Veterinary Pathology, College of Veterinary Medicine, University of Georgia, Athens, Georgia 30602, USA; <sup>2</sup> Consortium for Conservation Medicine, Columbia University, Palisades, New York 10964-8000, USA; <sup>3</sup> CSIRO Livestock Ind, Australian Animal Health Laboratory, Geelong, Victoria 220, Australia; <sup>4</sup> Corresponding author (email: CorBrown@vet.uga.edu)

**ABSTRACT:** Chytridiomycosis, caused by *Batrachochytrium dendrobatidis*, is an emerging disease of both wild and captive amphibians, posing a threat to their survival in many parts of the world. As the disease can be difficult to diagnose on routine pathologic sections, the purpose of this study was to develop an additional method for visualization. To accomplish this, immunohistochemical staining was applied to histologic skin sections from four experimentally infected Dyeing poison dart frogs (*Dendrobates tinctorius*). Staining of the positive tissue sections was distinct and readily visualized, making this technique a valuable ancillary diagnostic test for this important disease.

**Key words:** *Batrachochytrium dendrobatidis*, Chytridiomycosis, *Dendrobates tinctorius*, immunohistochemistry.

In recent years amphibian populations have been declining across the globe. While no sole factor is responsible for the population declines (Halliday, 1998), scientists have recently discovered a new fungal disease, chytridiomycosis, which has been causing severe mortality rates in many anuran populations (Berger et al., 1998). The affected populations often are found in widely separated, ecologically unspoiled environments where human interference is minimal (Daszak et al., 2000). The disease was first documented in Australia and Central America in 1998 (Berger et al., 1998) and was later discovered to be present in Europe (Bosch et al., 2001) and in captive populations in the United States (Pessier et al., 1999).

The chytrid pathogen belongs to the family Chytridiomycota, whose members are non-hyphal and usually function in the environment as primary degraders, saprobes, or parasites of algae, invertebrates, or other fungi (Powell, 1993). This new fungal pathogen, *Batrachochytrium den-*

*drobatidis*, is the first chytrid shown to infect a vertebrate host (Longcore et al., 1999). The fungus infects the keratin of the stratum corneum and stratum granulosum, resulting in acanthotic hyperkeratosis (Berger et al., 1998). Although the cause of death is not known, this thickening of the skin on the feet, hind-legs, and ventral pelvic region is thought to interfere with the ability of the skin to function properly in water and gas exchange, ultimately leading to death of the host (Nichols et al., 2001).

Chytridiomycosis is usually diagnosed using hematoxylin and eosin staining of affected skin. Septate thalli or flask-shaped sporangia present in the epidermis are characteristic of the disease (Daszak et al., 1999). However, identification of these features in histologic sections can be difficult for those not familiar with the morphology of the fungus. Also, organisms can easily be missed in light infections (Fig. 1). As amphibian populations continue to decline throughout the world accurate diagnostics are needed to assess the role of chytridiomycosis in causing these declines and in determining the extent of infection in various populations. Recently, antibodies to *B. dendrobatidis* have been produced and used in an immunoperoxidase test (Berger et al., 2002). The aim of this study was to examine immunohistochemistry as a diagnostic aid for chytrid infection and to further validate this antibody using a different technique, laboratory, and host for use in studies on *B. dendrobatidis*.

Formalin-fixed paraffin-embedded tissues from a previous pathogenesis experiment were used. In that study, four Dye-

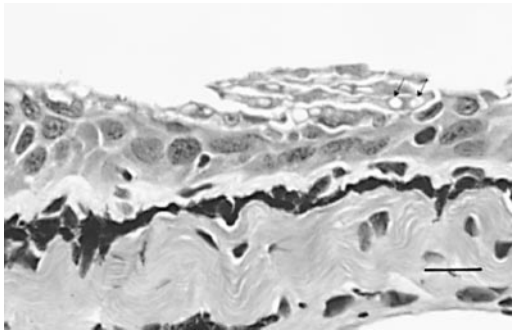


FIGURE 1. Hematoxylin and eosin staining of a light chytrid infection of *D. tinctorius* skin. Bar=100  $\mu$ m. Arrows indicate presence of chytrid thalli.

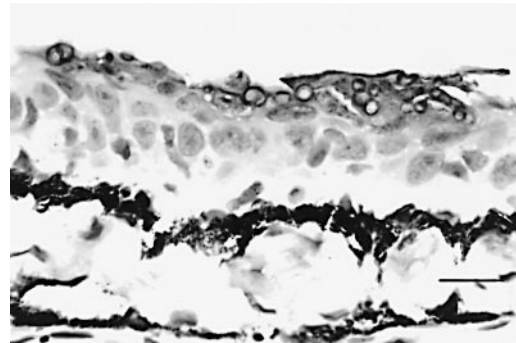


FIGURE 2. Immunohistochemical staining of a light chytrid infection of skin of *D. tinctorius*. Bar=100  $\mu$ m.

ing poison dart frogs (*Dendrobates tinctorius*) were infected with two strains of *B. dendrobatidis* between May and June 2000. For that experiment  $1\text{--}10 \times 10^6$  spores were counted on a hemacytometer and applied to the frogs topically once a day for 30 days. All animals died between 21 and 30 days post infection. Necropsies were performed within 12 hr of death. Tissue samples were fixed in 10% buffered formalin and processed routinely into paraffin within 72 hr of collection. Results and conclusions from that study will be described in greater detail in a subsequent manuscript (Peter Daszak, pers. comm.).

Paraffin blocks from that experiment were used for immunohistochemistry. Three to four  $\mu$ m sections were cut onto positively charged slides. Subsequent to deparaffinization, antigenic sites within the formalin matrix were exposed by immersion in a citrate buffer (pH 6.0) and microwaving at full strength twice for 5 min. A commercial blocking reagent (Powerblock, BioGenex, San Ramon, California, USA) was used to inhibit non-specific binding sites. Primary antibody was from a rabbit immunized with chytrid fungus (Berger et al., 2002), and was applied to sections of infected tissue from the same block at dilutions of 1:1000, 1:2500, 1:3500, and 1:10,000, overnight at 4 C or at 37 for 2 hr. A biotinylated anti-rabbit Ig antibody was used to detect the chytrid antigen-antibody complex. Avidin-biotin con-

jugated alkaline phosphatase was then applied to the tissues for 1 hr at 37 C, and the final complex was visualized with Vector Red (Vector Laboratories, Burlingame, California). Slides were then counterstained with hematoxylin and coverslipped for permanent record. Samples of mammalian tissues infected with *Aspergillus* sp., *Microsporium* sp., *Blastomyces dermatitidis*, or *Cryptococcus neoformans* and uninfected frog tissues were used as negative controls. Normal rabbit serum was applied to chytrid infected frog tissue to ensure the specificity of the primary antibody. Infected tissue samples were also stained with hematoxylin and eosin as well as with Grocott methenamine silver nitrate (GMS) stain.

A primary antibody dilution of 1:2,500 was found to maximize visibility of the fungus and minimize background staining (Figs. 2 and 3). The fungal thalli were clearly visible and appeared as sac-like bodies in the stratum corneum, corresponding to the morphology seen with the GMS fungal stain (Fig. 4). In those areas with intact colonial sporangia, individual spores stained as well. There was no staining evident in the sections stained with normal rabbit serum sample or in the sections containing *Aspergillus* sp., *B. dermatitidis*, or *C. neoformans* samples. There was some cross-reaction with arthrospores of *Microsporium* dermatophytes.

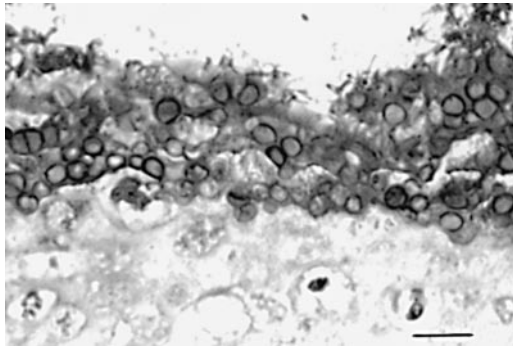


FIGURE 3. Immunohistochemical staining of digit of *D. tinctorius* showing intense chytrid infection in skin. Bar=100  $\mu$ m.

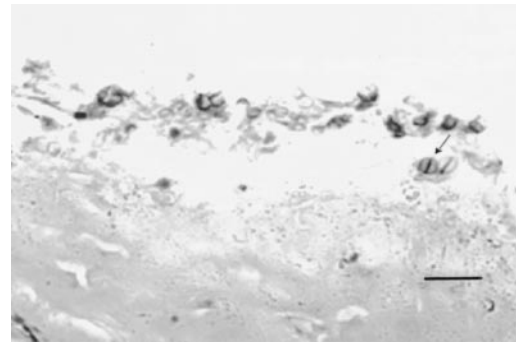


FIGURE 4. Histologic section of digit of *D. tinctorius*. Grocott methenamine silver nitrate staining highlights fungal thalli. Bar=100  $\mu$ m. Arrow indicates presence of fungus.

In summary, the distinct visualization of the *B. dendrobatidis* by this immunohistochemical technique makes this method a useful diagnostic tool for scientists to identify chytridiomycosis infections easily. One apparent cross-reaction was observed; the anti-chytrid serum was found to bind to *Microsporium* sp. fungal elements. Although both pathogens infect the keratin layer of the skin, diagnostic differentiation should not be a problem in the field as ringworm is not known to affect amphibians. Also, the morphology of the two fungi is quite different, with *microsporium* taking the form of distinct hyphal elements and round arthrospores within the keratin of hair follicles, and chytrid fungi appearing as sac-like units within the outer layers of keratin. Our results support those of Berger et al. (2002) that this antibody will be useful in diagnostic testing of chytridiomycosis over a range of test techniques, in different host species infected with different isolates of this pathogen. As chytridiomycosis continues to be found in various new locations throughout the world, this method could provide significant help for diagnosticians seeking to verify the presence of the fungus and learn more about its role in global amphibian declines.

We thank J. Longcore (Department of Biological Sciences, University of Maine), for donating the *B. dendrobatidis* spores. A portion of this research was supported by the Geraldine R. Dodge Foundation.

#### LITERATURE CITED

- BERGER, L. R., R. SPEARE, P. DASZAK, D. E. GREEN, A. A. CUNNINGHAM, C. L. GOGGIN, R. SLOCOMBE, M. A. RAGAN, A. D. HYATT, D. R. McDONALD, H. B. HINES, K. R. LIPS, G. MARANTELLI, AND H. PARKES. 1998. Chytridiomycosis causes amphibian mortality associated with population declines in the rainforests of Australia and Central America. *In* Proceedings of the National Academy of Science of the United States of America 95: 9031–9036.
- , A. D. HYATT, V. OLSEN, S. G. HENGSTBERGER, D. BOYLE, G. MARANTELLI, K. HUMPHREYS, AND J. E. LONGCORE. 2002. Production of polyclonal antibodies to *Batrachochytrium dendrobatidis* and their use in an immunoperoxidase test for chytridiomycosis in amphibians. *Diseases of Aquatic Organisms* 48: 213–220.
- BOSCH, J., I. MARTINEZ-SOLANO, AND M. GARCIA-PARIS. 2001. Evidence of a chytrid fungus infection involved in the decline of the common midwife toad (*Alytes obstetricans*) in protected areas of central Spain. *Biological Conservation* 97: 331–337.
- DASZAK, P., A. A. CUNNINGHAM, AND A. D. HYATT. 2000. Emerging infectious diseases of wildlife—threats to biodiversity and human health. *Science* 287: 443–449.
- , L. BERGER, A. A. CUNNINGHAM, A. D. HYATT, D. E. GREEN, AND R. SPEARE. 1999. Emerging infectious diseases and amphibian population declines. *Emerging Infectious Diseases* 5: 735–748.
- HALLIDAY, T. 1998. A declining amphibian conundrum. *Nature* 394: 418–419.
- LONGCORE, J. E., A. P. PESSIER, AND D. K. NICHOLS. 1999. *Batrachochytrium dendrobatidis* gen. et sp. nov., a chytrid pathogen to amphibians. *Mycologia* 91: 219–227.
- NICHOLS, D. K., E. W. LAMIRANDE, A. P. PESSIER,

- AND J. E. LONGCORE. 2001. Experimental transmission of cutaneous chytridiomycosis in dendrobatid frogs. *Journal of Wildlife Diseases* 37: 1–11.
- PESSIER, A. P., D. K. NICHOLS, J. E. LONGCORE, AND M. S. FULLER. 1999. Cutaneous chytridiomycosis in poison dart frogs (*Dendrobates* spp.) and White's tree frogs (*Litoria caerulea*). *Journal of Veterinary Diagnostic Investigation* 11: 194–199.
- POWELL, M. J. 1993. Looking at mycology with a Janus face: A glimpse at Chytridiomycetes active in the environment. *Mycologia* 85: 1–20.

*Received for publication 15 September 2002.*