

## **SYNHIMANTUS (NEMATODA) ASSOCIATED WITH GASTRIC SQUAMOUS TUMORS IN MUSKRATS \***

Authors: COSGROVE, G. E., LUSHBAUGH, W. B., HUMASON, GRETCHEN, and ANDERSON, M. G.

Source: Bulletin of the Wildlife Disease Association, 4(2) : 54-57

Published By: Wildlife Disease Association

URL: <https://doi.org/10.7589/0090-3558-4.2.54>

---

BioOne Complete ([complete.BioOne.org](https://complete.BioOne.org)) is a full-text database of 200 subscribed and open-access titles in the biological, ecological, and environmental sciences published by nonprofit societies, associations, museums, institutions, and presses.

Your use of this PDF, the BioOne Complete website, and all posted and associated content indicates your acceptance of BioOne's Terms of Use, available at [www.bioone.org/terms-of-use](https://www.bioone.org/terms-of-use).

Usage of BioOne Complete content is strictly limited to personal, educational, and non - commercial use. Commercial inquiries or rights and permissions requests should be directed to the individual publisher as copyright holder.

---

BioOne sees sustainable scholarly publishing as an inherently collaborative enterprise connecting authors, nonprofit publishers, academic institutions, research libraries, and research funders in the common goal of maximizing access to critical research.

and characterization of the causative agent.

Two mild cases of oral papillomatosis in coyotes were encountered by the field biologist in Webb County, Texas in November, 1967. These cases were not spectacular and probably would have gone undetected without the interest generated by the first case. Discussions with trappers and other biologists revealed three additional suspected cases of the disease, including one for which photographs were available for scrutiny. If spontaneous recovery occurs among coyotes and is followed by strong immunity, as in dogs, papillomatosis may not be a rare or isolated disease, but rather one that is frequently overlooked.

This case illustrates the thesis that

wildlife is susceptible to a wide variety of infectious diseases and that when these disease processes are described and looked for, they are often found. The continuous need to scrutinize wild populations for the existence of disease, and the importance of integrating disease studies with ecological research, are evident.

\*D. O. TRAINER

\*\*F. F. KNOWLTON

\*\*\*L. KARSTAD

\*Department of Veterinary Science,  
University of Madison, Wisconsin 53706

\*\*U.S. Department of Interior,  
Fish and Wildlife Service,  
P.O. Box 9037, Guilbeau Station,  
San Antonio, Texas

\*\*\*Ontario Veterinary College,  
University of Guelph,  
Guelph, Ontario

January 8, 1968

#### SYNHIMANTUS (NEMATODA) ASSOCIATED WITH GASTRIC SQUAMOUS TUMORS IN MUSKRATS\*

Nematodes of the genus *Synhimantus* have been reported in raccoons (Chandler, 1942. J. Parasitol. 28:255-268) and birds, with larval stages in fish and ostracods (Yamaguti, 1961. *Systema Helminthum*, Vol. III, *The Nematodes of Vertebrates*, Interscience). This and other genera in the spirurid family *Acuariidae* are principally parasites of birds. The first occurrence reported here in muskrats (*Ondatra zibethicus ripens*) is most unusual in view of previous extensive negative findings in surveys of parasitism in this mammal (Grundmann and Tsai, 1967. Trans. Am. Microscop. Soc. 86: 139-144) and because of the tissue reaction associated with the *Synhimantus* nematode in the muskrats' stomachs.

Two muskrats were trapped in irrigation ditches along the Rio Grande River near Las Cruces, Dona Ana County, New Mexico, in early summer of 1967. At necropsy, the limiting ridges of their forestomachs were distorted by papillary tumors which involved 5 cm. in one muskrat (Figure 1) and 2 cm. in the other. Histologically, the gastric tumors were composed of hyperplastic squamous epithelial papillomata that projected into the lumen (Figure 2). Anastomosing cords of squamous epithelium occurred in the submucosa (Figure 3). Several pathologists examined the histologic slides. Opinion was divided, but the majority felt that the tumors were benign

\*Research jointly sponsored by the Oak Ridge Associated Universities, and by the U.S. Atomic Energy Commission under contract with Union Carbide Corporation.

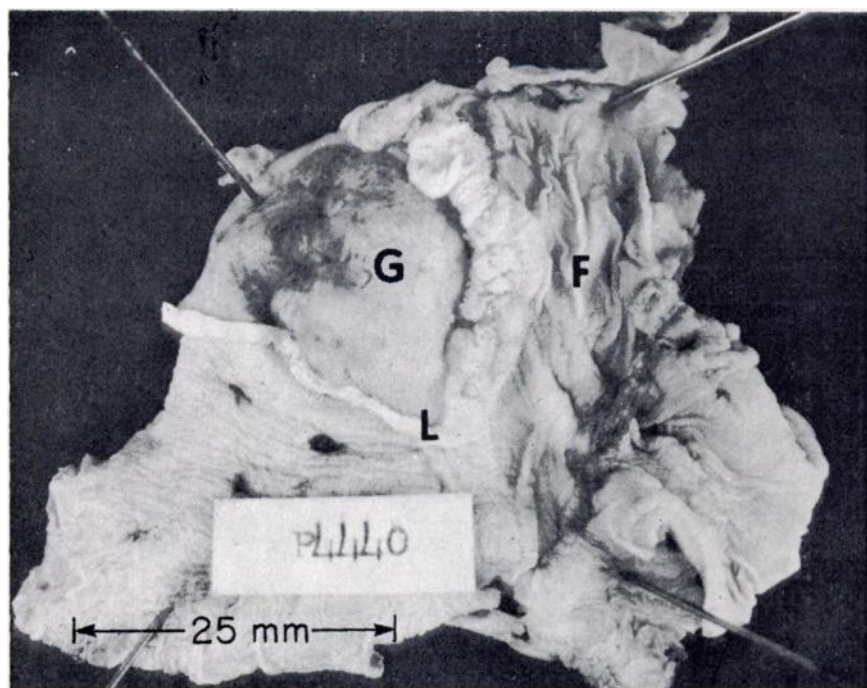


FIGURE 1. Opened stomach of a muskrat showing forestomach (F), glandular stomach (G), and limiting ridge (L). Normal limiting ridge is on the left side; the right side is neoplastic.

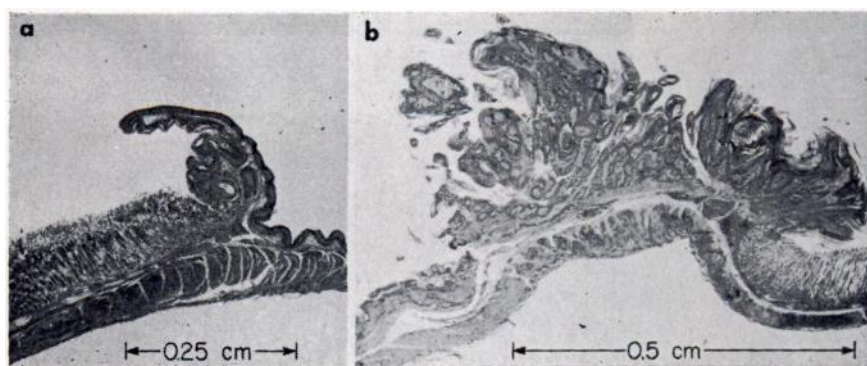


FIGURE 2. *a*—normal limiting ridge. *b*—neoplastic limiting ridge. Glandular stomach is to the right in *b* and to the left in *a*.

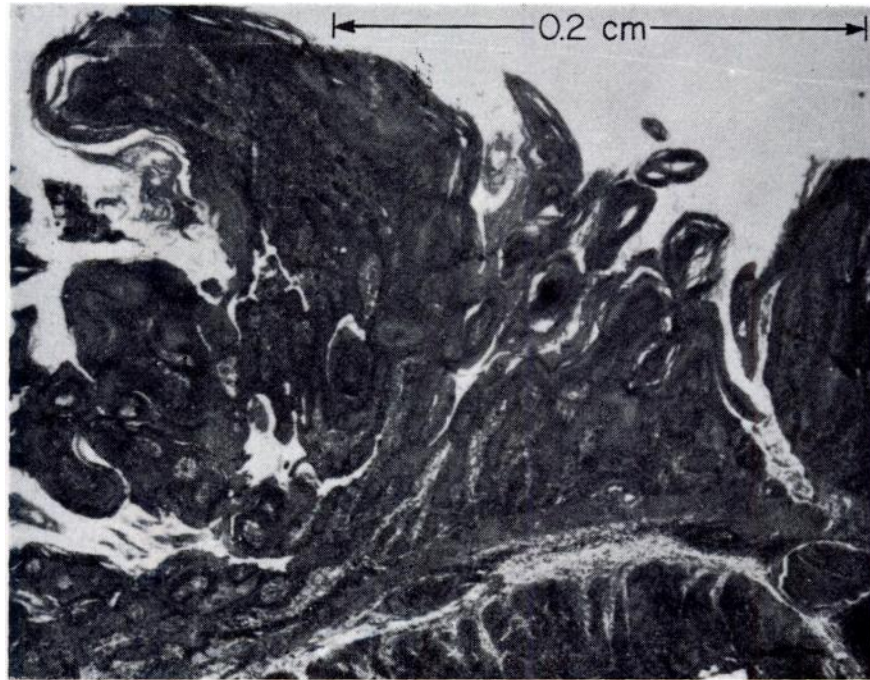


FIGURE 3. Enlargement of the papilloma of the stomach.

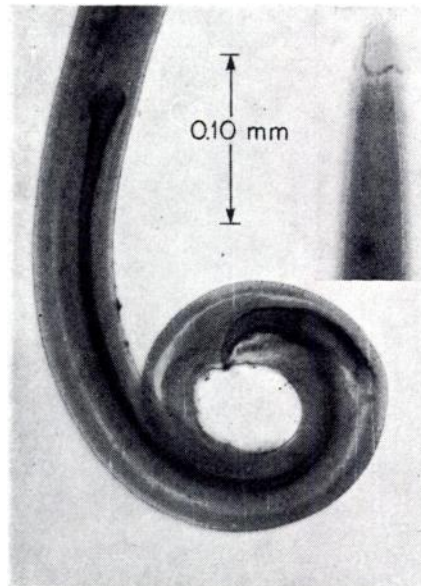


FIGURE 4. Head (insert) showing cordons, and tail showing spicules, of male *Synhimantus longigutturatus* from the muskrat.



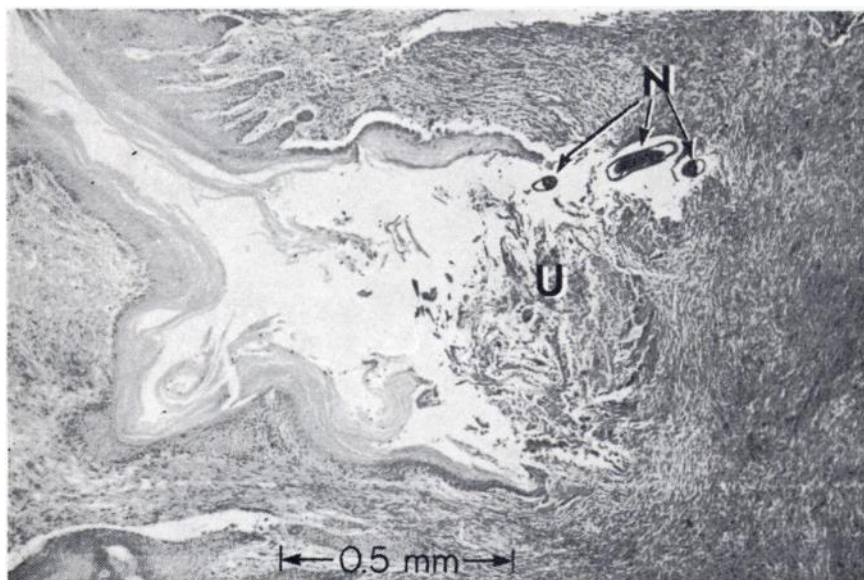


FIGURE 5. A cleft in the epithelium with an ulcerated base (U) and sections of nematode (N).

papillomas. Spirurid nematodes (*Synhimantus longigutturatus* Chandler, 1942)\* (Figure 4) were found free in stomach contents, in the gastric tumors and in submucosal and subperitoneal granulomatous abscesses. The nematodes were in clefts in the epithelium with their heads in cellular exudate in acute ulcerations (Figure 5). Although both muskrats appeared in good health when killed, each had yeast (*Monilia?*) growing in keratinized debris entrapped in the epithelial folds of the papilloma.

Although neoplasm-like epithelial responses to parasitic worms have been described previously (Willis, 1960. *Pathology of Tumours*, pp. 55-59, Butterworths),

they are sufficiently rare to warrant reporting.

#### ACKNOWLEDGEMENTS

We are indebted to Dr. C. C. Lushbaugh, Oak Ridge Associated Universities, for advice.

G. E. COSGROVE<sup>1</sup>

W. B. LUSHBAUGH<sup>2</sup>

GRETCHEN HUMASON<sup>3</sup>

M. G. ANDERSON<sup>2</sup>

<sup>1</sup> Biology Division, Oak Ridge National Laboratory, Oak Ridge, Tennessee 37830.

<sup>2</sup> Biology Department, New Mexico State University, Las Cruces, New Mexico.

<sup>3</sup> Medical Division, Oak Ridge Associated Universities, Oak Ridge, Tennessee.

\* USNM Helminthological Collection No. 70958.

December 5, 1967