

VISCERAL GOUT IN A CAPTIVE COOPER'S HAWK

Authors: WARD, F. PRESCOTT, and SLAUGHTER, LYNNARD J.

Source: Bulletin of the Wildlife Disease Association, 4(3) : 91-93

Published By: Wildlife Disease Association

URL: <https://doi.org/10.7589/0090-3558-4.3.91>

BioOne Complete (complete.BioOne.org) is a full-text database of 200 subscribed and open-access titles in the biological, ecological, and environmental sciences published by nonprofit societies, associations, museums, institutions, and presses.

Your use of this PDF, the BioOne Complete website, and all posted and associated content indicates your acceptance of BioOne's Terms of Use, available at www.bioone.org/terms-of-use.

Usage of BioOne Complete content is strictly limited to personal, educational, and non - commercial use. Commercial inquiries or rights and permissions requests should be directed to the individual publisher as copyright holder.

BioOne sees sustainable scholarly publishing as an inherently collaborative enterprise connecting authors, nonprofit publishers, academic institutions, research libraries, and research funders in the common goal of maximizing access to critical research.

The importance of this disease should be established.

Acknowledgements

We appreciate the efforts of Mr. Harry Greenwald of the U. S. Fish and Wildlife Service, and Mr. John Kruzan and Mr. Carl Helms of the New York State Conservation Department, whose sincere interest made this study possible. We are grateful to the Plum Island Animal Disease Laboratory of the

U. S. Department of Agriculture for their assistance in confirming a portion of these diagnoses.

LOUIS LEIBOVITZ

*Department of Avian Diseases
New York State Veterinary College
Cornell University
Duck Research Laboratory
Eastport, Long Island, New York 11941*

March 13, 1968

VISCERAL GOUT IN A CAPTIVE COOPER'S HAWK

A male Cooper's hawk (*Accipiter cooperii*) was taken into captivity by a falconer as a nestling (the primary feathers of the wings and tail were half grown). The bird refused food for the first 36 hours after capture but ate well thereafter. Diet during the period of captivity consisted of chicken hearts and an occasional small mammal or bird.

Approximately two weeks after capture, the bird's left leg seemed weak; the following day it refused to bear weight on the limb. A vitamin-mineral supplement* was added to the diet: 1/4 teaspoon was given daily for a week, then 1/8 teaspoon once a week for 5 weeks. The leg functioned normally a week after therapy was begun.

The hawk's adult weight was maintained at 10 ounces by controlled feeding based on daily weighing. It never progressed far enough in its training to be flown or exercised daily. Two months after capture, the hawk was accidentally exposed to a rain shower. During the next 24 hours, the bird lost approximately 1 ounce in weight, refused food, rapidly became listless, and died. Necropsy was performed within one hour after death.

When necropsied, the bird's general body condition was good and the plumage was excellent. "Hunger streaks"

or "shock marks" were seen on the mid-shafts of wing and tail feathers. These are transverse defects of the shafts and barbs of feathers, usually due to stress during feather growth; in this case they were probably due to the bird refusing food for 36 hours following capture.

The pericardium and air sacs appeared to be "dusted" with a pale yellow powder. The epicardium and myocardium were heavily mottled with small white spots. Many chalky streaks and plaques were seen beneath the fascia of the muscles on the ventral side of the neck.

Both kidneys were pale and slightly enlarged, with numerous white nodules on the external and sectioned surfaces.

Three pale yellow concretions were found in the cloaca. They were irregular in shape, 1/4 inch in diameter, and crumbled easily. Cloacal fluid was thick, chalky, and felt gritty.

We observed no other gross abnormalities.

Tissues were fixed in 10% formalin, sectioned at 6 microns, and stained with hematoxylin and eosin. Histologically, multiple small, focal lesions were observed throughout the myocardium. The lesions consisted of a central zone of radiating sheaves of eosinophilic crystal-like material (Figure 1) morphologically consistent with sodium urate crystals (Allen, *The Kidney*, Grune and Stratton, 1951). This zone was surrounded by mononuclear and multinu-

* Vitatone; Fort Dodge Laboratories, Inc., Fort Dodge, Iowa.

clear macrophages, with varying numbers of lymphocytes and heterophils on the periphery. Some necrosis was associated with these lesions.

The deposits observed in H&E-stained sections were studied using a polarizing microscope. Birefringence was not seen, an expected finding, as urate crystals are usually dissolved in sections fixed in 10% formalin (Allen, *The Kidney*, Grune and Stratton, 1951).

The kidney lesions were similar to the cardiac lesions and were randomly distributed throughout the cortex and medulla (Figure 2). Some glomeruli were necrotic and there was focal dilatation of tubules; their lumina contained amorphous eosinophilic debris. Occasional infiltrates of lymphocytes and heterophils were observed in the interstitial tissues at a distance from the granulomas.

Several focal areas of necrosis and calcification were seen in the skeletal muscle fibers of the ventral side of the neck. No microscopic lesions were observed in the skin, lungs, liver, spleen, pancreas, intestines, or central nervous system.

On the basis of the above findings, the pathologic diagnosis was visceral gout.

DISCUSSION

Birds are uricotelic, the bulk of nitrogenous waste being excreted by the kidney as uric acid. Avian gout is usually associated with hyperuricemia. Schlumberger (Lab. Invest., 8: 1304-1318, 1959) stated that factors causing hyperuricemia can be placed into two general categories:

1. impaired blood clearance of uric acid as a result of renal insufficiency (secondary hyperuricemia).
2. formation of increased amounts of uric acid (primary hyperuricemia).

Specific conditions known and suggested to cause visceral gout in birds are numerous. The renal lesions associated with a vitamin A deficiency were reported by Henk (Wiener Tierartzl.

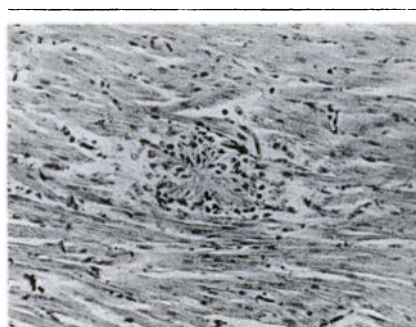


FIGURE 1. Photomicrograph of a lesion in the myocardium consisting of a central zone of eosinophilic radiating sheaves, surrounded by mono- and multinuclear macrophages. x 200

Monatsschr., 53: 161-170, 1966) and others to cause hyperuricemia and gout. Pyelonephritis (Siller, Lab. Invest., 8: 1319-1357, 1959) and renal neoplasia (Schlumberger, Lab. Invest., 8: 1304-1318, 1959) are associated with gout. Many investigators, including Bechade (Proc. 9th World Poultry Congr., Paris, I: 159-161, 1951) and Coles (J. S. Afr. Vet Med Assoc., 5: 41-48, 1934), blame excessive protein in the diet. Hartwig (Tierartzl. Rundschau., 37: 812-814, 1931) implicates the prolonged feeding of unbalanced rations, and Siller (Lab. Invest., 8: 1319-1357, 1959) suggests that a diet incorrect in amino acid balance may result in hyperuricemia. Craig

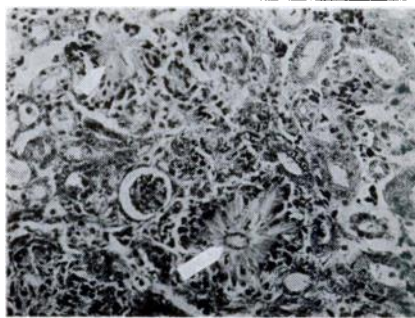


FIGURE 2. Photomicrograph of 2 kidney lesions morphologically consistent with depositions of sodium urate crystals. x 200

and Kearney (Vet Record, 11: 299-301, 1931) mention, among other factors, decreased solubility of blood urates. Nephrotoxic substances such as potassium dichromate (Ebstein, *Die Natur und Behandlung der Gicht*, Bergman, 1882) and mercuric chloride (von Kossa, Arch. Inter. Pharmacodyn., 5: 97-109, 1898-1899) are reported to result in visceral deposition of urates. The addition of small amounts of sodium bicarbonate to the diet (Witter, Poultr. Sci., 15: 256-263, 1936) and disturbances in electrolyte balances (Stonebrink, Tijdschr. Diergeneesk., 72:164-174, 1947) have also been reported to cause visceral gout. In birds and reptiles, gout has also been linked with dehydration. Most investigators, however, agree with Siller (Lab. Invest., 8: 1319-1357, 1959) that visceral gout is usually secondary to renal damage.

The only report of visceral gout in birds of prey was made by Kionka (cited by Kitt, *Textbook of Comparative General Pathology*, Keener, 1906) who reports its incidence as "quite frequent." He continues, "... the common occurrence of the disease in birds of prey kept in captivity and having insufficient exercise, favors the view that muscular activity lowers the disposition, or, in other words, uric acid is destroyed in the working muscles." Although no experimental evidence supports this postulate, accipiters are tense birds and their style of hunting is a furious, exhausting dash after their prey.

In this Cooper's hawk the main renal lesions seen microscopically were the tophaceous urate deposits. The remaining kidney tissue appeared to be functional. The concretions found in the cloaca also indicate that renal clearance of uric acid had been greater than normal for some time. Thus the general factor responsible for the disease in this bird probably was not renal insufficiency.

Pathologic evidence suggests an overproduction of uric acid, or a decrease in the solubility of normal blood levels of uric acid.

If the hawk had been overfed, one could speculate that excess protein, not utilized and converted to uric acid waste, caused a prolonged hyperuricemia. However, the bird's adult weight of 10 ounces was significantly below a 13.4 ounce mean weight of 34 wild-trapped male Cooper's hawks (Craighead and Craighead, *Hawks, Owls, and Wildlife*, Stackpole, 1956). Falconers commonly fly their birds at a weight usually 90% that of capture weight; when captured, birds are heavy or "high" and respond poorly to training unless dieted.

The most likely cause of gout in this hawk was probably the prolonged feeding of an unbalanced ration. If chicken hearts are grossly unbalanced in available essential amino acids, a large waste or unusable protein portion of the diet would be excreted as uric acid. The weakness of a leg when the bird was young, and the response of this condition to vitamin-mineral therapy support the postulate that chicken hearts alone are not an ideal diet for hawks.

A decrease in the solubility of normal blood uric acid is also a possible cause of gout in the bird. However, this is impossible to evaluate because we did not obtain blood samples. Also, no data are available on normal blood uric acid in birds of prey.

ACKNOWLEDGEMENTS

The authors acknowledge the assistance of Dr. John F. Ferrell, Dr. Gerald H. Bezahler, Mrs. Marion Royston, and Miss Carol Berg in the preparation of this manuscript.

*F. PRESCOTT WARD

**LYNNARD J. SLAUGHTER

* Medical Research Laboratory
Edgewood Arsenal, Maryland 21010

** Department of Pathology and Parasitology
Tuskegee Institute, Alabama 36088