

Occurrence of Helicobacter Infection in the Gastric Mucosa of Free-living Red Foxes (*Vulpes vulpes*)

Authors: Erginsoy, Serpil D., Sozmen, Mahmut, Ozcan, Kadir, and Tuzcu, Mehmet

Source: Journal of Wildlife Diseases, 40(3) : 548-554

Published By: Wildlife Disease Association

URL: <https://doi.org/10.7589/0090-3558-40.3.548>

BioOne Complete (complete.BioOne.org) is a full-text database of 200 subscribed and open-access titles in the biological, ecological, and environmental sciences published by nonprofit societies, associations, museums, institutions, and presses.

Your use of this PDF, the BioOne Complete website, and all posted and associated content indicates your acceptance of BioOne's Terms of Use, available at www.bioone.org/terms-of-use.

Usage of BioOne Complete content is strictly limited to personal, educational, and non - commercial use. Commercial inquiries or rights and permissions requests should be directed to the individual publisher as copyright holder.

BioOne sees sustainable scholarly publishing as an inherently collaborative enterprise connecting authors, nonprofit publishers, academic institutions, research libraries, and research funders in the common goal of maximizing access to critical research.

Occurrence of *Helicobacter* Infection in the Gastric Mucosa of Free-living Red Foxes (*Vulpes vulpes*)

Serpil D. Erginsoy,¹ Mahmut Sozmen,^{1,3} Kadir Ozcan,¹ and Mehmet Tuzcu² ¹ Department of Pathology, Faculty of Veterinary Medicine, University of Kafkas, Pasacayiri, Kars 36100, Turkey; ² Kars Vocational School, University of Kafkas, Kars 36040, Turkey; ³ Corresponding author (email: msozmen@hotmail.com)

ABSTRACT: We studied gastric *Helicobacter* spp. in five red foxes (*Vulpes vulpes*). Samples of stomach from the cardia, corpus, pyloric antrum, and duodenum were subjected to histopathologic, immunohistochemical, and transmission electron microscopy (TEM) examination for the presence of *Helicobacter* and gastritis. All foxes had gastric *Helicobacter*-like organisms (GHLOs) on examination by light microscopy and TEM. Gastric *Helicobacter*-like organisms were present in all areas of the stomachs. Chronic mild or moderate gastric inflammation was associated with infection by GHLOs in one or more regions of the stomach, but there was no correlation between inflammation and infection. It is not clear whether the organisms were causing the minimal histologic lesions observed, but the gastric mucosa of free-living foxes appears to be commonly colonized with GHLOs. The frequent colonization of free-living foxes with distinct GHLOs possibly reflects their special characteristic in feeding and/or social behavior or the potential commensal nature of the bacteria in free-ranging foxes.

Key Words: Gastritis, *Helicobacter*, immunohistochemistry, red foxes, transmission electron microscopy, *Vulpes vulpes*.

Since the identification of gastric spiral bacteria by Marshall and Warren in 1984, the genus *Helicobacter* has expanded to include more than 36 different species (Neiger, 2001); new *Helicobacter* species have been reported every year at increasing speed. Various species of *Helicobacter* have been identified in the gastric mucosa and intestines of humans and a wide range of animals, including pets and laboratory animals (Shen et al., 1997; Diker et al., 2002) and various captive and free-ranging animals (Jakob et al., 1997; Kinsel et al., 1998a; Seidel et al., 2001a, b).

Despite the frequent occurrence of gastric bacteria in captive carnivorous animals (Jakob et al., 1997; Seidel et al., 1997, 2001a, b), there have been limited studies

examining the prevalence of these bacteria in free-ranging animals (Giusti et al., 1998; Kinsel et al., 1998b). The purposes of the present study were to determine the presence, colonization sites, and morphologic types of gastric *Helicobacter*-like organisms (GHLOs) and to assess whether naturally occurring gastric bacteria were associated with gastritis in free-living foxes.

Between December 2000 and December 2002, specimens were collected from five adult free-ranging foxes (*Vulpes vulpes*; three male and two female) hunted by farmers in Turkey (40°35'N, 43°04'E). All foxes were subjected to a systematic necropsy examination; samples were collected for histopathologic and electron microscopic examinations from a range of tissues, including the cardia, corpus, and pyloric antrum of the stomach and the duodenum. Tissues were fixed in 10% neutral buffered formalin.

Fixed tissues were routinely processed and embedded in paraffin. Sections (5 µm) were stained with hematoxylin and eosin for histopathologic evaluation and with Warthin-Starry silver stain (Luna, 1968) for the identification and localization of the bacteria. Hematoxylin and eosin sections of different regions of the stomach were assessed for evidence of gastritis and degree of GHLO colonization. The classification and grading of gastritis was based on a modification of the updated Sydney system used to describe histologic lesions in humans with gastritis (Dixon et al., 1996). The overall gastritis score was determined by assessment of leukocytic infiltration, the presence of lymphoid aggregates, and the presence of gastric epithelial changes. Morphologic characteristics of the bacteria were determined by measur-

ing 50 bacteria (from 10 fields examined at $\times 1,000$ magnification). Bacterial colonization was graded as: - = absent; + = few bacteria; ++ = numerous bacteria; and +++ = numerous bacteria filling gastric glands and in mucus (Table 1).

Sections of all tissues were also processed for immunohistochemical examination by a streptavidin-biotin-peroxidase method with diaminobenzidine (Sigma, St. Louis, Missouri, USA) as the chromogen. A primary rabbit polyclonal antibody against *Helicobacter pylori* (Dako® Diagnostica GmbH, Hamburg, Germany) was used at a 1:300 dilution. Normal rabbit serum was used as a negative control.

Formalin-fixed gastric mucosa from one case were postfixed in 1% osmium tetroxide, dehydrated, infiltrated, and embedded in epoxy resin. Semithin sections cut at 1 μ m were stained with toluidine blue (containing 1% borax). Thin sections, approximately 100 nm thick, were stained with uranyl acetate and lead citrate and examined at 80 kV with a Philips 201 transmission electron microscope.

The five foxes were mature and normal in body condition (average weight 8 kg, range 7–9 kg). They were moderately infested with fleas. Their stomach contents consisted mainly of one or two semidigested mice; there were no gastric ulcerations or lesions. No macroscopic lesions were noted in any other tissues.

A single animal had no gastric inflammation. The other foxes had mild gastritis in one or all parts of the stomach; the gastritis scores within each animal were generally similar at all sites. A single fox had larger numbers of inflammatory cells in a single site (the antrum). Inflammatory cells consisted of lymphocytes and plasma cells (Table 1). In three foxes, lymphoid aggregates occurred in the lamina propria of the corpus or pyloric antrum. Gastric epithelial changes (glandular dilatation, reduction in normal undulations of the mucosal surface, and thickening of the propria mucosa) were present in one fox

TABLE 1. Semiquantitative analysis of gastric *Helicobacter* spp. colonization density, organisms detected, and gastritis score in stomachs of free-living red foxes.

Fox no.	Bacteria				Histopathology									
	Organism detected ^a				Colonization density ^b				Gastritis score ^c			Leukocytic infiltration		
					Region ^d				Region			Region		
	HFLO	HHLO	HPLO		C	Cp	A		C	Cp	A	C	Cp	A
1	-	+	+	+	+	+	+	+	+	+	+	-	-	+
2	+	-	-	-	+	+	+	+	-	-	-	-	+	-
3	+	+	-	-	+	+	+	+	+	+	+	-	-	-
4	+	+	-	-	+	+	+	+	-	-	-	-	-	-
5	-	-	+	+	-	-	+	+	+	+	+	-	-	+

^a HFLO = *Helicobacter felis*-like organism; HHLO = "*H. heilmannii*"-like organism; HPLO = *Helicobacter pylori*-like organism.

^b Colonization density: mean of three fields at $\times 400$: - = 0; + = 1–10; ++ = 11–25; +++ = >25 .

^c Gastritis score (leukocytic infiltration was scored for a mean of three fields at $\times 400$; lymphoid aggregates were scored for a mean of three fields at $\times 20$): - = leukocytes (<5); lymphoid aggregates (0); normal gastric mucosa; + = leukocytes (5–40), lymphoid aggregates (<2), normal gastric mucosa; ++ = leukocytes (40–50), lymphoid aggregates (2–5), and/or mild gastric epithelial changes; and +++ = leukocytes (>50), lymphoid aggregates (>5), and marked gastric epithelial changes.

^d C = cardia; Cp = corpus; A = pyloric antrum.

^e A short form of HHLO.

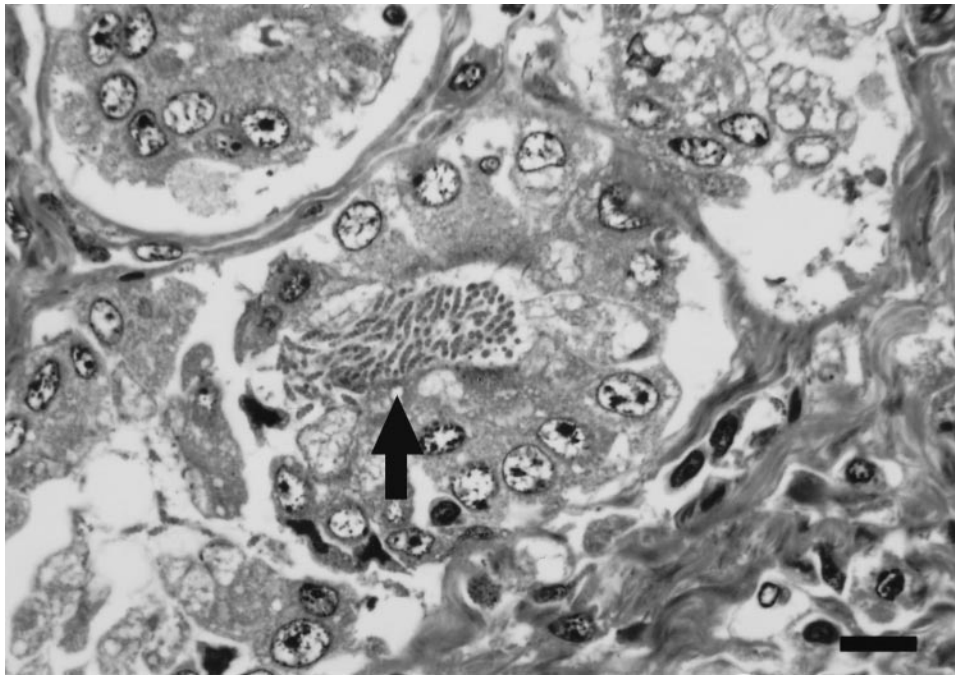


FIGURE 1. Clusters of tightly coiled cork-screw-like *Helicobacter* sp. in a gastric glandular lumen from a fox. Semi-thin section, toluidine blue. Bar = 10 μ m.

(which harbored an *H. pylori*-like organism [HPLO]).

Warthin-Starry and immunostaining revealed gastric bacteria in all foxes; no GHLOs were visualized in the duodenum. In four foxes, spiral bacteria were present at all three sites in the stomach; the intensity of colonization was slightly more in the pyloric antrum than the other two gastric regions. In a fifth fox, bacteria were confined to the antrum. In all cases, the organisms occurred as single organisms or in groups. Bacterial colonization densities ranged from mild to marked (Table 1). Immunolabeling ranged from diffuse to focal, with most samples demonstrating positive organisms in the surface mucus covering the gastric epithelium; bacteria also occurred in gastric pits and glands. There was no correlation between the presence or density of bacteria and gastric inflammation. Gastric epithelial changes were present only in the single fox harboring HPLOs.

Three morphologically different types of

bacteria were observed. In two foxes, there was combined infection by two different morphologic types of spiral organisms (Table 1). The first type, which was found in three of five foxes, consisted of loosely coiled spirals, 6–10 μ m in length; the distance between the turns was 1–1.4 μ m. These morphologic features most closely resembled *H. felis*. The second bacterial type was found in three foxes. These bacteria were long and tightly coiled (7–13 turns) organisms with an average length of 8 μ m having two to three turns at intervals of average 2 μ m and did not taper at the ends. On the basis of these morphologic characteristics they were similar to "*H. heilmannii*." In two foxes, "*H. heilmannii*"-like organisms (HHLOs) were present together with *H. felis*-like organisms. Sections from one fox had a relatively short form of spiral bacteria. They were cork-screw-like (4–6 turns) and 4–5 μ m in length (Fig. 1). On the basis of these morphologic characteristics, they most closely

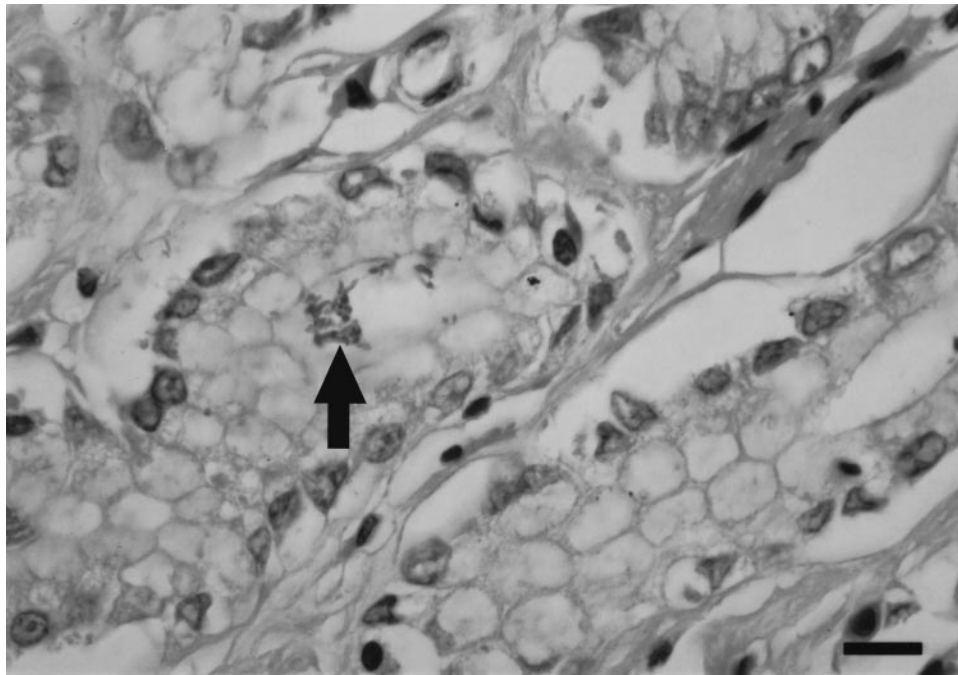


FIGURE 2. Clusters of curved or gull-winged shaped *Helicobacter* sp. in a dilated pyloric gland lumen. Immunolabeling. Bar = 10 μm .

resembled "*H. heilmannii*," with different morphology.

The third morphologically distinct microorganisms about 3–4 μm long and 0.3–0.4 μm in diameter were seen in the lumen of pyloric glands (Fig. 2). The shape ranged among rodlike, slightly curved and spiral appearances. Spiral forms usually displayed two to three loose spiral turns. The bacteria occurred singly or in groups only in the glandular lumina or on the mucosal surfaces. On the basis of these morphologic characteristics, they most closely resembled *H. pylori*.

In the semithin section of the specimen from a fox infected with *Helicobacter* that morphologically resembled *H. heilmannii*, the distribution of the bacteria and the patterns of tissue reaction were similar to those noted by light microscopy. Bacteria were on the mucosal surfaces or within the glandular lumina and were often mixed with mucus strands. They were also found intracellularly within the gastric parietal cell canaliculi. There was no evidence of

attachment to gastric epithelial cells. The organisms were a relatively short form of helical bacteria, with six to seven coils of average length of 4–5 μm (Fig. 3a) and a distance of 0.75–1 μm for every turn. They were 0.8–1 μm in diameter at the center and tapered to a diameter of 0.5–0.7 μm at the ends. The spirals were quite tight, with a pitch of 70–80° from the longitudinal axis (Fig. 3b). At least one terminal tuft of five to eight flagella was observed. Periplasmic or axial fibrils were not observed within any of the bacteria. These morphologic characteristics were consistent with the presumed resemblance to *H. heilmannii*.

Helicobacter-like bacteria commonly colonize the gastric mucosa of free-living foxes, which confirms the ubiquitous nature of this organism; it has been shown to occur in a variety of captive and free-ranging animals (Jakob et al., 1997; Giusti et al., 1998; Kinsel et al., 1998a, b; Seidel et al., 2001b). Three morphologically different kinds of spiral-shaped bacteria were

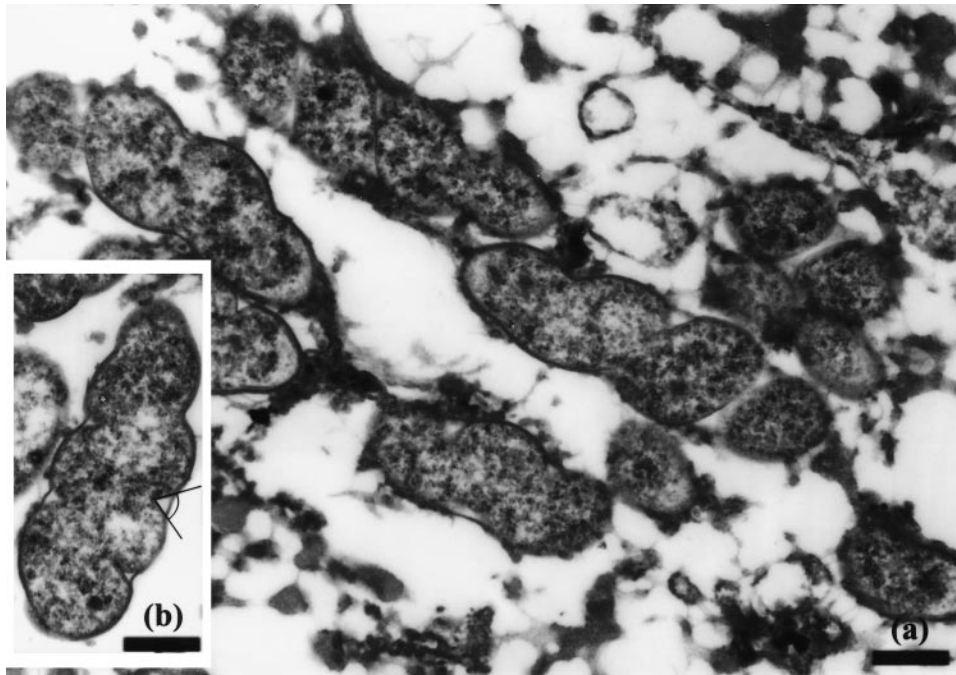


FIGURE 3. (a) Electron micrograph of a gastric cell infected with gastric *Helicobacter*-like organisms. Approximately nine tight, helix-shaped bacteria are present within the cell. Bar = 0.52 μm . (b) Transmission electron micrograph of a typical helical bacterium. The coils are quite tight with a pitch of 70° from the longitudinal axis. Bar = 0.57 μm .

found in the gastric mucosa of infected foxes. One of them had a distinctive morphology, in that it was long, loosely coiled, and similar to those bacteria most often referred to as *H. felis*; a similar bacterium was also found in the gastric mucosa of a wolf (*Canis lupus*) (Jakob et al., 1997).

The second type of spiral-shaped organism found in three foxes consisted of long and tightly coiled bacteria similar to those most often referred to as "*H. heilmannii*," which also occur in humans (Svec et al., 2000). They are well-known inhabitants of the gastric mucosa of domestic dogs (Happonen et al., 1998; Yamasaki et al., 1998) and cats (Norris et al., 1999). They also have been found in the stomach of cheetahs (*Acinonyx jubatus*) (Eaton et al., 1993a, b) and lions (*Panthera leo*) (Jakob et al., 1997), and they coexist with HPLOs. "*Helicobacter heilmannii*" may represent multiple species (Trebesius et al., 2001), and, in one fox, HHLOs with different

morphology were found. Whether these less-common morphologies represent a different form of the same species or different organisms cannot be determined from the present study, although their infrequent occurrence suggests the former.

A third organism, which was found in only one fox, was similar, if not identical, to *H. pylori*; this is the most common inhabitant of the gastric mucosa of humans, and an organism very similar to *H. pylori* has been isolated from captive cheetahs (Eaton et al., 1993a, b), lions (Jakob et al., 1997; Seidel et al., 2001b), and tigers (*Panthera tigris*) (Jakob et al., 1997) with gastritis.

The presence of *Helicobacter* spp. in fox stomachs was associated with limited tissue reactions; the lesions consisted mainly of lymphoplasmacytic and some mucosal lymphocytic aggregates. Similar mild chronic gastritis has been observed in natural or experimental *Helicobacter* infection

in dogs (Lee et al., 1992) and cats (Norris et al., 1999), and the scarcity of polymorphonuclear leucocytes is a feature of *Helicobacter* gastritis in most animal models (Diker et al., 2002), as well as in children (Camorlinga-Ponce et al., 2003). The chronic nature of the inflammation suggests that the foxes had harbored the infection for a long time. The absence of a correlation between *Helicobacter* colonization density and severity or extent of mucosal changes is similar to results of other studies (Happonen et al., 1998; Yamasaki et al., 1998).

Various hypotheses have suggested for the high prevalence of *Helicobacter* spp. in animals. Overcrowding (Dubois, 1995) and animal-to-animal contact (Hänninen et al., 1998) have been proposed as major risk factors for the transmission of gastric *Helicobacter* spp. This may explain the high incidence of *Helicobacter* infection in zoo animals, animal shelters, and research colonies, but it may be less important in free-living foxes. The demonstration of *Helicobacter* species in saliva and feces by polymerase chain reaction suggests possible oro-fecal and oro-oral transmission (Fox et al., 1995) and is consistent with increased prevalence of *H. pylori* in humans living under crowded or poor hygienic conditions (Dubois, 1995). In captive animals, intraspecies transmission of infection may also occur by vomit—the mucus may act as a vector (Axon, 1996). The infection of very young individuals is probably due to fecal-oral route (Yoshimatsu et al., 2000) or direct mouth-to-mouth transmission from the mother and among puppies (Hänninen et al., 1998). Infection from mother to cubs, by feeding of regurgitated food, is a possible route of transmission among foxes.

In conclusion, the stomach of free-living foxes is commonly colonized with *Helicobacter*-like organisms including some that resemble *H. felis*, “*H. heilmannii*” and *H. pylori*. It was not clear whether the organisms were causing minimal inflammation or whether the host is well adapted (Eaton

et al., 1993c). In such cases, the host-parasite relationship may be simply commensal or symbiotic, such as occurs when a bacterium provides a probiotic effect and contributes to competitive exclusion of more pathogenic bacteria (Dunn et al., 1997). The frequent colonization of free-living foxes with distinct GHLOs possibly reflect special characteristic in feeding and/or social behavior of wild foxes.

The authors thank A. Skuse, Comparative Pathology Laboratory, University of Bristol, Veterinary School, Langford, Bristol BS40 5DU, UK, for transmission electron microscope processing.

LITERATURE CITED

- AXON, A. T. R. 1996. The transmission of *Helicobacter pylori*: Which theory fits the facts? *European Journal of Gastroenterology and Hepatology* 8: 1–2.
- CAMORLINGA-PONCE, M., F. AVILES-JIMENEZ, L. CABRERA, R. HERNANDEZ-PANDO, O. MUNOZ, J. SOZA, AND J. TORRES. 2003. Intensity of inflammation, density of colonization and interleukin-8 response in the gastric mucosa of children infected with *Helicobacter pylori*. *Helicobacter* 8: 554–560.
- DIKER, K. S., R. HAZIROGLU, M. AKAN, S. ÇELİK, AND N. KABAKÇI. 2002. The prevalence, colonization sites and pathological effects of gastric helicobacters in dogs. *Turkish Journal of Veterinary Animal Sciences* 26: 345–351.
- DIXON, M. F., R. M. GENTA, J. H. YARDLEY, AND P. CORREA. 1996. Classification and grading of gastritis: The updated Sydney System. *International Workshop on the Histopathology of Gastritis, Houston 1994. The American Journal of Surgical Pathology* 20: 1161–1181.
- DUBOIS, A. 1995. Spiral bacteria in the human stomach: The gastric *Helicobacters*. *Emerging Infectious Diseases* 1: 79–85.
- DUNN, B. E., H. COHEN, AND M. J. BLASER. 1997. *Helicobacter pylori*. *Clinical Microbiology Reviews* 10: 720–741.
- EATON, K. A., F. E. DEWHIRST, M. J. RADIN, J. G. FOX, B. J. PASTER, S. KRAKOWKA, AND D. R. MORGAN. 1993a. *Helicobacter acinonyx* sp. nov., isolated from cheetahs with gastritis. *International Journal of Systemic Bacteriology* 43: 99–106.
- , M. J. RADIN, L. KRAMER, R. WACK, R. SHERDING, S. KRAKOWKA, J. G. FOX, AND D. R. MORGAN. 1993b. Epizootic gastritis associated with gastric spiral-shaped bacilli in cheetahs (*Acinonyx jubatus*). *Veterinary Pathology* 30: 55–63.
- , ———, AND S. KRAKOWKA. 1993c. Animal

- models of bacterial gastritis: The role of host, bacterial species and duration of infection on severity of gastritis. *Zentralbl für Bakteriologie* 280: 28–37.
- FOX, J. G., S. PERKINS, L. YAN, N. TAYLOR, L. ATTARDO, AND J. PAPPO. 1995. Public health implication of *Helicobacter pylori* in cat saliva, gastric juice and feces. *Gut* 37: 10–13.
- GIUSTI, A. M., L. CRIPPA, O. BELLINI, M. LUINI, AND E. SCANZIANI. 1998. Gastric spiral bacteria in wild rats from Italy. *Journal of Wildlife Diseases* 34: 168–172.
- HÄNNINEN, M. L., I. HAPPONEN, AND K. JALAVA. 1998. Transmission of canine gastric *Helicobacter salomonis* infection from dam to offspring and between puppies. *Veterinary Microbiology* 62: 47–58.
- HAPPONEN, I., J. LINDEN, S. SAARI, M. KARJALAINEN, M. L. HANNINEN, K. JALAVA, AND E. WESTERMARCK. 1998. Detection and effects of *Helicobacters* in healthy dogs and dogs with signs of gastritis. *Journal of American Veterinary Medical Association* 213: 1767–1774.
- JAKOB, W., M. STOLTE, A. VALENTIN, AND H. D. SCHRODER. 1997. Demonstration of *Helicobacter pylori*-like organisms in the gastric mucosa of captive exotic carnivores. *Journal of Comparative Pathology* 116: 21–33.
- KINSEL, M. J., P. KOVARIK, AND R. D. MURNANE. 1998a. Gastric spiral bacteria in small felids. *Journal of Zoo and Wildlife Medicine* 29: 214–220.
- , M. B. BRIGGS, K. VENZKE, O. FORGE, AND R. D. MURNANE. 1998b. Gastric spiral bacteria and intramuscular sarcocysts in African lions from Namibia. *Journal of Wildlife Diseases* 34: 317–324.
- LEE, A., S. KRAKOWKA, J. G. FOX, G. OTTO, K. A. EATON, AND J. C. MURPHY. 1992. Role of *Helicobacter felis* in chronic canine gastritis. *Veterinary Pathology* 29: 487–494.
- LUNA, L. G. 1968. Manual of histologic staining methods of the Armed Forces Institute of Pathology. 3rd Edition, McGraw-Hill Book Company, New York, 238 pp.
- NEIGER, R. 2001. *Helicobacter*-gastritis in cats and dogs. In *Proceedings of the 7th Federation of European Companion Animal Veterinary Associations and 47th Fachgruppe Kleintierkrankheiten der Deutschen Veterinärmedizinischen Gesellschaft congress*. 25–28 October, Berlin, Germany, pp. 89–91.
- NORRIS, C. R., S. L. MARKS, K. A. EATON, S. Z. TORABIAN, R. J. MUNN, AND J. V. SOLNICK. 1999. Healthy cats are commonly colonized with “*Helicobacter heilmannii*” that is associated with minimal gastritis. *Journal of Clinical Microbiology* 37: 189–194.
- SEIDEL, K. E., A. VALENTIN, W. JAKOB, M. STOLTE, AND J. BAUER. 1997. Histological and serological evidence of *Helicobacter* sp. in the fox. *Gut Supplement* 41: A125.
- , M. RUDOLPH, J. BAUER, A. KOLM, R. FRIES, G. DURSTEWITZ, AND W. JAKOB. 2001a. Occurrence of *Helicobacter* sp. in a wide range of captive carnivores. *International Journal of Medical Microbiology* 291 (Supplement 31): 3–4.
- , ———, ———, ———, ———, ———, AND ———. 2001b. *Helicobacter* sp. isolated from gastric mucosa of captive lions. *International Journal of Medical Microbiology* 291 (Supplement 31): 148.
- SHEN, Z., J. G. FOX, F. E. DEWHIRST, B. J. PASTER, C. J. FOLTZ, L. YAN, B. SHAMES, AND L. PERRY. 1997. *Helicobacter rodentium* sp. v., a urease-negative *Helicobacter* species isolated from laboratory mice. *International Journal of Systematic Bacteriology* 47: 627–634.
- SVEC, A., P. KORDAS, Z. PAVLIS, AND J. NOVOTNY. 2000. High prevalence of *Helicobacter heilmannii*-associated gastritis in a small, predominantly rural area: Further evidence in support of a zoonosis? *Scandinavian Journal of Gastroenterology* 35: 925–928.
- TREBESIU, K., K. ADLER, M. VIETH, M. STOLTE, AND R. HAAS. 2001. Specific detection and prevalence of *Helicobacter heilmannii*-like organisms in the human gastric mucosa by fluorescent in situ hybridization and partial 16S ribosomal DNA sequencing. *Journal of Clinical Microbiology* 39: 1510–1516.
- YAMASAKI, K., H. SUEMATSU, AND T. TAKAHASHI. 1998. Comparison of gastric lesion in dogs and cats with and without gastric spiral organisms. *Journal of American Veterinary Medical Association* 212: 529–533.
- YOSHIMATSU, T., M. SHIRAI, K. NAGATA, K. OKITA, AND T. NAKAZAWA. 2000. Transmission of *Helicobacter pylori* from challenged to nonchallenged nude mice kept in a single cage. *Digestive Diseases and Sciences* 45: 1747–1753.

Received for publication 23 April 2003.