

PATHOLOGY OF AURAL ABSCESES IN FREE-LIVING EASTERN BOX TURTLES (TERRAPENE CAROLINA CAROLINA)

Authors: Brown, Justin D., Richards, Jean M., Robertson, John, Holladay, Steven, and Sleeman, Jonathan M.

Source: Journal of Wildlife Diseases, 40(4) : 704-712

Published By: Wildlife Disease Association

URL: <https://doi.org/10.7589/0090-3558-40.4.704>

BioOne Complete (complete.BioOne.org) is a full-text database of 200 subscribed and open-access titles in the biological, ecological, and environmental sciences published by nonprofit societies, associations, museums, institutions, and presses.

Your use of this PDF, the BioOne Complete website, and all posted and associated content indicates your acceptance of BioOne's Terms of Use, available at www.bioone.org/terms-of-use.

Usage of BioOne Complete content is strictly limited to personal, educational, and non - commercial use. Commercial inquiries or rights and permissions requests should be directed to the individual publisher as copyright holder.

BioOne sees sustainable scholarly publishing as an inherently collaborative enterprise connecting authors, nonprofit publishers, academic institutions, research libraries, and research funders in the common goal of maximizing access to critical research.

PATHOLOGY OF AURAL ABSCESES IN FREE-LIVING EASTERN BOX TURTLES (*TERRAPENE CAROLINA CAROLINA*)

Justin D. Brown,¹ Jean M. Richards,¹ John Robertson,¹ Steven Holladay,¹ and Jonathan M. Sleeman^{1,2,3}

¹ Virginia-Maryland College of Veterinary Medicine, Virginia Polytechnic Institute and State University, Blacksburg, Virginia 24061–0442, USA

² Wildlife Center of Virginia, P.O. Box 1557, Waynesboro, Virginia 22980, USA

³ Corresponding author (email: jsleeman@wildlifecenter.org)

ABSTRACT: Aural abscess or abscess of the middle ear is common in free-living Eastern box turtles (*Terrapene carolina carolina*) of Virginia (USA) and elsewhere. Although its etiology remains unknown, hypovitaminosis A has been suggested on the basis of similar lesions occurring in captive chelonians fed diets that are deficient in vitamin A. This hypothesis was supported by significantly greater body burdens of organochlorine compounds (reported disruptors of vitamin A metabolism) and a nonsignificant trend toward lower serum and hepatic vitamin A levels in free-living box turtles with this lesion. The tympanic epithelium was evaluated in 27 box turtles (10 with aural abscesses and 17 without). Lesions of the tympanic epithelium of box turtles with aural abscesses included hyperplasia, squamous metaplasia, hyperemia, cellular sloughing, granulomatous inflammation, and bacterial infection. These changes were more severe in turtles with aural abscesses than in those without and were more severe in tympanic cavities that had an abscess compared to those without when the lesion was unilateral. Organs from 21 box turtles (10 with aural abscesses and 11 without) from the study population were examined for microscopic lesions, and minimal histopathologic changes were found, none of which were similar to those found in the tympanic epithelium. Histopathologic changes in box turtles with aural abscesses were consistent with a syndrome that may involve hypovitaminosis A.

Key words: Aural abscess, Eastern box turtle, pathology, hypovitaminosis A, squamous metaplasia, *Terrapene carolina carolina*.

INTRODUCTION

Aural abscess, a unilateral or bilateral swelling of the tympanic cavity or middle ear (Fig. 1), was recently found to be the second highest cause of morbidity and mortality in free-living Eastern box turtles (*Terrapene carolina carolina*) from Virginia (USA; Brown and Sleeman, 2002). This lesion was reported in free-living Eastern box turtles in other states (Willer et al., 2003). Mucin-secreting epithelium lining the upper respiratory tract and middle ear of free-living box turtles with aural abscesses exhibits varying degrees of pathologic change, including squamous metaplasia, hyperkeratinization, mucosal hyperplasia, inflammation, and mucosal erosion (Holladay et al., 2001). These changes, when in the tympanic cavity of turtles, result in accumulation of caseous debris and inflammatory cells, the development of abscesses, and, occasionally, bony erosion of the skull.

The cause of aural abscesses in free-liv-

ing box turtles is unknown. A similar lesion, both grossly and histologically, occurs in captive turtles that are fed diets deficient in vitamin A (Jackson and Cooper, 1981; Murray, 1996). We believe that hypovitaminosis A may play a role in the pathophysiology of aural abscesses in free-living box turtles. We previously reported higher body burdens of organochlorine compounds and a nonsignificant trend toward decreased serum and liver vitamin A concentrations in free-living box turtles with aural abscesses (Holladay et al., 2001). Lack of statistical significance of this observation may have been due to a low number of turtles ($n=10$) used in the previous study. The presence of high body concentrations of organochlorine compounds was hypothesized to disrupt normal vitamin A metabolism, causing hypovitaminosis A, squamous metaplasia, and the development of aural abscesses. This hypothesis is supported by previous reports in humans and rats, which have

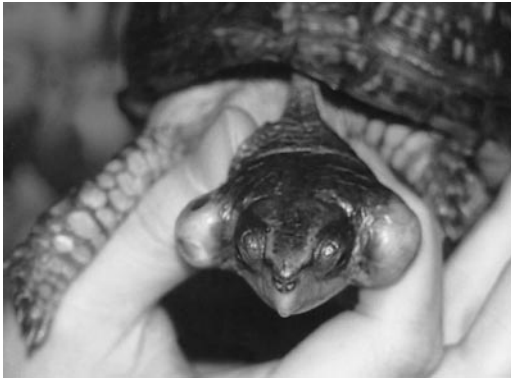

FIGURE 1. Bilateral aural abscesses in an Eastern box turtle (*Terrapene carolina carolina*).

shown a similar organochlorine-induced vitamin A deficiency (Chen et al., 1992; Coenraads et al., 1994). The objectives of this study were to 1) describe the gross and histopathologic changes of the tympanic epithelium and other organs of free-living box turtles with aural abscesses, 2) compare the severity of these lesions to changes in turtles that were not clinically affected by aural abscesses, and 3) discuss the relationship of the lesions to the proposed hypothesis of organochlorine compound-induced hypovitaminosis A.

MATERIALS AND METHODS

The tympanic epithelium and samples of gastrointestinal tract, heart, kidney, liver, pancreas, reproductive tract, skeletal muscle, skin, spleen, and trachea were collected from free-living Eastern box turtles presented to the Wildlife Center of Virginia (WCV, Waynesboro, Virginia, USA). Ten turtles had aural abscesses (six unilateral and four bilateral). Also included in the study were 17 turtles that were euthanized for other terminal conditions, such as trauma, and were designated as “non-aural abscess cases.” The clinical diagnoses were made by the attending veterinarians at the WCV.

All turtles were killed by intravenous pentobarbital sodium (Beuthanasia-D; Schering-Plough Animal Health, Union, New Jersey, USA) and overdose of inhaled halothane; they were then decapitated. The plastrons were removed, and tissue samples were taken. All heads and tissues were immediately fixed in 10% neutral buffered formalin. Transverse sections of the fixed heads were made using a band saw at the level of the tympanum and

decalcified for 1 week in TBD-2 decalcifier (Thermo Shandon, Pittsburgh, Pennsylvania, USA). The resultant sections and tissue samples were sectioned at 7 μ m, stained with hematoxylin and eosin (HE), and processed for paraffin embedding. Six turtle heads (three with aural abscesses and three without) were selected at random for further evaluation with special stains (Gram’s and periodic acid–Schiff [PAS]).

Tissue sections were examined without knowledge of their source. Pathologic changes evaluated in the tympanic epithelia included inflammation, hyperemia, keratinization, necrosis, hyperplasia, and dysplasia. The presence and severity of changes for each diagnostic category were scored as minimum, moderate, or marked, which correlated with a score of one, two, or three, respectively. For the purposes of analysis, and to group this constellation of lesions, the scores for each of the six categories were added with a maximum value of 18 and a minimum value of 6. The final score for each turtle was interpreted on the basis of the following ranges of scores: ≤ 7 , minimal aggregate pathologic change; 8–11, moderate aggregate pathologic change; 12–15, marked aggregate pathologic change; and ≥ 16 , severe aggregate pathologic change.

One turtle with aural abscesses and one without a lesion were randomly selected for further evaluation of their tympanic epithelium using scanning electron microscopy (SEM). Samples were immersed in 3% glutaraldehyde in 0.1 M sodium phosphate buffer (pH 7.4). The samples were washed in 0.1 M phosphate buffer (pH 7.4) and postfixed in 1% osmium tetroxide in 0.1 M sodium phosphate buffer for 1 hr. Samples were again washed in 0.1 M sodium phosphate buffer, dehydrated in an ethanol series, and subjected to critical point drying. Tissues were then prepared for and examined by SEM (Cambridge Instruments, Olympus America, Inc., Melville, New York, USA).

Additional tissue samples were collected from the gastrointestinal tract, cardiac muscle, kidney, liver, pancreas, reproductive tract, skeletal muscle, skin, spleen, and trachea from 10 turtles with aural abscesses and 11 turtles without. Samples were fixed, processed, and sectioned as previously described, without decalcification. The mean, SD, and range were calculated for the total number of melanomacrophages counted in eight 40 \times fields per liver in three turtles with aural abscesses and four turtles without. The eight fields were examined in the same rectangular pattern in all liver samples examined.

RESULTS

The tympanic membranes from unaffected box turtles were normal (Fig. 2A). The tympanic epithelium of all turtles with aural abscesses was markedly hyperplastic and/or deformed (Fig. 2B). Squamous metaplasia was observed throughout the tympanic epithelium, which consisted of stratified squamous, stratified pseudocolumnar, and stratified columnar cells, with little order to the transition. All of the turtles with abscesses had variable amounts of bilateral hyperplasia. This change varied from focal to diffuse. The caseous plug or abscess was composed of a necrotic core with an outer zone that consisted of necrotic cellular debris, variable amounts of keratin, and inflammatory cells that consisted primarily of heterophils, lymphocytes, and plasma cells.

Of the 10 turtles with aural abscesses, two had marked keratinization (Fig. 2C) of the tympanic epithelium, three had moderate, and four had minimal keratinization. Turtles with larger abscesses had greater amounts of keratin incorporated into the caseous plug, but not accumulated on the epithelium itself. The outer layers of cells in the hyperplastic epithelium were sloughing into the lumen of the middle ear and were incorporated in the caseous plug (Fig. 2D). The vasculature in the lamina propria lining the tympanic cavity was moderately to markedly hyperemic in every tympanic cavity that contained an abscess. A marked, diffuse, mixed inflammatory response was present in the epithelium and lamina propria lining the tympanic cavities and extended into the lumen of the cavity in all turtles with aural abscesses. This inflammation was characterized by the presence of lymphocytes, heterophils, and plasma cells (Fig. 2E), with occasional giant cells and macrophages (Fig. 2F). Inflammation in tympanic cavities that contained an abscess extended into underlying subepithelial regions. Two of 10 turtles had abscesses that extended to and involved the bone surrounding the

tympanic cavity. In these cases, giant cells predominated. Affected turtles with more severe pathologic changes in the tympanic epithelium also had focal areas of erosion. Erosion was highly variable in severity, ranging from focal indentations to total loss of epithelial cells and exposure of subepithelial tissue. Ulceration of the tympanic membrane was abrupt.

In the six turtles with unilateral abscesses, the severity of change in the contralateral tympanic cavity was variable for each of the lesion categories (ranging from minimal to marked) but, in general, was less severe than in the cavity with an abscess. In contrast, the four turtles with bilateral aural abscesses had changes to both tympanic cavities that were similar in character and severity. The 10 turtles with aural abscesses had more severe pathologic changes in their tympanic epithelium than the 17 turtles without abscesses, as indicated by greater mean scores in each of the lesion categories (Fig. 3).

No fungi were observed in the tympanic cavities of the six turtles (three with abscesses and three without) examined with PAS. The presence and activity of goblet cells in the tympanic cavity were variable in turtles with or without aural abscesses, ranging from few cells with minimal mucus secretion to numerous cells with enormous secretory activity. No trend was noted between the concentration goblet cells and the activity and occurrence of aural abscesses. Bacterial colonies were observed in large numbers on Gram's stain in three turtles with aural abscesses. The colonies were heterogeneous and were incorporated into the caseous plug along with desquamated epithelial tissues and inflammatory debris. In these turtles, bacterial colonies were also observed in the oropharyngeal cavity. One of the three turtles without aural abscesses had bacteria in its tympanic cavity, but numbers were minimal, and colonies were not observed. Numbers of bacteria in the oropharynx of these three turtles without aural abscesses were minimal.

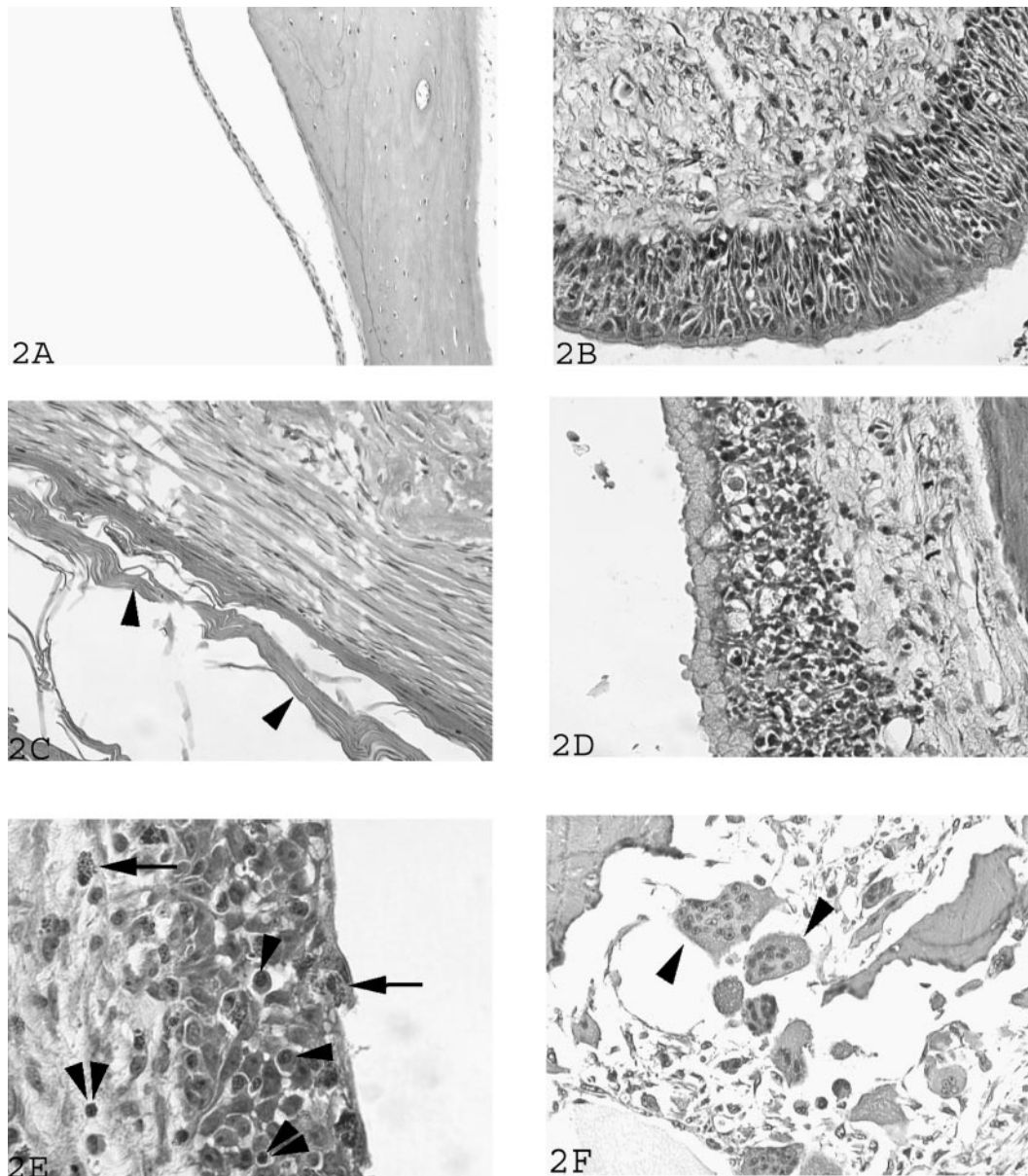


FIGURE 2. (A) Tympanic epithelium from a turtle without aural abscess (HE stain, 250 \times). (B–F) Tympanic epithelium from turtles with aural abscess (HE stain). (B) Hyperplastic and dysplastic tympanic epithelium. 250 \times (C) Extensive accumulation of keratin (single arrowhead) on the surface of the epithelium, which is sloughed into the lumen of the cavity and incorporated into the aural abscess. 250 \times (D) Outer cell layers of the hyperplastic epithelium are necrotic and incorporated into the aural abscess. 250 \times (E) Mixed inflammatory infiltrates in affected tympanic epithelium, including numerous heterophils (single arrow), lymphocytes (double arrowhead), and plasma cells (single arrowhead). 400 \times (F) Giant cells (single arrowhead) in the inflammatory response in a turtle with aural abscess. 400 \times

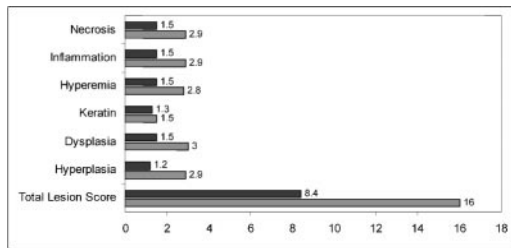


FIGURE 3. Mean scores of severity for lesions in free-living box turtles with aural abscesses ($n=10$, light bar) and without aural abscesses ($n=17$, dark bar). Necrosis, inflammation, hyperemia, keratin, dysplasia, and hyperplasia were scored from one (minimal change) to three (marked change). Total lesion score was the sum score from each category for an individual turtle and ranged from 6 (minimal change) to 18 (marked change).

SEM evaluation of the tympanic membrane from a turtle without aural abscesses revealed a well paved cellular surface (Fig. 4A). Minor artifacts were noted due to preparation, but desquamation, cracks, and other alterations were minimal. In comparison, the tympanic membrane of a turtle with aural abscesses had cellular discontinuity, with multifocal erosions and an accumulation of debris (Fig. 4B).

Lesions in organs other than the head were minimal. When compared with livers from turtles without aural abscesses, livers from turtles with aural abscesses had increased numbers of melanomacrophages (mean number of melanomacrophages in eight $40\times$ fields per turtle \pm SD [range]—three turtles with aural abscesses, 69 ± 41 [22–98]; four turtles without aural abscesses, 43 ± 10 [32–55]). Microscopic lesions




FIGURE 4. Surface scanning electron micrographs. (A) Tympanic epithelium from a free-living box turtle without aural abscess (magnification, $5,490\times$). (B) Tympanic epithelium from turtle with aural abscess (magnification, $3,490\times$). Note the extensive desquamation and deformation of the smooth continuous surface of the tympanic cavity surface in the affected turtle.

consistent with malnutrition—such as reduced glycogen stores, shrunken hepatocytes, and increased cords and sinuses—were observed in turtles with and without aural abscesses.

DISCUSSION

Deficiencies in vitamin A are characterized by changes in epithelial tissue, including keratinization, squamous metaplasia, hyperplasia, and decreased growth (Cheville, 1994). In this study, lesions in the tympanic epithelium of box turtles with aural abscesses were consistent with these previously reported hypovitaminosis A-induced epithelial changes.

Vitamin A is required for the maintenance of epithelium in a normal differentiated state; with a lack of this cofactor, mucin-secreting epithelium undergoes squamous metaplasia and a change in phenotype from simple or pseudostratified columnar to stratified squamous cells (Kim et al., 2002). This change in phenotype accompanies a change in function as cells that normally secrete mucus switch to producing keratin (Rosenthal et al., 1994). Hypovitaminosis A-induced changes, such as squamous metaplasia, hyperplasia, and hyperkeratinization of mucin-secreting epithelium, result in many clinical signs, including softening of the cornea, drying of conjunctiva and membranes, and secondary infection (Combs, 1992; Wiederman et al., 1996). In captive turtles, squamous metaplasia also occurs in the middle ear and Eustachian tube, where it manifests as sloughed epithelium, which accumulates, forming a caseous plug with secondary bacterial infection (Murray, 1996).

Retinoids (vitamin A) are powerful regulators of the differentiation and maintenance of epithelial cells. As a consequence of the distribution pattern of retinoic acid receptor isoforms $\alpha 1$, $\alpha 2$, $\beta 2$, $\beta 3$, $\gamma 1$, and $\gamma 2$ (RAR) and retinoid-X receptors α , β , and γ (RXR), epithelial tissues are differentially responsive to retinoids (Darwicke et al., 1994). In particular, epithelial cells in structures associated with the pharynx,

conjunctival membranes, the urogenital tract, and upper airway and lower respiratory passages are highly sensitive to squamous metaplasia induced by vitamin A deficiency. This abnormal epithelial cell differentiation, which may be associated with diminished mucin production and swelling and outgrowth of the hornlike keratin, can be reversed by administration of retinoic acid (RA; Frye, 1991; Denning and Verma, 1994). Specific operating mechanisms by which RA improves squamous metaplasia have not been definitively identified; however, an altered expression of cytokeratins may accompany such squamous differentiation, and the expression of keratin squamous differentiation markers (e.g., K13) can be inhibited by RA (Denning and Verma, 1994). Induction of the squamous-specific gene, cornifin α , has been noted in tracheal epithelial tissues of vitamin A-deficient animals and was suppressed by the administration of RA (Fujimoto et al., 1994). Vitamin A deficiency, or exposure to either natural or synthetic estrogens (e.g., diethylstilbestrol [DES]), greatly enhanced the squamous differentiation and keratinization of vaginal epithelium in ovariectomized animals. The latter effect was again associated with a dramatic induction of the cornifin α gene (Jetten et al., 1996).

The observation that DES exposure may alter the differentiation of epithelial cells has raised questions about possible similar effects in wildlife from environmental estrogenic or endocrine-disrupting compounds or related compounds that affect thyroid hormone levels (Colburn, 2002). Serum retinol concentrations have been negatively associated with organochlorine exposure in polar bears (*Ursus maritimus*; Skaare et al., 2001). Wild bird populations exposed to organochlorine pesticides or polychlorinated biphenyls display altered thyroid hormone levels (Bishop et al., 1998) and have an inhibited vitamin A metabolism (Grasman et al., 1996). In this regard, thyroid hormone and vitamin A metabolism are linked by a com-

mon plasma carrier protein, transthyretin (TTR). Polychlorinated biphenyls and related organochlorine compounds deplete vitamin A and thyroxine by interaction with TTR and by alteration of their metabolism in the liver and other organs (Heussen et al., 1993). However, altered differentiation of vitamin A-sensitive epithelia or thyroid or estrogen hormone-sensitive epithelia has not been examined in these animals.

Anaerobic and aerobic bacteria have been isolated from aural abscesses of turtles, with the latter being more frequent (Stewart, 1990; Murray, 1996). The tympanic cavity of turtles connects to the oropharynx via the Eustachian tube. Pathologic changes in the middle ear and Eustachian tube resulting from hypovitaminosis A, such as squamous metaplasia and the sloughing of epithelial cells, predispose these animals to secondary bacterial infection by disrupting the normal continuity of the epithelium (Murray, 1996). The deformed tympanic epithelium is colonized by ascending commensal bacteria from the oropharynx. Additionally, hypovitaminosis A may predispose these turtles to secondary bacterial infection by interfering with complement and normal cellular immune function (Stewart, 1990). Turtles with aural abscesses and histopathologic changes consistent with vitamin A deficiency carried greater bacterial loads in their tympanic cavities than turtles without lesions. From this histopathologic evaluation, we were unable to determine whether the bacteria observed were commensal or pathogens; however, bacterial cultures are being conducted to further evaluate pathophysiology of this lesion. A previous study did not identify a consistent bacterial pathogen (Willer et al., 2003).

We also investigated the possibility of hypovitaminosis A-induced altered cell differentiation in tissues other than tympanic epithelium. Associated histopathologic changes (squamous metaplasia, hyperplasia, and keratinization) would likely occur in epithelial tissues, such as the tra-

chea, reproductive tract, and gastrointestinal tract. However, no changes comparable to those in the tympanic epithelium were observed in other organs that we examined. One explanation could be that the tympanic epithelium of box turtles has a greater density of RAR and RXR and is more sensitive to hypovitaminosis A than other epithelial structures examined in this study; this requires further investigation. Ocular epithelial tissues are sensitive to hypovitaminosis A, and swelling of the eyelids or blepharoeidema is frequently one of the first observed clinical signs in pet chelonians with hypovitaminosis A (Boyer, 1996). We are currently investigating the histopathologic changes to the ocular system in free-living turtles with aural abscesses.

Increased numbers of melanomacrophages in the livers of turtles with aural abscesses may be important. Melanomacrophages are pigment cells with characteristic eumelanin-containing organelles (Gopalakrishnakon, 1986). These cells are in the dermis, lung, and liver of turtles (Hou, 1999). It has not been reported, however, whether melanomacrophages in the liver react to toxicants, such as organochlorine compounds, by an increase in activity or proliferation. It has been proposed that the spatial distribution of melanomacrophages and other pigment cells is controlled, in part, by environmental factors (Hou, 1999). The pathophysiology of the malnutrition-induced changes in the livers of turtles with and without aural abscesses can likely be explained by the moribund status of the animals.

The findings of this study provide evidence for a hypovitaminosis A-induced etiology of aural abscesses. This supports the organochlorine-induced hypovitaminosis A hypothesis proposed by Holladay et al. (2001). However, other causes of hypovitaminosis A—such as direct dietary deficiency, interference in the gastrointestinal absorption of vitamin A, the presence of other endocrine-disrupting chemicals, or other etiologies—cannot be ruled out.

Further investigations are being conducted that may provide more definitive evidence for the role of vitamin A deficiency and organochlorine compounds in the development of aural abscesses.

ACKNOWLEDGMENTS

We thank V. Viers for assistance in SEM preparation. We also thank the staff of the Wildlife Center of Virginia, who were responsible for the medical care of reptile cases, and the staff of the histopathology laboratory at Virginia-Maryland College of Veterinary Medicine for their help in preparing the slides. This study was funded by the Geraldine R. Dodge Foundation Frontiers For Veterinary Medicine initiative and the Environmental Quality Technology Program of the US Army, with continued support from the Morris Animal Foundation. The study was approved by the Virginia Tech Animal Care Committee, and the samples were collected with permission from the Virginia Department of Game and Inland Fisheries.

LITERATURE CITED

- BISHOP, C. A., G. J. VAN DER KRAAK, P. NG, J. E. SMITS, AND A. HONTELA. 1998. Health of tree swallows (*Tachycineta bicolor*) nesting in pesticide-sprayed apple orchards in Ontario, Canada. II. Sex and thyroid hormone concentrations and testes development. *Journal of Toxicology and Environmental Health* 55: 561–581.
- BOYER, T. H. 1996. Hypovitaminosis A and hypervitaminosis A. *In* Reptile medicine and surgery, D. R. Mader (ed.). W. B. Saunders Co., Philadelphia, Pennsylvania, pp. 382–385.
- BROWN, J. D., AND J. M. SLEEMAN. 2002. Morbidity and mortality of reptiles admitted to the Wildlife Center of Virginia, 1991–2000. *Journal of Wildlife Diseases* 38: 699–705.
- CHEN, L. C., I. BERBERIAN, B. KOCH, M. MERCIER, V. AZAIS-BRAESCO, H. P. GLAUERT, C. K. CHOW, AND L. W. ROBERTSON. 1992. Polychlorinated biphenyl congeners and retinoid levels in rat tissues: Structure-activity relationships. *Toxicology and Applied Pharmacology* 114: 47–55.
- CHEVILLE, N. F. 1994. Pathologic cell growth. *In* Ultrastructural pathology: An introduction to interpretation. Iowa State University Press, Ames, Iowa, pp. 192–228.
- COENRAADS P. J., A. BROUWER, K. OLIE, AND N. TANG. 1994. Chloracne: Some recent issues. *Dermatologic Clinics* 12: 569–576.
- COLBURN, T. 2002. Clues from wildlife to create an assay for thyroid system disruption. *Environmental Health Perspectives* 10(Suppl. 3): 363–367.
- COMBS, G. F. 1992. Vitamin A. *In* The vitamins: Fundamental aspects in nutrition and health. Academic Press, Inc., San Diego, California, pp. 119–150.
- DARWICHE, N., G. CELLI, AND L. M. DE LUCA. 1994. Specificity of retinoid receptor gene expression in mouse cervical epithelia. *Endocrinology* 134: 2018–2025.
- DENNING, M. F., AND A. K. VERMA. 1994. The mechanism of the inhibition of squamous differentiation of rat tracheal 2C5 cells by retinoic acid. *Carcinogenesis* 15: 503–507.
- FRYE, F. L. 1991. Nutrition: A practical guide for feeding captive reptiles. *In* Biomedical and surgical aspects of captive reptile husbandry, F. Frye (ed.). Krieger Publishing, Melbourne, Florida, pp. 41–100.
- FUJIMOTO, W., K. W. MARVIN, M. D. GEORGE, G. CELLI, N. DARWICHE, L. M. DE LUCA, AND A. M. JETTEN. 1993. Expression of cornifin in squamous differentiating epithelial tissues, including psoriatic and retinoic acid-treated skin. *Journal of Investigative Dermatology* 10: 268–74.
- GOPALAKRISHNAKON, P. 1986. The structure of the pigment cells in the turtle *Trionyx sinensis*. *Archivum Histologicum Japonicum* 49: 421–435.
- GRASMAN, K. A., G. A. FOX, P. F. SCANLON, AND J. P. LUDWIG. 1996. Organochlorine-associated immunosuppression in prefledgling Caspian terns and herring gulls from the Great Lakes: An ecopidemiological study. *Environmental Health Perspectives* 104(Suppl. 4): 829–842.
- HEUSSEN, G. A., G. J. SCHEFFERLIE, M. J. TALSMA, H. VAN TIL, M. J. DOHMEN, A. BROUWER, AND G. M. ALINK. 1993. Effects on thyroid hormone metabolism and depletion of lung vitamin A in rats by airborne particulate matter. *Journal of Toxicology and Environmental Health* 38: 419–434.
- HOU, L. 1999. Effects of local tissue environment on the differentiation of neural crest cells in turtle, with special reference to understanding the spatial distribution of pigment cells. *Pigment Cell Research* 12: 81–88.
- HOLLADAY, S. D., J. C. WOLF, S. A. SMITH, D. E. JONES, AND J. L. ROBERTSON. 2001. Aural abscesses in wild-caught box turtles (*Terrapene carolina*): Possible role of organochlorine-induced hypovitaminosis A. *Ecotoxicology and Environmental Safety* 48: 99–106.
- JACKSON, O. F., AND J. E. COOPER. 1981. Nutritional diseases. *In* Diseases of reptilia, J. E. Cooper and O. F. Jackson (eds.). Academic Press, New York, pp. 416–418.
- JETTEN, A. M., L. M. DE LUCA, K. NELSON, W. SCHROEDER, S. BURLINGAME, AND W. FUJIMOTO. 1996. Regulation of cornifin alpha expression in the vaginal and uterine epithelium by estrogen and retinoic acid. *Molecular and Cellular Endocrinology* 123: 7–15.
- KIM, Y. S., S. M. HWANG, S. J. LEE, AND J. S. JUNG.

2002. Differential expression of a WD protein during squamous differentiation of tracheal epithelial cells. *Journal of Cellular Biochemistry* 86: 194–201.
- MURRAY, M. J. 1996. Aural abscesses. *In* Reptile medicine and surgery, D. R. Mader (ed.). W. B. Saunders Co., Philadelphia, Pennsylvania, pp. 349–352.
- ROSENTHAL, D., F. LANCILLOTTI, N. DARWICHE, R. SINHA, AND L. M. DE LUCA. 1994. Regulation of epithelial differentiation by retinoids. *In* Vitamin A in health and disease, R. Blomhoff (ed.). Marcel Dekker, Inc., New York, New York, pp. 425–450.
- SKAARE, J. U., A. BERNHOFT, O. WIIG, K. R. NORUM, E. HAUC, D. M. EIDE, AND A. E. DEROCHE. 2001. Relationships between plasma levels of organochlorines, retinol and thyroid hormones from polar bears (*Ursus maritimus*) at Svalbard. *Journal of Toxicology and Environmental Health Part A* 62: 227–241.
- STEWART, J. S. 1990. Anaerobic bacterial infections in reptiles. *Journal of Zoo and Wildlife Medicine* 21: 180.
- WIEDERMAN, U., A. TARKOWSKI, T. BREMELL, L. A. HANSON, H. KAHU, AND U. I. DAHLGREN. 1996. Vitamin A deficiency predisposes to *Staphylococcus aureus* infection. *Infection and Immunity* 64: 209–214.
- WILLER, C. J., G. A. LEWBART, AND C. LEMONS. 2003. Aural abscesses in wild Eastern box turtles, *Terrapene carolina carolina*, from North Carolina: Aerobic bacterial isolates and distribution of lesions. *Journal of Herpetological Medicine and Surgery* 13: 4–9.

Received for publication 12 August 2003.